

Original

**A Comparison of Magnifying Chromoendoscopy
Versus Narrow Band Imaging in the Diagnosis of
Depth of Invasion for Early Colorectal Cancers**

Yasutoshi KOBAYASHI, Shin-ei KUDO, Hideyuki MIYACHI,
Toshihisa HOSOYA, Takemasa HAYASHI, Kunihiko WAKAMURA,
Yoshiki WADA, Nobunao IKEHARA, Fuyuhiko YAMAMURA
and Kazuo OHTSUKA

Abstract: Although chromoendoscopy and narrow band imaging (NBI) are widely used in diagnosing the invasion depth of colorectal cancers, comparative studies of these modalities are lacking. This meta-analysis compared the performance of these two modalities in colorectal cancer diagnosis. MEDLINE, EMBASE, and Cochrane Library were searched for relevant original articles published up to December 20th, 2010. Major criteria for article inclusion were: (i) magnifying chromoendoscopy or NBI was used as a diagnostic modality and pit pattern or vascular pattern was used as a diagnostic classification; (ii) sensitivity and specificity were reported; (iii) absolute numbers of true-positive, false-positive, true-negative, and false-negative cases, or their equivalent, were provided; and (iv) pathology of biopsy, endoscopy, or surgical treatment was used as the reference standard. Sensitivity and specificity were pooled using a random effects model. Regression analysis was performed to compare the discriminatory power between chromoendoscopy and NBI by including a dummy variable. We made the assumption that a positive regression coefficient implied a better discriminatory power for NBI, and vice versa. Of 1846 screened articles, 16 fulfilled all inclusion criteria. Pooled sensitivity for chromoendoscopy and NBI was 0.85 (95% CI: 0.82–0.87) and 0.80 (0.76–0.85), respectively, and specificity was 0.98 (0.97–0.99) and 0.98 (0.97–0.99), respectively. The regression coefficient for chromoendoscopy versus NBI was –0.02 (95% CI: –1.18–1.71). These results indicate that chromoendoscopy and NBI may have similar power for the diagnostic assessment of colonic neoplasms. However, other factors such as convenience, time, and cost still must be taken into account in making the final diagnostic choice.

Key words: early colorectal cancer, chromoendoscopy, Narrow Band imaging, pit pattern, vascular pattern

Introduction

Recently, colorectal cancer (CRC) has become the second most commonly diagnosed cancer and the third leading cause of cancer-related death in Japan¹⁾. In 2009, approximately 23,000 men and 20,000 women died of this malignancy¹⁾. During the past decade, great emphasis has been placed on the use of colonoscopy for the early detection and removal of neoplastic polyps to reduce the incidence of and mortality from CRC.

When considering the therapeutic strategy for patients with CRC, it is crucial to estimate the stage of carcinoma progression according to the TMN classification because the stages are well correlated with disease prognosis. Intramucosal and submucosal cancers are classified as T1 stage, with intramucosal cancers generally not associated with lymph node (LN) metastasis²⁾. Therefore, such cancers have a good indication for endoscopic treatment. On the other hand, submucosal cancers have a 6–12% possibility of LN metastasis requiring surgical resection by lymphadenectomy²⁾.

Several pathological investigations of submucosal cancers have together suggested that lesions with slight invasion into submucosal cancers carry a low possibility of LN metastasis. For instance, in classifying the degree of submucosal invasion, Kudo *et al*³⁾ demonstrated that lesions associated with a carcinomatous invasion approximately one-third the depth of the entire submucosa (SM) layer exhibit no LN metastasis. By retrospective analyses, Kitajima *et al*⁴⁾ also concluded that lesions of less than 1000 μm have little possibility of LN metastasis. Hence, many endoscopists are currently investigating the diagnostic criteria for predicting lesions with low-level cancerous invasion with the view that patients could avoid undergoing unnecessary operations for lesions that are curable with endoscopic treatment.

The traditional criteria for predicting the histopathology and the carcinomatous depth of colorectal lesions are those advocated by Kudo *et al*³⁾ in the mid-1990s. In these criteria, called Kudo's pit pattern classification, dye spraying (chromoendoscopy) and magnifying endoscopy are used to differentiate among non-neoplastic, neoplastic, and cancerous lesions⁵⁾. Meanwhile, after the advent of a new endoscopic technology called Narrow Band Imaging (NBI) early in the 21st century, several researchers proposed that this modality could be used with certain predictive criteria of cancer depth^{6,7)}. In this system, images of the microvessels and the surface structures of lesions are provided without the need for dye spraying; endoscopists then estimate the depth of cancer by observing these features^{6,7)}.

While several studies have suggested the usefulness of chromoendoscopy and NBI in predicting the depth of cancer, few direct comparisons have been reported. Therefore, this study aimed to pool the diagnostic test characteristics of chromoendoscopy and NBI to compare their diagnostic performance.

Methods

Data Collection

We searched the MEDLINE and EMBASE databases, and the Cochrane Controlled Trial Register from 1966 to December 20th 2010. Searched articles were limited to published, English language studies. We used the search terms “colorectal neoplasms” and/or “endoscope” in medical subject headings (MESH), and “dye spraying”, “pit pattern”, “chromoendoscopy”, “chromocolonoscopy”, or “magnifying” in the text to search MEDLINE for articles about chromoendoscopy. We located articles about NBI using the search terms “colorectal neoplasms” and/or “endoscope” in MESH, and “narrow band imaging” or “NBI” in the text. We also scanned the references provided in retrieved articles and contacted endoscopists for further information about any other relevant reports. A similar strategy was used for database searches in the EMBASE database and Cochrane Library. The titles and abstracts of relevant studies were screened for appropriateness prior to retrieval of the full article. Two of the investigators (Y.K., H.M.) independently searched and extracted the data from all articles. Any differences were resolved by mutual agreement.

Inclusion and exclusion criteria

A study was included when all of the following criteria were met :

- (1) Magnifying chromoendoscopy or NBI was used as a diagnostic modality and the pit pattern and vascular pattern was used as a diagnostic classification for predicting the histology and invasion depth of colorectal lesions according to the pit pattern, surface pattern, or vascular pattern of the lesions.
- (2) Sensitivity and specificity were reported, or a 2×2 contingency table could be reconstructed.
- (3) Absolute numbers of true-positive, false-positive, true-negative, and false-negative cases, or their equivalent, were provided.
- (4) Pathology from biopsy, endoscopy, or surgical treatment was used as the reference standard for lesion diagnosis.

A study was excluded if any of the following criteria were met :

- (1) A stereomicroscope, confocal microscope, endocytoscope, FICE (Fuji Intelligence Color Enhancement), or other tool was used as the diagnostic modality.
- (2) The target patients were restricted only to familial polyposis (FAP), inflammatory bowel disease (IBD), or hereditary non-polyposis colorectal cancer (HNPCC).
- (3) The published information was incomplete.

When more than two results were obtained from each study, the result with the worst specificity was applied to the analysis because specificity is important in colonoscopy as a confirmatory test.

Quality assessment of primary studies

The quality of all included articles was assessed using Quality Assessment of Diagnostic Studies (QUADAS), a tool designed specifically for studies on diagnostic accuracy⁸⁾. Using this tool, we assessed the most significant forms of bias in diagnostic research including spectrum, disease progression, verification, and review biases, as well as potential bias associated with subject withdrawal and aspects of external validity⁸⁾.

Statistical analysis

We first performed a separate evaluation of the diagnostic performance of chromoendoscopy and NBI by combining pooled sensitivity, specificity, and likelihood ratios using a random effect model⁹⁾ to derive estimates and their 95% confidence intervals (CI). Standard error was calculated using the Agresti-Coul (Wald) adjustment¹⁰⁾ if the sensitivity or specificity of each study was equal to 1. Heterogeneity of the studies was assessed by using the I^2 statistic¹¹⁾. The causal factor of heterogeneity was also explored by meta-regression¹²⁾. Factors evaluated as sources of heterogeneity were as follows: (i) the model of the endoscope used in each study; (ii) a video system that used color chip imaging, sequential imaging, or other; (iii) a study that was prospective or retrospective; (iv) the Quadas score was > 12 ; and, (v) the target lesion was restricted in size and/or macroscopic appearance in each study.

Next, we tested the performance of chromoendoscopy and NBI in studies that adopted the same diagnostic modality in a similar patient population. For this purpose, we used only the studies that met both of the following criteria: (i) the definition of invasive cancer was set as “more than 1000 μm ”, (ii) there were no restrictions on polyp size or macroscopic appearance of lesions.

The discriminatory power between chromoendoscopy and NBI was compared using meta-regression analysis that included a dummy variable (chromoendoscopy = 0, NBI = 1). In this case, a positive regression coefficient implies that NBI had better discriminatory power compared to chromoendoscopy, while a negative value indicates the opposite. Publication bias was assessed by Begg’s and Egger’s tests¹³⁾. To avoid undefined values that would have arisen due to zero values, 0.5 was added to any zero cell¹⁴⁾. Statistical significance was set at $P < 0.05$. All analyses were performed using Stata version 10.1 (Stata Corporation, College Station, TX, USA).

Results

Study Selection and Data Extraction

An initial search using the specified search terms identified a total of 1846 reference articles. Among these, 64 relevant articles were selected and reviewed by two authors independently, with 48 articles excluded for the following reasons: (a) the pit pattern, surface pattern, vascular pattern classification, or magnifying endoscope was not used as a diagnostic

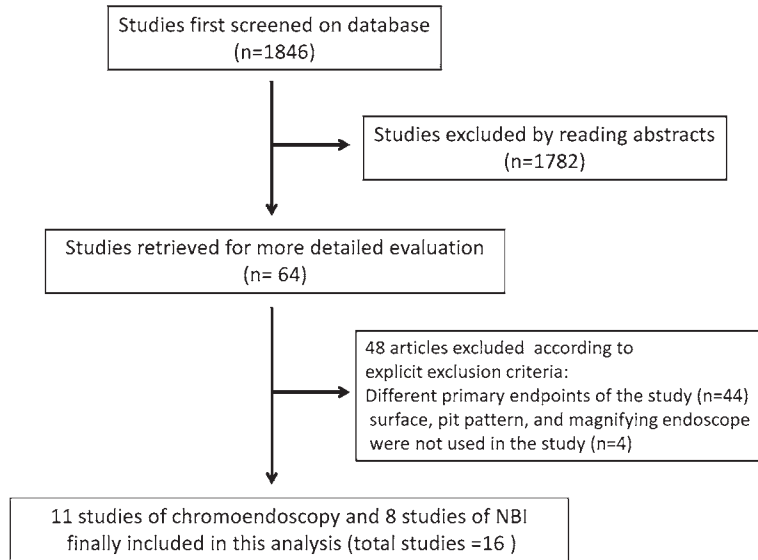


Fig. 1. Flow diagram of reviewing process

modality; (b) their primary outcome was to differentiate neoplasms from non-neoplasms or evaluate the detection rate of polyps. Thus, we included 16 studies in our final review (Fig. 1). Table 1 summarizes the included study characteristics. Ten studies were conducted prospectively in clinical settings^{2, 7, 15-22}, and six studies were based on still images of lesions analyzed retrospectively²³⁻²⁸. Patient demographics were generally not provided. One study restricted inclusion criteria based on polyp size and two studies did so by macroscopic appearance. Chromoendoscopy was used in 11 studies and NBI was used in 8 studies, with a sequential imaging system used in all of the studies.

Diagnostic test performance of chromoendoscopy and NBI

Of the 16 studies, 11 were used to evaluate the diagnostic performance of chromoendoscopy, while 8 were included to evaluate NBI (Fig. 2). Pooled diagnostic performance of chromoendoscopy revealed a sensitivity of 0.85 (95%CI: 0.82–0.87), a specificity of 0.98 (0.97–0.99), a positive likelihood of 16.1 (6.02–42.8), and a negative likelihood of 0.17 (0.10–0.30), while the pooled performance of NBI revealed a sensitivity of 0.80 (95%CI: 0.76–0.85), a specificity of 0.98 (0.97–0.99), a positive likelihood of 25.7 (11.5–57.3), and a negative likelihood of 0.20 (0.12–0.32) (Fig. 3 (a), (b), and Table 2). Heterogeneity was significant for all the aforementioned diagnostic performance measures with chromoendoscopy and NBI.

A secondary analysis was then conducted using five extracted studies for chromoendoscopy and seven studies for NBI. When restricted in this condition, analyzing the pooled diagnostic performance of chromoendoscopy showed a sensitivity of 0.87 (95%CI: 0.83–0.90), a specificity of 0.99 (0.98–0.99), a positive likelihood of 26.0 (7.24–93.0), and a

Table 1. Characteristics of Included Studies

Study and Year (Reference)	Diagnostic Modality	Diagnostic classification	Pathologic Reference standard	Criteria of massive SM invasion	Number of endoscopist	Number of polyps	Research design	Restriction in analysis	Quadas score
Nagata S, 2000 (21)	CF-240Z* CF-200Z** EC410CM** EC410ZM** Crystal (conc, NS)	Original pit Classification (Nagata classification)	Vienna	> 400 μ m	NS	75	Pros.	NS	10
Matsumoto T, 2002 (22)	CF-240Z* CF-200Z* 1.0% Crystal	Modified Nagata Classification	NS	SM2, and SM3	NS	50	Pros.	NS	13
Hurlstone DP, 2004 (15)	CF-H260Z* CF-240Z* 0.05% Crystal	Nagata Classification	Vienna	> 200 μ m	1	51	Pros.	W / O Polypoid lesion	13
Tobaru T, 2008 (23)	CF-240ZI* 0.08% Crystal	Modified Kudo classification	JRSCCR	> 1000 μ m	NS	99	Retro.	NS	9
Matsuda T, 2008 (16)	CF-240ZI* PCF-240ZI* CF-200Z* 0.05% Crystal	Invasive pattern	JRSCCR	> 1000 μ m	NS	4215	Pros.	NS	12
Fu KI, 2008 (2)	CF-240Z* CF-200Z* 0.2% Indigo	Invasive pattern	JRSCCR	SM2, and SM3	NS	102	Pros.	NS	11
Okamoto Y, 2011 (17)	PCF-240Z* Crystal (conc, NS) NBI	Nagata Classification (Chromo) Hiroshima Classification (NBI)	JRSCCR	> 1000 μ m	NS	296	Pros.	NS	9
Ikehara H 2010 (24)	CF-240Z* PCF-240ZI* CF-200Z* 0.05% Crystal	Invasive pattern	Vienna	> 1000 μ m	3	379	Retro.	W / O LST-G	11
Fukuzawa M, 2010 (19)	CF-H260AZI* PCF-240Z* 0.05% Crystal NBI	Invasive Pattern (Chromo) Original Classification (NBI)	Vienna	> 1000 μ m	3	112	Pros.	W / O Size < 10 mm	9
Wada Y, 2010 (18)	CF-H260AZI* 0.05% Crystal NBI	Kudo Classification (Chromo) Original Classification (NBI)	Vienna	> 1000 μ m	2	1473	Pros.	NS	9
Matsumoto K, 2011 (28)	CF-H260ZI* PCF-240Z* CF-240Z* 0.03% Crystal	Original Classification	Vienna	> 1000 μ m	NS	96	Retro.	W / O Size > 10 mm	7
Hirata M 2007 (27)	CF-H260ZI* NBI	Hiroshima Classification	Vienna	> 1000 μ m	2	189	Retro.	NS	10
Kanao H 2009 (25)	CF-H260ZI* NBI	Hiroshima Classification	Vienna	> 1000 μ m	3	289	Retro.	NS	9
Ikematsu H 2010 (7)	CF-H260ZI* NBI	Sano Classification	Vienna	> 1000 μ m	3	130	Pros.	NS	11
Yoshida N 2010 (26)	CF-H260ZI* PCF-240ZI* NBI	Sano Classification	Vienna	> 1000 μ m	2	111	Retro.	NS	10
Oba S, 2010 (20)	CF-260AZI* NBI	Hiroshima Classification	Vienna	> 1000 μ m	NS	189	Pros.	NS	11

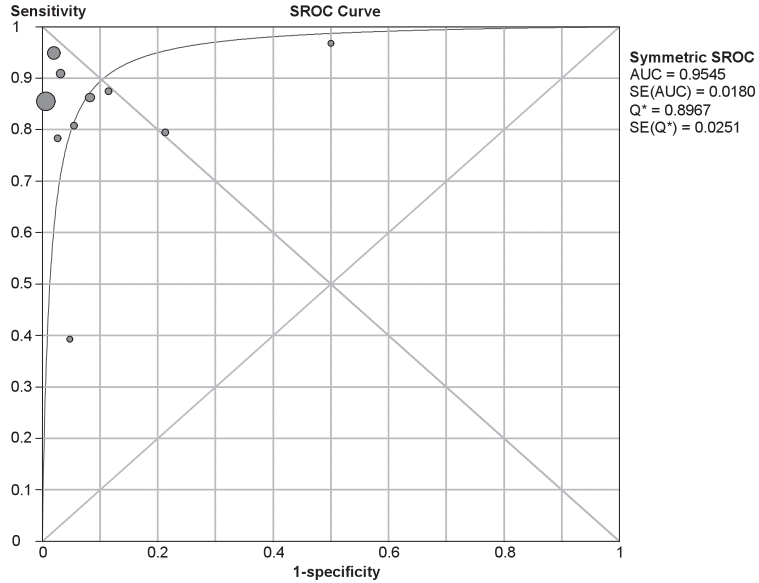
Crystal : crystal violet, Indigo : indigo carmine, Conc. : concentration, * : Olympus Co., Ltd., ** : Fujinon Co., Ltd,

Viena : Vienna classification, JRSCCR : Japanese Society for Cancer of the Colon and Rectum

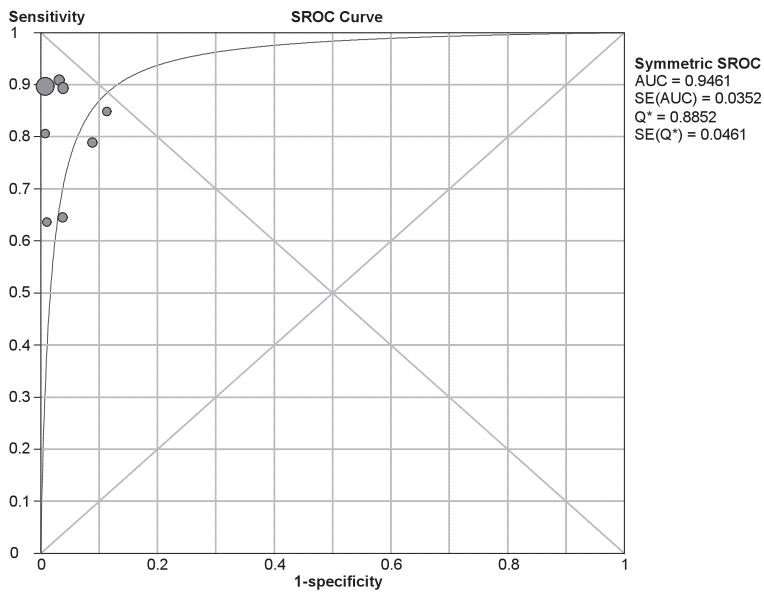
NS : not stated, SM : submucosa, LST-G : laterally spreading tumor (Granular type),

Chromo : chromoendoscopy, NBI : Narrow Band imaging, Pros. : prospective study, Retro : retrospective study,

W / O : study was conducted without the following condition.



(a) 2ROC Curve pooled Sensitivity of Chromoendoscopy

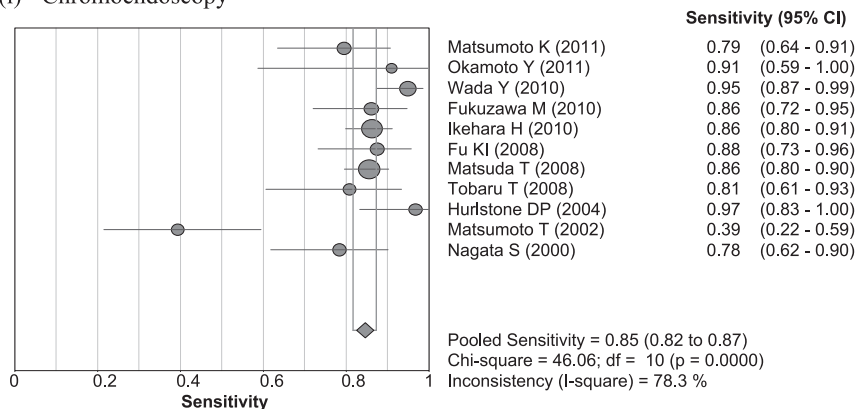


(b) 2ROC Curve pooled Sensitivity of NBI

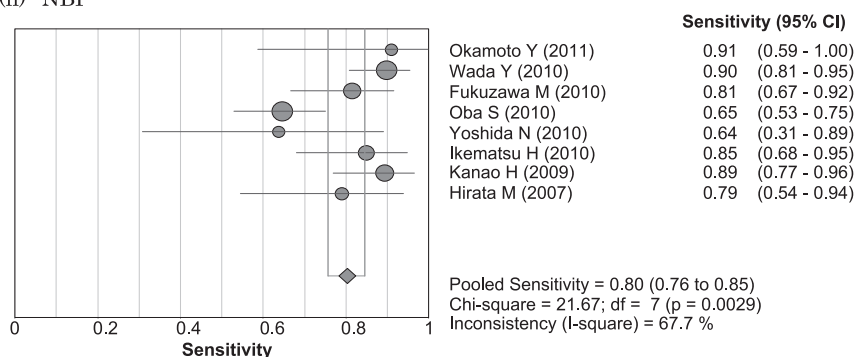
Fig. 2.

negative likelihood of 0.15 (0.09–0.25), whereas a pooled diagnostic performance analysis of NBI revealed a sensitivity of 0.80 (95%CI: 0.75–0.85), a specificity of 0.98 (0.97–0.98), a positive likelihood of 23.5 (10.3–53.5), and a negative likelihood of 0.19 (0.11–0.35) (Fig. 3 (c), (d), and Table 2). Heterogeneity was significant for all the aforementioned diagnostic performance measures for both chromoendoscopy and NBI.

(i) Chromoendoscopy



(ii) NBI



(a) Pooled Sensitivity of Chromoendoscopy and NBI for All Extracted Studies

Fig. 3.

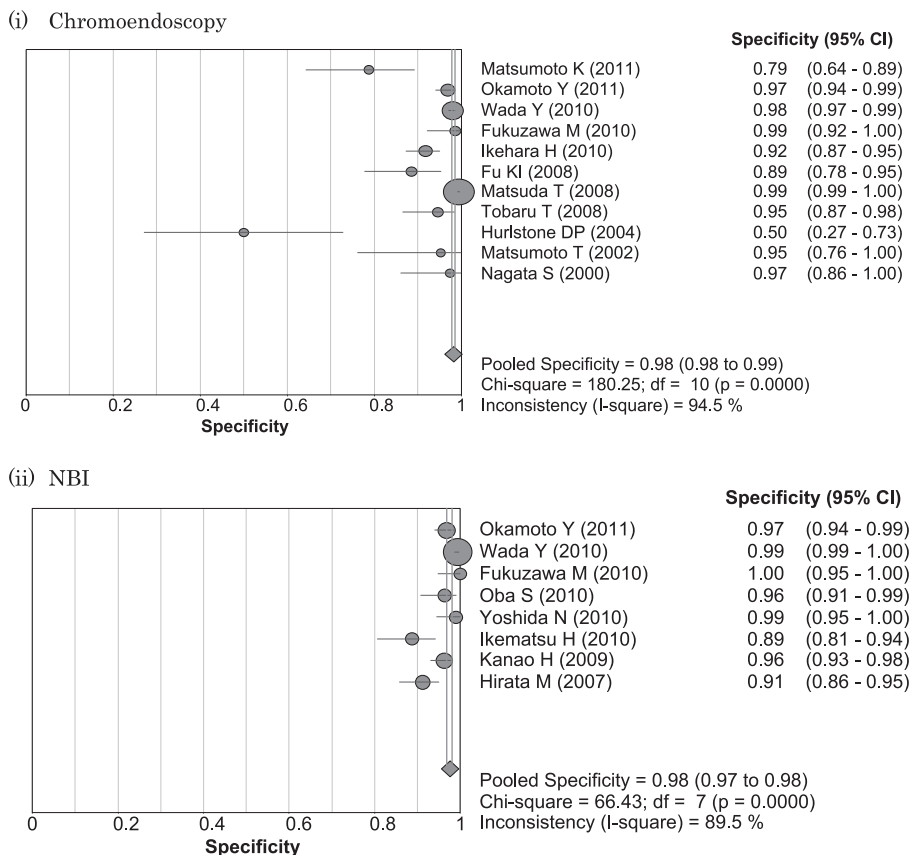
Meta-regression analysis for the source of heterogeneity

Based on the data extracted from each study, the source of heterogeneity was explored using meta-regression analysis in the models of the endoscope used, study design, QUADAS score, and target lesions. However, none of these factors had a statistically significant effect.

Comparing chromoendoscopy and NBI showed no significant difference in terms of discriminatory power both in a model of all extracted studies (β coefficient, -0.02 , 95% CI: -1.18 - 1.71) and taking only those studies with restricted criteria (β coefficient, -0.56 , 95% CI: -3.70 - 2.57).

Evaluation of publication bias

Begg's and Egger's test for all extracted studies suggested no significant publication bias based on Egger's test ($P = 0.166$), however, the funnel plot did not show a symmetric pattern, suggesting possible publication bias (Fig. 4). In contrast, testing only those studies with restricted criteria suggested significant publication bias by both analyses (Fig. 4).



(b) Pooled Specificity of Chromoendoscopy and NBI for All Extracted Studies

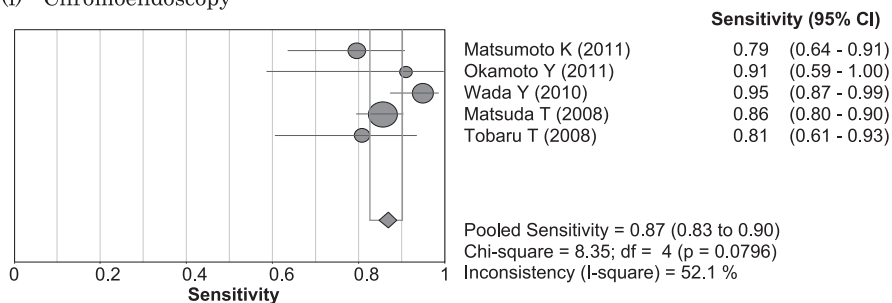
Fig. 3.

Discussion

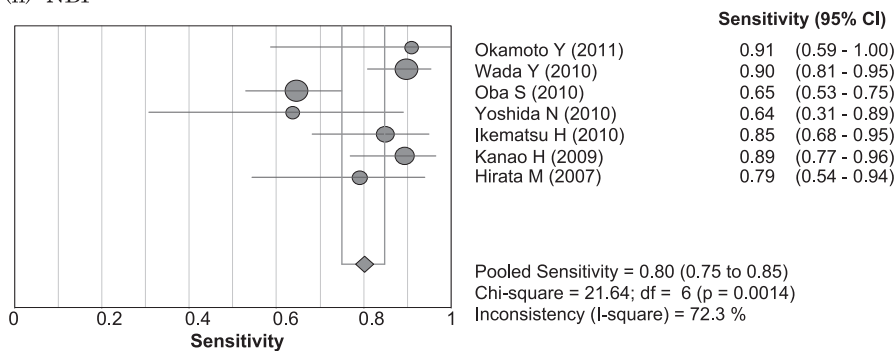
The ongoing development of therapeutic approaches for CRC has resulted in less invasive treatments, largely because of revolutionary endoscopic procedures. Endoscopic mucosal resection, in particular, has drastically changed CRC therapy because it allows recurrence of this malignancy to be controlled as long as the cancer is in an early stage. The range of therapeutic strategies was further expanded with the clinical application of laparoscopy-assisted colectomy and endoscopic submucosal dissection to colon in the late 90s and early 2000s. Hence, collaboration among endoscopists, surgeons, radiologists, and pathologists has now become increasingly important for determining the most appropriate therapeutic approach for a lesion that is discovered by chance in a screening study.

Several studies have indicated a relationship between pathological features and LN metastasis following resection of CRCs such that early tumors with the following features are considered likely to show LN metastasis: [1] massive submucosal invasion of cancer; [2] lymphatic or vascular invasion; and, [3] poorly differentiated histology²⁹. Among

(i) Chromoendoscopy



(ii) NBI



(c) Pooled Sensitivity of Chromoendoscopy and NBI for Studies with Restricted Criteria

Fig. 3.

these pathological features, massive submucosal invasion of CRC is the only factor that can be detected in preoperative endoscopy²⁾. However, taking biopsies is cumbersome because patients are required to stop anticoagulant agents for several days and much time is required to obtain the pathology results. Therefore, many endoscopists have established criteria for predicting massively invasive cancers to avoid biopsies and send such patients directly to the surgeons. For this reason, the use of a magnifying endoscope for detecting colonic polyps has increased dramatically in clinical settings.

The opening of a colonic crypt is referred to as a “pit”, and the specific arrangement of the gland openings in various lesions is called the “pit pattern”. This pattern is considered to reflect the epithelial aberrations originating in the luminal sector of the epithelium, meaning that changes in the deeper layers are reflected on the surface⁵⁾. In this respect, the diagnostic process that uses magnifying endoscopy is similar to that used by the examining pathologist, although discrepancies might exist between the pathological features of the surface and of deeper tissues⁵⁾. Several studies on the combined use of magnifying endoscopy and chromoendoscopy have led to acceptance of Kudo’s classification of pit patterns as a standard, and this classification is currently the most widely used system for differentiating normal mucosa from neoplasms^{3,5)}.

NBI is another diagnostic method that was recently introduced into clinical practice for

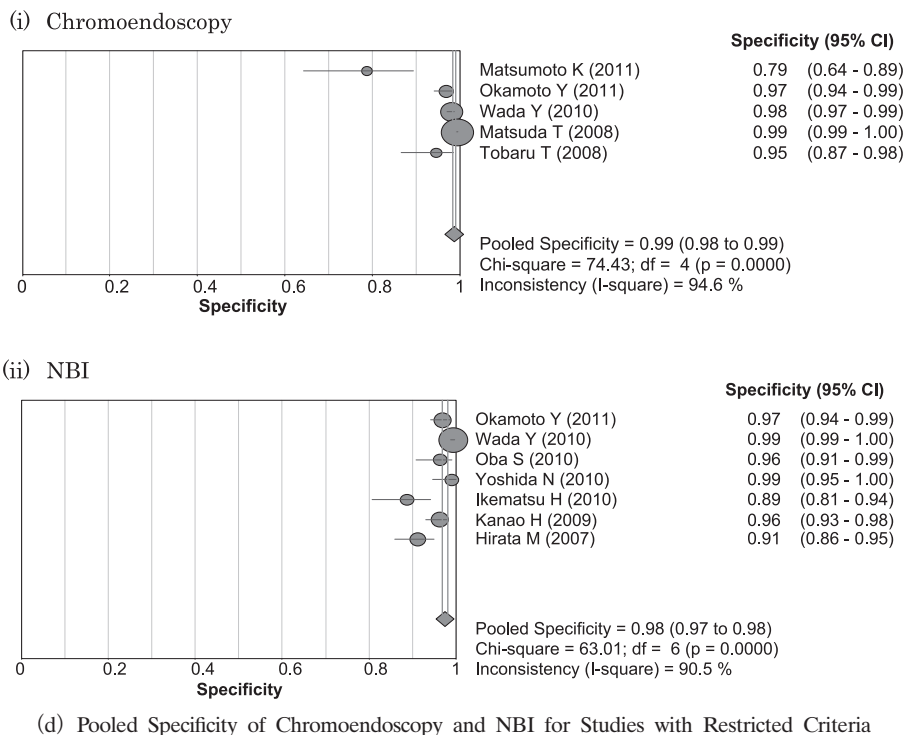


Fig. 3.

Table 2. Chromoendoscopy and NBI pooled analyses

	Number of Studies	Sensitivity (95%CI)	Specificity (95%CI)	LR +	LR -
Chromoendoscopy	11	0.85 (0.82-0.87)	0.98 (0.97-0.99)	16.1 (6.02-42.8)	0.17 (0.10-0.30)
NBI	8	0.80 (0.76-0.85)	0.98 (0.97-0.99)	25.7 (11.5-57.3)	0.20 (0.12-0.32)
Chromoendoscopy* (Study restriction)	5	0.87 (0.83-0.90)	0.99 (0.98-0.99)	26.0 (724-93.0)	0.15 (0.09-0.25)
NBI* (Study restriction)	7	0.80 (0.75-0.85)	0.98 (0.97-0.98)	23.5 (10.3-53.5)	0.19 (0.11-0.35)

LR + : likelihood positive, LR - : likelihood negative, * : studies with restricted criteria

both upper and lower endoscopy³⁰). This technology is based on narrowing the bandwidth of spectral transmittance of the optical filters used in the frame sequential image method for creating endoscopy images⁶). In doing so, NBI enables real-time imaging of capillary vessels in endoscopic images. Angiogenesis, which is the secondary growth of blood vessels, plays an important role in the growth and persistence of solid tumors. Although the vascular

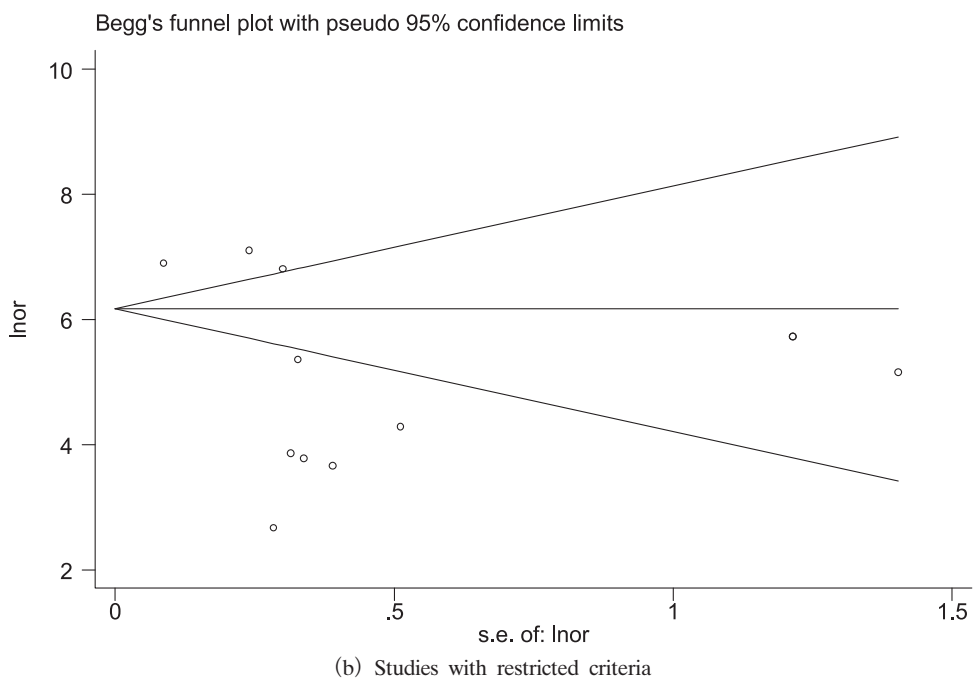
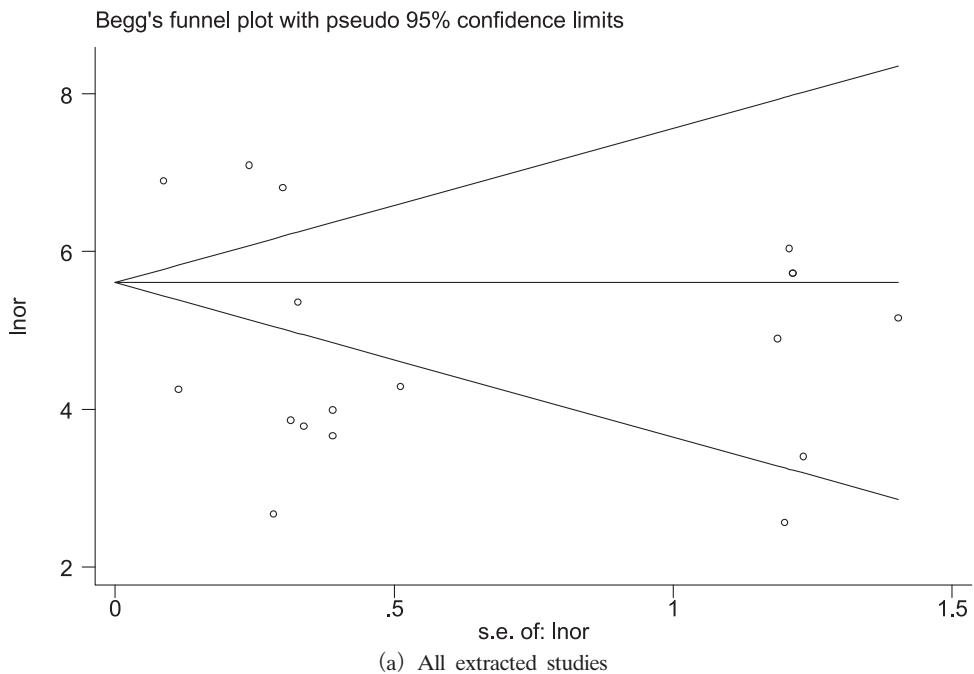


Fig. 4. Funnel plot assessing publication bias

architecture of adenomas is similar to that of the normal colon in having a regular and consistent caliber, microvessels in adenomas tend to be elongated with a wider diameter and in higher number than microvessels in normal mucosa. The number and density of capillaries in the interstitial space of colonic adenomas increases with size. Microvessels are also increased in both number and density in CRCs. Consequently, capillary patterns detected by NBI with magnification are typically well correlated with the histopathology of colorectal lesions⁶). The NBI system was first reported by Sano *et al* in 2001³⁰) and a number of subsequent studies have appeared since. Several classification systems for NBI surface patterns have also been proposed; however, none have yet been adopted as a standard. When used with magnifying endoscopy, NBI provides visualization of the mucosal pattern and surface microvasculature without the need for a dye spray.

The primary aim of the present meta-analysis study was to evaluate the diagnostic performance with respect to depth prediction of CRC using NBI and to compare the results to those obtained with chromoendoscopy. The sensitivity and specificity were 0.85 and 0.98, respectively, for chromoendoscopy, and 0.80 and 0.98 for NBI, and the regression coefficient for chromoendoscopy versus NBI was -0.02 (95% CI: $-1.18-1.71$). These results indicated a similarly strong diagnostic performance of both chromoendoscopy and NBI. However, the sensitivity and specificity were not 100% for either modality, suggesting the possibility of inappropriate indications for endoscopic and surgical treatment if pit pattern or NBI classifications were used. This is because both classifications are superficial diagnostic processes, and a small percentage of polyps might not reflect the full cancer histology on their surface. This is one of the limitations of these subjective classifications.

The NBI process without dye spray provides a user-friendly modality that now plays a central role in colorectal diagnosis. However, we consider that it might be too early to propose NBI as superior to chromoendoscopy, for two reasons. First, the NBI system itself is very expensive, especially considering that indicative colorectal lesions that would require precise observation by NBI are encountered rather rarely in routine clinical settings. For example, most of the institutions involved in the present are high-volume centers; however, even in such a setting, submucosal cancers account for only approximately 2.0% of all detected polyps, according to a study by Fu *et al*²). Therefore, the cases in which NBI can display its full capability may be scarce. Furthermore, no statistically significant difference may exist between the ability to detect a colonic polyp by NBI compared to conventional endoscopy³¹). For these reasons, the merit of using NBI remains controversial. Second, the NBI process seemed to be similar to that using dye spray with respect to time and effort when the polyps were covered with mucus, which has to be washed off with water several times prior to dye spraying. Therefore, it is difficult to conclude which is the better of these two modalities.

Our study had some limitations. First, the methodological consideration was the choice of diagnostic classification. Many chromoendoscopy studies refer to Kudo's classification;

however, some studies used their own original classifications. Similarly, many NBI studies refer to vascular patterns that differ to some extent from each other, even though Sano *et al*³⁰⁾ clearly proposed an NBI classification. Nevertheless, our meta-regression analysis indicated little difference in diagnostic performance between classification by chromoendoscopy and NBI; therefore, this heterogeneity in classification might have had little influence on the results. Second, publication bias might have affected our results, although there are no clearly defined methods for assessing publication bias among diagnostic test meta-analyses. Evidence from therapy trials indicates that statistically significant studies are more likely to be published, compared to smaller studies with no significant effects. Whether similar bias also exists for diagnostic trials is uncertain. Tests of publication bias in the therapy trials were based on a nonparametric measure of the relationship between the effect and the precision of the study. In the present study, Begg's test found a significant relationship between the test estimate and study precision. Therefore, a researcher who tests a diagnostic modality in a small sample and finds poor test performance is unlikely to publish the data, possibly resulting in an overestimation of diagnostic performance.

In conclusion, our analysis shows that chromoendoscopy and NBI have similar diagnostic power for the determination of the depth of cancer in colorectal neoplasms. While NBI may be preferable in most instances, the clinician's choice of image modality must take into account other important factors such as the examiner's experience and the overall objectives of diagnosis for polyps, together with convenience, time, and cost.

Acknowledgement

We would like to thank Dr. Hayashino and Dr. Kawakami (Kyoto University School of Public Health) for their advice on statistical analysis.

References

- 1) Foundation for Promotion of Cancer Research : Cancer Statistics in Japan 2010. http://ganjoho.ncc.go.jp/public/statistics/backnumber/2010_en.html, (accessed 2010-12-26) (in Japanese)
- 2) Fu KI, Kato S, Sano Y, Onuma EK, Saito Y, Matsuda T, Koba I, Yoshida S and Fujii T: Staging of early colorectal cancers : magnifying colonoscopy versus endoscopic ultrasonography for estimation of depth of invasion. *Dig Dis Sci* **53** : 1886-1892 (2008)
- 3) Kudo S, Tamura S, Nakajima T, Yamano H, Kusaka H and Watanabe H : Diagnosis of colorectal tumorous lesions by magnifying endoscopy. *Gastrointest Endosc* **44** : 8-14 (1996)
- 4) Kitajima K, Fujimori T, Fujii S, Takeda J, Ohkura Y, Kawamata H, Kumamoto T, Ishiguro S, Kato Y, Shimoda T, Iwashita A, Ajioka Y, Watanabe H, Watanabe T, Muto T and Nagasako K : Correlations between lymph node metastasis and depth of submucosal invasion in submucosal invasive colorectal carcinoma : a Japanese collaborative study. *J Gastroenterol* **39** : 534-543 (2004)
- 5) Kudo S, Rubio CA, Teixeira CR, Kashida H and Kogure E : Pit pattern in colorectal neoplasia : endoscopic magnifying view. *Endoscopy* **33** : 367-373 (2001)
- 6) Sano Y, Ikematsu H, Fu KI, Emura F, Katagiri A, Horimatsu T, Kaneko K, Soetikno R and Yoshida S : Meshed capillary vessels by use of narrow-band imaging for differential diagnosis of small colorectal polyps. *Gastrointest Endosc* **69** : 278-283 (2009)
- 7) Ikematsu H, Matsuda T, Emura F, Saito Y, Uraoka T, Fu KI, Kaneko K, Ochiai A, Fujimori T and Sano Y :

- Efficacy of capillary pattern type IIIA/IIIB by magnifying narrow band imaging for estimating depth of invasion of early colorectal neoplasms. *BMC Gastroenterol* **10** : 33 (2010)
- 8) Whiting P, Rutjes AW, Reitsma JB, Bossuyt PM and Kleijnen J: The development of QUADAS: a tool for the quality assessment of studies of diagnostic accuracy included in systematic reviews. *BMC Med Res Methodol* **3** : 25 (2003)
 - 9) DerSimonian R and Laird N: Meta-analysis in clinical trials. *Control Clin Trials* **7** : 177-188 (1986)
 - 10) Agresti A and Coull BA: Approximate is better than "exact" for interval estimation of binominal proportions. *Am Stat* **52** : 119-126 (1998)
 - 11) Higgins JP, Thompson SG, Deeks JJ and Altman DG: Measuring inconsistency in meta-analyses. *BMJ* **327** : 557-560 (2003)
 - 12) van Houwelingen HC, Arends LR and Stijnen T: Advanced methods in meta-analysis: multivariate approach and meta-regression. *Stat Med* **21** : 589-624 (2002)
 - 13) Egger M, Davey Smith G, Schneider M and Minder C: Bias in meta-analysis detected by a simple, graphical test. *BMJ* **315** : 629-634 (1997)
 - 14) Littenberg B and Moses LE: Estimating diagnostic accuracy from multiple conflicting reports: a new meta-analytic method. *Med Decis Making* **13** : 313-321 (1993)
 - 15) Hurlstone DP, Cross SS, Adam I, Shorhouse AJ, Brown S, Sanders DS and Lobo AJ: Endoscopic morphological anticipation of submucosal invasion in flat and depressed colorectal lesions: clinical implications and subtype analysis of the kudo type V pit pattern using high-magnification-chromoscopic colonoscopy. *Colorectal Dis* **6** : 369-375 (2004)
 - 16) Matsuda T, Fujii T, Saito Y, Nakajima T, Uraoka T, Kobayashi N, Ikehara H, Ikematsu H, Fu KI, Emura F, Ono A, Sano Y, Shimoda T and Fujimori T: Efficacy of the invasive / non-invasive pattern by magnifying chromoendoscopy to estimate the depth of invasion of early colorectal neoplasms. *Am J Gastroenterol* **103** : 2700-2706 (2008)
 - 17) Okamoto Y, Watanabe H, Tominaga K, Oki R, Yamagata M, Yokotsuka F, Ishida M, Masuyama H and Hiraishi H: Evaluation of microvessels in colorectal tumors by narrow band imaging magnification: including comparison with magnifying chromoendoscopy. *Dig Dis Sci* **56** : 532-538 (2011)
 - 18) Wada Y, Kashida H, Kudo SE, Misawa M, Ikehara N and Hamatani S: Diagnostic accuracy of pit pattern and vascular pattern analyses in colorectal lesions. *Dig Endosc* **22** : 192-199 (2010)
 - 19) Fukuzawa M, Saito Y, Matsuda T, Uraoka T, Itoi T and Moriyasu F: Effectiveness of narrow-band imaging magnification for invasion depth in early colorectal cancer. *World J Gastroenterol* **16** : 1727-1734 (2010)
 - 20) Oba S, Tanaka S, Oka S, Kanao H, Yoshida S, Shimamoto F and Chayama K: Characterization of colorectal tumors using narrow-band imaging magnification: combined diagnosis with both pit pattern and microvessel features. *Scand J Gastroenterol* **45** : 1084-1092 (2010)
 - 21) Nagata S, Tanaka S, Haruma K, Yoshihara M, Sumii K, Kajiyama G and Shimamoto F: Pit pattern diagnosis of early colorectal carcinoma by magnifying colonoscopy: clinical and histological implications. *Int J Oncol* **16** : 927-934 (2000)
 - 22) Matsumoto T, Hizawa K, Esaki M, Kurahara K, Mizuno M, Hirakawa K, Yao T and Iida M: Comparison of EUS and magnifying colonoscopy for assessment of small colorectal cancers. *Gastrointest Endosc* **56** : 354-360 (2002)
 - 23) Tobaru T, Mitsuyama K, Tsuruta O, Kawano H and Sata M: Sub-classification of type VI pit patterns in colorectal tumors: relation to the depth of tumor invasion. *Int J Oncol* **33** : 503-508 (2008)
 - 24) Ikehara H, Saito Y, Matsuda T, Uraoka T and Murakami Y: Diagnosis of depth of invasion for early colorectal cancer using magnifying colonoscopy. *J Gastroenterol Hepatol* **25** : 905-912 (2010)
 - 25) Kanao H, Tanaka S, Oka S, Hirata M, Yoshida S and Chayama K: Narrow-band imaging magnification predicts the histology and invasion depth of colorectal tumors. *Gastrointest Endosc* **69** : 631-636 (2009)
 - 26) Yoshida N, Naito Y, Kugai M, Inoue K, Uchiyama K, Takagi T, Ishikawa T, Handa O, Konishi H, Wakabayashi N, Kokura S, Yagi N, Morimoto Y, Yanagisawa A and Yoshikawa T: Efficacy of magnifying endoscopy with

- flexible spectral imaging color enhancement in the diagnosis of colorectal tumors. *J Gastroenterol Hepatol* **26** : 286–291 (2010)
- 27) Hirata M, Tanaka S, Oka S, Kaneko I, Yoshida S, Yoshihara M and Chayama K: Evaluation of microvessels in colorectal tumors by narrow band imaging magnification. *Gastrointest Endosc* **66** : 945–952 (2007)
 - 28) Matsumoto K, Nagahara A, Terai T, Ueyama H, Ritsuno H, Mori H, Nakae K, Beppu K, Shibuya T, Sakamoto N, Osada T, Ogihara T, Yao T and Watanabe S: Evaluation of new subclassification of type V(I) pit pattern for determining the depth and type of invasion of colorectal neoplasm. *J Gastroenterol* **46** : 31–38 (2011)
 - 29) Netzer P, Forster C, Biral R, Ruchti C, Neuweiler J, Stauffer E, Schonegg R, Maurer C, Husler J, Halter F and Schmassmann A: Risk factor assessment of endoscopically removed malignant colorectal polyps. *Gut* **43** : 669–674 (1998)
 - 30) Sano Y, Kobayashi M, Kato S, Fu KI, Hamamoto Y, Yoshino T, Yoshida S, Kozu T and Fujii T: New diagnostic method based on color imaging using narrow band imaging (NBI) system for gastorointestinal tract. *Gastrointest Endosc* **53** : AB125 (2001)
 - 31) Adler A, Pohl H, Papanikolaou IS, Abou-Rebyeh H, Schachschal G, Veltzke-Schlieker W, Khalifa AC, Setka E, Koch M, Wiedenmann B and Rosch T: A prospective randomised study on narrow-band imaging versus conventional colonoscopy for adenoma detection: does narrow-band imaging induce a learning effect? *Gut* **57** : 59–64 (2008)

[Received February 22, 2011 : Accepted March 9, 2011]