

## Case Report

### An Autopsy Case of Multiple Jejunal Diverticula Showing Severe Malabsorption

Tetsuya MIKOGAMI<sup>1)</sup>, Toshiaki KUNIMURA<sup>1)</sup>, Mutsuko OMATSU<sup>1)</sup>,  
Shigeharu HAMATANI<sup>1)</sup>, Akira SHIOKAWA<sup>1)</sup>, Kodai HIRABAYASI<sup>2)</sup>,  
Yojiro KAWAMURA<sup>2)</sup>, Masayuki ISOZAKI<sup>2)</sup>, Hidetsugu TATENO<sup>2)</sup>  
and Toshio MOROHOSHI<sup>2)</sup>

**Abstract:** A rare autopsy case of multiple jejunal diverticula showing severe malabsorption is reported. A 56-year-old man was admitted due to vomiting and leg edema. On admission, his height was 160 cm, his body weight was 39 kg, and laboratory data revealed severe hypoproteinemia (TP: 4.0 g/dl, ALB: 2.1 g/dl). On the 14<sup>th</sup> day of admission, agonal breathing and disturbance of consciousness occurred after massive vomiting of gastric juice, and the patient died of respiratory failure. At autopsy, on abdominal sectioning, multiple diverticula situated on the mesenterium side of the enteron extending 70 cm in length from the proximal jejunum were identified. However there were no findings suggesting perforation or diverticulitis. Histologically, the diverticula were lined by ordinal jejunum mucosa associated with muscularis mucosa, but the muscularis propria was not involved in the diverticular walls. The diverticula were identified as false diverticula. In both lower lungs, aspiration pneumonia was widely seen. The cause of death was considered to be aspiration pneumonia due to the vomiting caused by multiple jejunal diverticula.

Only 16 case reports of multiple jejunal diverticulosis in Japan could be found in the literature however most of the reported complications were perforation and diverticulitis, and there were no reports of malabsorption. Therefore, the present case is significant concerning the cause of malabsorption in routine explorations.

**Key words:** multiple jejunal diverticulosis, malabsorption, autopsy

## Introduction

Patients with multiple jejunal diverticulosis are rare, with only 16 case reports available in Japan<sup>1,2)</sup>. We report here a rare autopsy case of multiple jejunal diverticulosis showing severe malabsorption.

---

<sup>1)</sup> Department of Clinico-diagnostic Pathology, Showa University Northern Yokohama Hospital, 35-1, Chigasaki-Chuoh, Tsuzuki-ku, Yokohama-city 224-8503, Japan.

<sup>2)</sup> Department of Pathology, Showa University School of Medicine

## Case report

A 56-year-old man was admitted to our hospital due to vomiting and leg edema. Diarrhea was not reported. Physical examination upon admission revealed edema in both legs and pale skin color. His height was 160 cm, and body weight was 36.1 kg. Blood pressure was 83/53 mmHg, and no neurological signs were observed. Laboratory data upon admission revealed mild anemia (RBC: 3470000/ $\mu$ l, Hb: 10.1 g/dl, Ht: 30.7%) and severe hypoproteinemia (TP: 4.0 g/dl, ALB: 2.1 g/dl). Other data were as follows: WBC: 4100/ $\mu$ l, PLT: 164000/ $\mu$ l, AST: 38 IU/L, ALT: 27 IU/l, LDH: 398 IU/l, BUN: 17.2 mg/dl, Crea: 1.04 mg/dl, UA: 6.2 mg/dl, Na: 137 mEq/l, K: 3. mEq/l, Cl: 100 mEq/l, Glu: 78 mg/dl, CRP: 0.09 mg/dl. A chest X-P revealed mild elevation of cardio-thoracic ratio, and an abdominal X-P revealed dilatation of the small intestine due to gas, and there was no evidence of ileus. From these findings, malabsorption was considered first, and upper endoscopic examination was undertaken. Hiatus herniation was found, but there was no other obvious finding suggesting malabsorption within the stomach and duodenal bulb. Other examinations to differentiate from protein-losing gastroenteropathy, such as estimation of fat content and alpha1-antitrypsin analysis of stool, were not carried out.

The patient had mild mental retardation, and attended a special class for handicapped children until junior high school. He had been healthy until this admission, and the other members of his family appeared to be free of hereditary disease or malignant tumors.

After admission, the patient was medicated with diuretic drugs (Frusemide, Spironolactone), and an antihypertensive drug (Lisinopril hydrate), and leg edema was improved. However, treatment with Sennoside A B calcium and Famotidine did not improve vomiting and appetite loss, and the cause of malabsorption was still unclear. One week after admission, sleep tendency and depression of consciousness level occurred, and the intravenous drip and antihypertensive drug were withdrawn. However the patient's condition did not improve, and the cause was unclear. On the 14<sup>th</sup> day of admission, agonal breathing and disturbance of consciousness appeared after massive vomiting of gastric juice. A brain CT did not show any obvious disorder, but a chest X-P revealed an infiltrating shadow in both lower lobes of the lungs. The patient died of respiratory failure on the 16<sup>th</sup> day of admission due to aspiration pneumonia and an autopsy was performed.

## Autopsy findings

At autopsy, his height was 160 cm, and body weight was 39 kg, with severe emaciation. Abdominal sectioning showed multiple diverticula, each approximately 5 cm in diameter, situated on the mesentrium side of the enteron extending 70 cm from the proximal jejunum (Figs. 1, 2). The surface of each diverticulum was normal in color, and was not suggestive of hemorrhage or diverticulitis. There was no obvious ascetic fluid. The diverticular contents were found to be intestinal juice, and there was no hemorrhagic or purulent fluid.

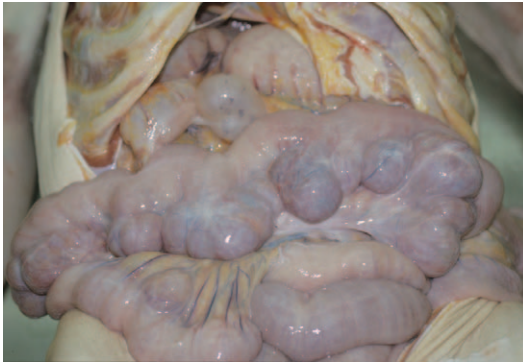


Fig. 1. Macroscopic findings of jejunal diverticulosis. On abdominal sectioning, multiple diverticula were observed.

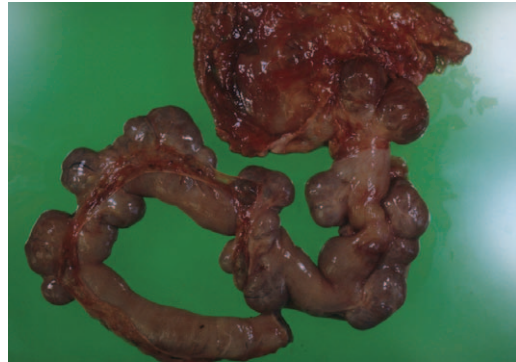

Fig. 2. Macroscopic findings of excised jejunal diverticulosis.

The diverticula were situated on the mesenteric side of the enteron, extending 70 cm from the proximal jejunum, and were each approximately 5 cm in diameter.

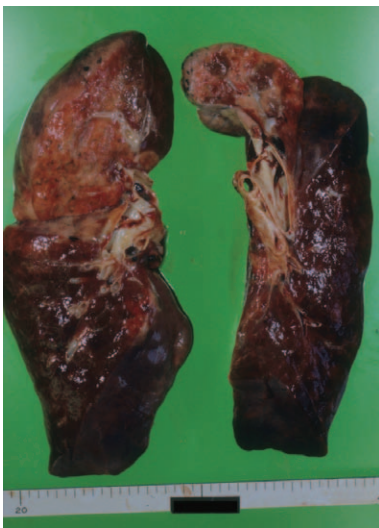

Fig. 3. Macroscopic findings of lungs. Both lower lungs were dark red in color.

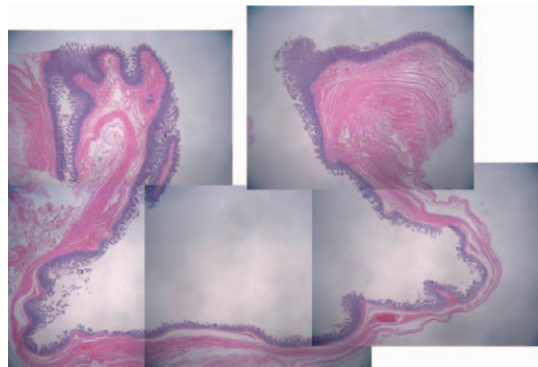


Fig. 4. Low power view of jejunal diverticulosis. The diverticula were lined by ordinal jejunal mucosa without any heterotopic component such as pancreatic acinar or gastric fundic glands. (H.E. staining,  $\times 1.25$ )

Both lower lungs were dark red-colored and weighed 600 g on the left and 630 g on the right, and did not float in water (Fig. 3). Other organs were normal in appearance.

Microscopically, the diverticula were lined by ordinal jejunum mucosa without any heterotopic components such as pancreatic acinar or gastric fundic glands (Fig. 4). The lining mucosa was associated with muscularis mucosa, but muscularis propria was not involved in the walls (Fig. 5) and the diverticula were identified as false diverticula. There were no inflammatory foci suggesting diverticulitis or perforation. Lymphangiectasia suggesting protein-losing gastroenteropathy could not be seen. In both lower lungs, diffuse neutrophilic infiltration was observed from the terminal bronchus to the alveoli (Fig. 6), and foreign bodies were focally observed, suggesting aspiration pneumonia. Pericardial adipose tissue

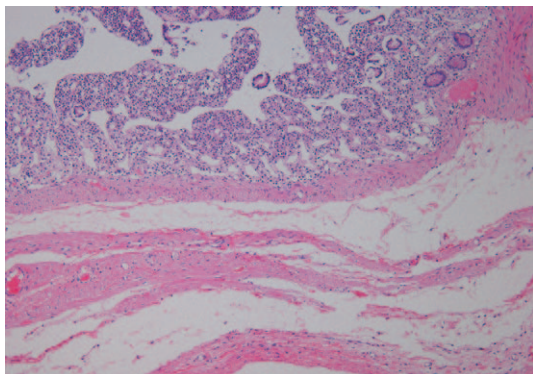


Fig. 5. High power view of jejunal diverticulosis  
The lining mucosa was associated with muscularis mucosa, but muscularis propria was not involved in the diverticular walls. (H.E. staining,  $\times 20$ )

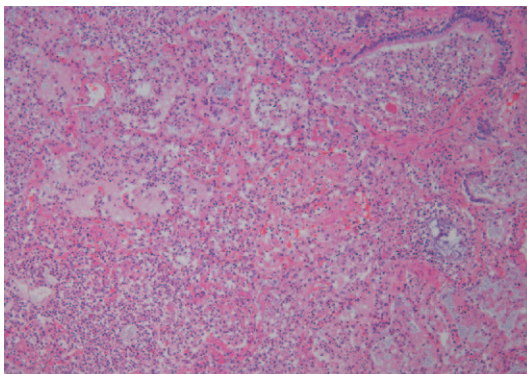


Fig. 6. Low power view of left lower lung  
Diffuse neutrophilic infiltration was observed from the terminal bronchus to the alveoli. (H.E. staining,  $\times 10$ )

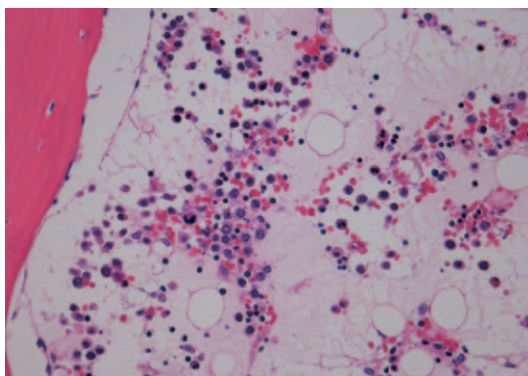


Fig. 7. High power view of bone marrow  
Bone marrow showed jelly-like degeneration suggesting malnutrition. (H.E. staining,  $\times 40$ )

and bone marrow showed jelly-like degeneration (Fig. 7) suggesting malnutrition. Liver, spleen and kidneys showed mild congestion, but there was no obvious disorder in other organs. Cause of death was considered to be aspiration pneumonia due to vomiting caused by multiple jejunal diverticulosis.

## Discussion

Small bowel diverticular disease is a pathological entity that is not easily diagnosed. However, it can be a source of vomiting and malabsorption, and should be considered in the patient who has no other obvious pathology noted on physical examination or radiological evaluation<sup>3)</sup>. Akhrass *et al*<sup>4)</sup> reported that complications developed in 42 (20 percent) of 208 small bowel diverticular disease patients. These included bleeding in 14, diverticulitis with perforation and abscess formation in 12, and malabsorption in 8 patients.

Diverticular disease of the small intestine is reported to be distributed as follows: 60%–70% duodenal, 20%–25% jejunal, and 5%–10% ileal<sup>5)</sup>. The majority of cases of jejunal diverticulosis have been noted in patients in their sixth and seventh decades of life<sup>6)</sup>. The literature estimates that jejunal diverticulosis has an incidence of 0.02% to 7.1% (reference?). Maglinte *et al*<sup>7)</sup> described an incidence of small bowel diverticular disease of 2.3%, based on enteroclysis studies. In an autopsy series, Palder and Frey<sup>8)</sup> described the incidence of jejunal diverticula to be 0.06% to 1.3%.

Cases of jejunal diverticulosis can be complicated not only by diverticulitis, but by hemorrhage, perforation, intussusception, volvulus or malabsorption<sup>9–11)</sup>. Although there have been 16 case reports of multiple jejunal diverticulosis in Japan<sup>1,2)</sup>, most of the reported complications are perforation and diverticulitis, and there are no reports of malabsorption. Therefore, the present case is significant, describing a cause of malabsorption detected during routine exploration. According to Fukuda<sup>12)</sup>, the causes of malabsorption are divided into three groups: intraluminal phase, intestinal phase and removal phase. In multiple jejunal diverticulosis, an abnormal proliferation of enterobacterium occurs, and this can be a cause of intraluminal phase malabsorption.

The pathogenesis of small bowel diverticular disease is believed to be as follows. Intraluminal pressure is increased in a particular segment of bowel due to gut dysmotility, resulting in mucosal herniation along the mesenteric border of the bowel<sup>13)</sup>. This makes the majority of jejunal diverticular disease a type of false diverticulosis, as there is no muscularis propria involved. With respect to the location of the diverticula, the mesenteric border of the bowel is more susceptible because there is an innate weakening of the wall due to entry of mesenteric blood vessels on that side. The present case showed these typical pathologic features, however, the size was larger than the average small bowel diverticulum. According to Fukuda *et al*<sup>14)</sup>, each diverticulum is less than 0.5 cm in size in more than 80% of cases, but those in the present case were each about 5 cm in diameter. In this case it is likely that the presence of multiple large jejunal diverticula was the cause of the clinical symptoms such as vomiting and malabsorption which were observed.

In conclusion, we should take into consideration during routine exploration that multiple jejunal diverticula can be a cause of vomiting and malabsorption.

## References

- 1) Sato T, Abe T, Tsuchiya H, Fujiwara K, Akaishi S and Shinozawa Y: A case treated by three laparotomies within two years for multiple diverticuloses of the small intestine. *J Jpn Assoc Acute Med* **21**: 252–256 (2010) (in Japanese)
- 2) Danno K, Ohnishi T, Inatome J, Kano T, Tono T and Monden T: A case of multiple jejunal diverticula penetrating into the mesentery. *J Jpn Surg Assoc* **72**: 2153–2157 (2011) (in Japanese)
- 3) Chugay P, Choi J and Dong XD: Jejunal diverticular disease complicated by enteroliths: report of two different presentations. *World J Gastrointest Surg* **2**: 26–29 (2010)
- 4) Akhrass R, Yaffe MB, Fischer C, Ponsky J and Shuck JM: Small-bowel diverticulosis: perceptions and reality. *J*



- Am Coll Surg* **184** : 383-388 (1997)
- 5) Crace PP, Grisham A and Kerlakian G: Jejunal diverticular disease with unborn enterolith presenting as a small bowel obstruction : a case report. *Am Surg* **73** : 703-705 (2007)
  - 6) Lobo DN, Braithwaite BD and Fairbrother BJ: Enterolith ileus complicating jejunal diverticulosis. *J Clin Gastroenterol* **29** : 192-193 (1999)
  - 7) Maglinte DD, Chernish SM, DeWeese R, Kelvin FM and Brunelle RL: Acquired jejunoileal diverticular disease : subject review. *Radiology* **158** : 577-580 (1986)
  - 8) Palder SB and Frey CB: Jejunal diverticulosis. *Arch Surg* **123** : 889-894 (1988)
  - 9) Chiu EJ, Shyr YM, Su CH, Wu CW and Lui WY: Diverticular disease of the small bowel. *Hepatogastroenterology* **47** : 181-184 (2000)
  - 10) Edwards HC: Diverticulosis of the small intestine. *Ann Surg* **103** : 230-254 (1936)
  - 11) Williams RA, Davidson DD, Serota AI and Wilson SE: Surgical problems of diverticula of the small intestine. *Surg Gynecol Obstet* **152** : 621-626 (1981)
  - 12) Fukuda Y: Malabsorption syndrome. *J Jpn Soc Parenter Enteral Nutr* **27** : 5-17 (2012) (in Japanese)
  - 13) Harris LM, Volpe CM and Doerr RJ: Small bowel obstruction secondary to enterolith impaction complicating jejunal diverticulitis. *Am J Gastroenterol* **92** : 1538-1540 (1997)
  - 14) Fukuda Y, Tamura K and Hirakawa H: Diverticulosis of small intestine. *Clin Gastroenterol* **3** : 697-705 (1988) (in Japanese)

[Received August 3, 2012 : Accepted August 29, 2012]