

Case Report

A Case of Unusual Polypoid Mixed Hemangioma of the Sigmoid Colon : Possibly an Angioadenomatous Polyp

Toshiaki KUNIMURA¹⁾, Mutsuko OMATSU¹⁾, Tetsuya MIKOGAMI¹⁾,
Shigeharu HAMATANI¹⁾, Akira SHIOKAWA¹⁾, Genki TSUKUDA²⁾,
Yusuke WADA²⁾, Kunio ASONUMA²⁾, Kodai HIRABAYASHI²⁾,
Yojiro KAWAMURA²⁾, Masayuki ISOZAKI²⁾, Hidetsugu TATENO²⁾
and Toshio MOROHOSHI²⁾

Abstract : Herein, we report on an unusual case of polypoid mixed hemangioma of the sigmoid colon. An 85-year-old woman who underwent colonoscopic examination was found to have a smooth, red polypoid tumor, 6 mm in diameter, in the sigmoid colon. The polyp was resected endoscopically. Microscopically, the polyp contained two pathologic components : (i) adenomatous proliferative glands as the epithelial component ; and (ii) mixed hemangioma as the mesenchymal component. On the basis of these findings, a pathological diagnosis of angioadenomatous polyp was made. Although seven previous cases of polypoid hemangioma located in the submucosa have been reported in the literature, the present case is the first in which the hemangioma is localized only in the mucosa. The mixed hemangioma may be the pathogen stimulating the adenomatous proliferation of the glands.

Key words : colon, polyp, mixed hemangioma, mucosa

Introduction

Herein we report on an unusual case of polypoid mixed hemangioma of the sigmoid colon that was removed successfully by endoscopic mucosal resection (EMR).

Case Report

An 85-year-old woman was admitted to our hospital after a screening examination detected occult blood in the stool. Colonoscopic examination revealed a smooth, red, 6-mm diameter polypoid tumor in the sigmoid colon. The polyp was removed successfully by EMR, although there was slight blood loss during the procedure. The patient had been healthy until this admission, and the other members of her family appeared free of hereditary disease or malignant tumors.

¹⁾ Department of Clinico-diagnostic Pathology, Showa University Northern Yokohama Hospital, 35-1 Chigasaki-Chuoh, Tsuzuki-ku, Yokohama 224-8503, Japan.

²⁾ Department of Pathology, Showa University School of Medicine

Microscopically, mildly atypical tubular glands were seen proliferating in the mucosa of the polypoid tumor (Fig. 1) in association with an increased nuclear:cytoplasmic (N/C) ratio. In addition, some mitotic figures were observed (Fig. 2). However, the colonic epithelial cells in the atypical glands exhibited maturation from the crypts to the apical surface. On this basis, the glands were identified as reactive proliferative adenomatous glands rather than adenoma as a true neoplastic lesion. Moreover, dilated vascular structures covered by endothelium without nuclear polymorphism (suggestive of hemangioma) were noted in the lamina propria, and the vascular spaces were filled with blood (Fig. 3a). Immunohistochemically, the endothelium was positive for both CD31 (Fig. 3b) and CD34, but was negative for D2-40. These findings support the histological findings of hemangioma. Moreover, because the vascular structures were located on the far side from the endoscopic cut-off margin and there was no heat-denaturation of red blood cells, the lesion was unlikely to have been caused by the artificial dilation of vessels during endoscopic resection. Serial sections revealed that the lesion contained both small vascular spaces, suggestive of capillary hemangioma (Fig. 4a), and large vascular spaces, suggestive of cavernous hemangioma (Fig. 4b). Thus, the lesion was determined to be a mixed-type hemangioma. The hemangioma component was well demarcated and localized only in the lamina propria and not in the submucosa. These findings indicated that the polypoid tumor consisted of two pathologic components: (i) adenomatous proliferative glands as the epithelial component, and (ii) mixed hemangioma as the mesenchymal component. On the basis of the findings, a pathological diagnosis of angioadenomatous polyp was made.

Discussion

Colonic hemangioma is a rare, benign tumor usually localized at the rectum and sigmoid colon. A PubMed search of the literature revealed seven previously reported cases of colonic polypoid hemangioma¹⁻⁴. Microscopically, the cavernous hemangioma was located in the submucosa in five of the cases and it was located predominantly in the submucosa rather than mucosa in two cases. However, there has been no report published to date of a case of hemangioma localized within the mucosa. It is reasonable to assume that hemangiomas would be primarily localized in the submucosa because they arise from submucosal vascular plexuses⁵. The present case is the first reported case in which the polypoid hemangioma is localized only in the mucosa.

An angiokeratoma of the skin is known as a pedunculated vascular tumor. It is defined histologically as one or more dilated blood vessels lying directly subepidermally and exhibiting an epidermal proliferative reaction. The pathogen has been identified as capillary ectasia in the papillary dermis, with the epidermal changes being secondary to the ectasia⁶. In the present case of colonic polypoid tumor, the mixed hemangioma was lying directly on the colonic glands in the lamina propria, with the glands exhibiting a proliferative reaction. Similar to angiokeratoma, the mixed hemangioma arising in the lamina propria may be the

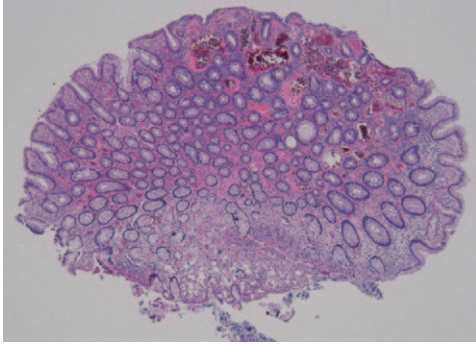


Fig. 1. Low-power view of the angioadenomatous polyp in the sigmoid colon. Mildly atypical tubular glands were found proliferating in the mucosa, with dilated vascular structures noted in the lamina propria. (Hematoxylin and eosin stain; original magnification $\times 125$).

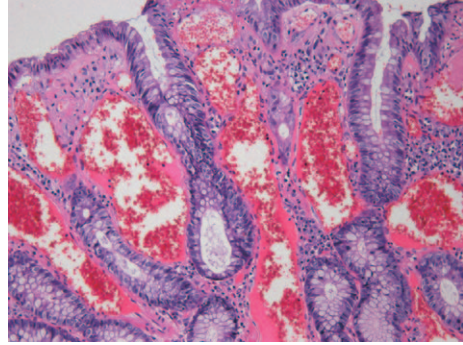


Fig. 2. Intermediate-power view of the angioadenomatous polyp in the sigmoid colon. An increased N/C ratio and some mitotic figures were observed in the proliferating glands, whereas the dilated vascular structures in the lamina propria showed mixed hemangioma. (Hematoxylin and eosin stain; original magnification $\times 20$).

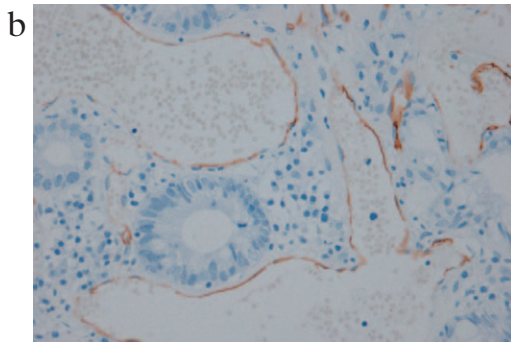
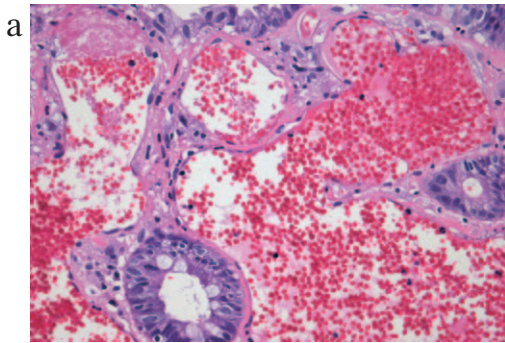


Fig. 3. High-power view of the angioadenomatous polyp in the sigmoid colon.
 (a) The dilated vascular structures were covered by the endothelium without nuclear polymorphism. The vascular spaces were filled with blood. (Hematoxylin and eosin stain; original magnification $\times 40$).
 (b) The endothelium was positive for CD31 (immunohistochemistry; original magnification $\times 40$).

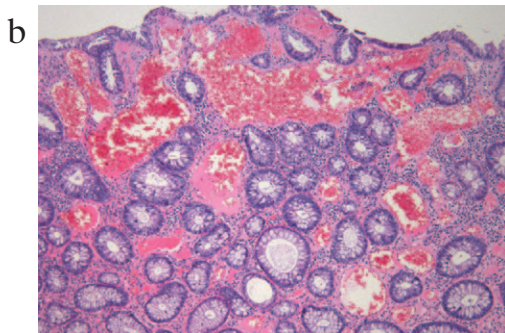
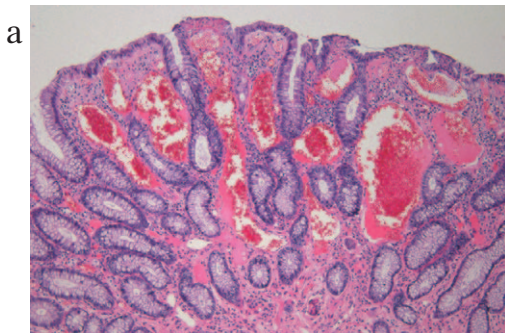


Fig. 4. Serial sections of the angioadenomatous polyp in the sigmoid colon.
 (a) Mildly dilated vascular spaces resembling capillary hemangioma can be seen.
 (b) Highly dilated vascular spaces resembling cavernous hemangioma are shown. (Hematoxylin and eosin stain; original magnification $\times 20$).

pathogen that stimulated the adenomatous proliferation of the glands in the present case, resulting in the development of the pedunculated polyp. Although another possible pathogen for this tumor may be a so-called mixed tumor (i.e. a mixture of colonic adenoma and hemangioma), because of the cellular maturation within the crypts and the limited atypia, we would interpret the findings to indicate a reactive adenomatous lesion rather than an adenoma. Thus we identified the tumor in our patient as an angioadenomatous polyp of the colon on the basis of its microscopic structure.

References

- 1) Kimura S, Tanaka S, Kusunoki H, Kitadai Y, Sumii M, Tazuma S, Yoshihara M, Haruma K and Chayama K: Cavernous hemangioma in the ascending colon treated by endoscopic mucosal resection. *J Gastroenterol Hepatol* **22** : 280–281 (2007)
- 2) van Deursen CT, Buijs J and Nap M: An uncommon polyp in the colon: a pedunculated cavernous hemangioma. *Endoscopy* **40** : E127 (2008)
- 3) Ueda K, Nakase H, Yaku H, Honzawa Y and Chiba T: Pedunculated cavernous hemangioma mimicking inflammatory fibroid polyp in a patient with ulcerative colitis. *Endoscopy* **42** : E162 (2010)
- 4) Leite S, Veloso R, Pinho R, Silva AP, Pinto J, Afonso M, Carvalho J and Fraga J: Cavernous hemangiomas limited to the sigmoid colon. *Gastrointest Endosc* **72** : 1064–1065 (2010)
- 5) Ackerman LV: Cavernous hemangiomata of small and large bowel. *Am J Cancer* **30** : 753–757 (1937)
- 6) Imperial R and Helwig EB: Angiokeratoma. A clinicopathological study. *Arch Dermatol* **95** : 166–175 (1967)

[Received June 1, 2012 : Accepted July 31, 2012]