

Original

Clinicopathological Study of Serrated Polyps of the Colorectum, with Special Reference to Maspin Expression

Yasuo OCHIAI^{1,2)}, Nobuyuki OHIKE¹⁾, Kunio ASONUMA^{1,2)},
Genki TSUKUDA¹⁾, Yusuke WADA¹⁾, Koudai HIRABAYASHI¹⁾,
Yojiro KAWAMURA¹⁾, Masayuki ISOZAKI¹⁾ and Toshio MOROHOSHI¹⁾

Abstract : Aims : We compared the clinicopathologic features of three types of colorectal serrated polyps, namely, hyperplastic polyps (HPs), sessile serrated adenomas/polyps (SSA/Ps), and traditional serrated adenomas (TSAs), and analyzed the expression pattern of maspin in these serrated lesions. We retrospectively examined 173 polypoid lesions that were endoscopically excised from 136 patients and diagnosed as hyperplastic or adenomatous serrated lesions, and histologically classified as HPs, SSA/Ps, or TSAs. Maspin expression was immunohistochemically examined in all lesions. Overall, 59 lesions (34%) were classified as HPs, 70 (40%) as SSA/Ps and 44 (25%) as TSAs. There were no significant differences in mean age or gender of patients between types, but SSA/Ps frequently developed on the right colon and showed a superficial/flat elevation, whereas HPs and TSAs frequently developed on the left colon and showed protruded lesions. The average diameters of HPs, SSA/Ps, and TSAs were 7.2, 9.9, and 12.9 mm, respectively, showing significant differences. Diffuse cytoplasmic expression of maspin was observed in the serrated glands of all three types. In addition, focal or diffuse intranuclear localization of maspin was observed in 15% of HPs, 13% of SSA/Ps, and 84% of TSAs, showing significant differences between TSAs and the other two types. The three types of serrated polyp examined in this study showed distinct clinicopathological features. The presence of maspin expression in these polyps, regardless of whether they were hyperplastic or neoplastic, indicates that maspin might be commonly associated with cell proliferation, although the underlying mechanism might be different between types.

Key words : clinicopathological study, colorectum, maspin, serrated polyp

Introduction

Research on precancerous lesions of the colorectum has been intensively conducted, along with studies to improve endoscopic techniques and diagnostics for colorectal mucosal lesions.

¹⁾ Department of Pathology, Showa University School of Medicine, 1-5-8 Hatanodai, Shinagawa-ku, Tokyo 142-8555, Japan.

²⁾ Department of Medicine, Division of Gastroenterology, Showa University Fujigaoka Hospital.

Recently, a pathway through which cancer develops from colorectal serrated polyps has attracted attention in addition to the conventional theory, namely, the adenoma-carcinoma sequence¹⁻³⁾. Previously, colorectal serrated polyps were classified into hyperplastic polyps (HPs) and traditional serrated adenomas (TSAs), but, in 2003, Goldstein *et al*⁴⁾ and Torlakovic *et al*⁵⁾ showed that some lesions previously diagnosed as HPs were adenomatous and proposed another type, the sessile serrated adenomas/polyp (SSA/P). Currently, there are two pathways considered in the pathogenesis of colorectal cancer, on the basis of a combination of the above three serrated polyps: a traditional serrated pathway, in which HPs develop into cancer through TSAs, and a sessile serrated pathway, in which HPs develop into cancer through SSA/Ps^{6,7)}.

However, a number of pathologists are still unsure about the diagnosis of SSA/Ps. The main reason is the difficulty in distinguishing SSA/Ps from HPs histologically (Fig. 1). Although SSA/Ps rarely show cellular atypia similar to HPs, they have structural atypias such as curved, meandering, branched (inverted T-shape, L-shape), and dilated glands, mainly at the lower part of the gland, and are thereby distinguishable from HPs. Moreover, proliferative zones are located at the bottom of the gland for HPs, whereas they extend from the bottom to the surface of the gland for SSA/Ps. These differential findings, however, are not always clear in daily routine clinical specimens. Currently, histological diagnostic standards developed by Higuchi *et al*^{8,9)}, on the basis of the reports by Torlakovic *et al*⁵⁾, are generally used to diagnose SSA/Ps in Japan.

Maspin is a unique member of the serpin family of protease inhibitors with tumor suppressive potential in several cancers^{10,11)}. The maspin gene was originally identified in normal mammary epithelial cells by subtractive hybridization on the basis of its mRNA expression. It has tumor suppressive activity attributable to inhibition of cancer cell motility,

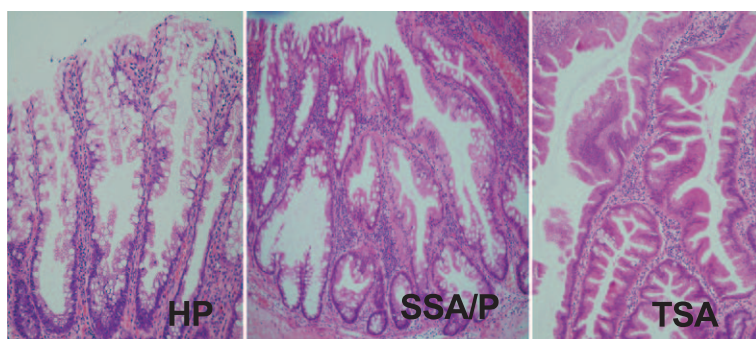


Fig. 1. Histological features of three types of serrated polyp. Hyperplastic polyp (HP) is characterized by elongation of the crypts with mild serration. Sessile serrated adenoma/polyp (SSA/P) shows a dilated and distorted (multibranched) appearance to the crypts. Traditional serrated adenoma (TSA) consists of villous or serrated glands of tall-columnar epithelium with eosinophilic cytoplasm and pseudostratified nuclei.

invasion and metastasis. The regulatory mechanism of its expression in various cancer cells appears to involve DNA methylation and histone deacetylation which commonly play a suppressive role in maspin gene activation^{10,11}. Recently, it has been demonstrated that down-regulation of maspin expression correlates with progression and metastatic status in several cancers^{10,11}. We have also studied the expression pattern of maspin in the esophagus, stomach, colorectum, pancreas, and lung¹¹⁻¹⁷, where a high rate of maspin expression is commonly observed during cancer formation from precancerous lesions, and maspin expression tends to be suppressed when invasion and metastasis of cancer cells occurs. Similar results in the colorectum have been previously reported by several authors^{18,19}. However, to the best of our knowledge, there have been no reports focusing on maspin expression in colorectal serrated polyps.

The purpose of this study was to compare the clinicopathological features of three colorectal serrated polyps, HPs, SSA/Ps, and TSAs, in patients treated in our hospital, and analyze the expression pattern of maspin and its significance in these polyps.

Materials and Methods

We studied 173 lesions that were endoscopically excised from 136 patients treated at Showa University Hospital between April 2008 and May 2010 which were diagnosed as hyperplastic or adenomatous serrated polyps. These serrated polyps were classified into three histological types, i.e., HPs, SSA/Ps, and TSAs, on the basis of the World Health Organization (WHO) classification²⁰, and the classification developed by Higuchi *et al*^{8,9} (Fig. 1). In particular, HPs and SSA/Ps were distinguished on the basis of the seven items of Higuchi's classification, as follows: (1) distinct serrated structure at the bottom of crypts and villous or papillary structure on the mucosal surface; (2) multibranched or horizontally arrayed crypts; (3) dilatation of crypts; (4) increase in epithelium-to-interstitium ratio of at least 50%; (5) nuclear division at the upper part of crypts; (6) atypical cells at the upper part of crypts (enlarged nucleus with distinct nucleolus and balloon-like chromatin); and (7) increase in production of mucus (within cells or lumen). Serrated polyps for which four or more of the seven items were observed were classified as SSA/Ps, and those for which three or less of the seven items were observed were classified as HPs. These diagnoses were agreed upon by multiple observers (YO, NO, TM).

Clinicopathologically, five items were investigated: age and gender of the patient, and the site, size, and macroscopic shape of the lesion. The site was classified as the right or left colon. The right colon included the cecum, ascending colon, and transverse colon, whereas the left colon included the descending colon, sigmoid colon, and rectum. The size of the lesion was determined by the maximum diameter of the tumor in tissue samples. The shape of the lesion was classified as one of two types, based on the Japanese Classification of Colorectal Carcinoma²¹: superficial elevated type (type IIa) or protruded type (types Ip, Isp, and Is).

Table 1. Clinicopathological features of three types of serrated polyp

	Serrated polyps			<i>p</i> -value		
	HP (n = 59)	SSA/P (n = 70)	TSA (n = 44)	HP vs SSA/P	SSA/P vs TSA	HP vs TSA
Mean age (years)	60.2 (32-81)	62.4 (36-84)	61.5 (29-85)	NS	NS	NS
Gender (male : female)	50 : 9	52 : 18	29 : 15	NS	NS	NS
Site (right colon : left colon)	20 : 39	56 : 14	12 : 32	< 0.01	< 0.01	NS
Mean size (mm)	7.2 (2.5-20)	9.9 (3-24)	12.9 (4-40)	< 0.01	< 0.05	< 0.01
Shape (protruded : superficial elevated)	48 : 11	29 : 41	39 : 5	< 0.01	< 0.01	NS

HP, hyperplastic polyp ; SSA/P, sessile serrated adenoma/polyp ; TSA, traditional serrated adenoma
NS, not significant

Immunohistochemical staining was performed using an avidin-biotin complex detection system (BenchMark XT/LT automated slide stainer ; Ventana Medical Systems, Inc., Tucson, AZ). Thin sections of 3 μ m were cut from the formalin-fixed paraffin-embedded blocks used for the histological analysis. These slices were stained with anti-maspin monoclonal antibody (EAW24, Novocastra, Newcastle upon Tyne, UK ; dilution, 1 : 50) and subsequently observed under an optical microscope. The positive control samples were myoepithelial cells of the mammary ducts.

Statistical analyses were performed using the chi-square test and *t* test. Differences with *P*-values < 0.05 were considered to be statistically significant.

Results

Clinicopathological features

Among the 173 lesions, 59 (34%) were classified as HPs, 70 (40%) as SSA/Ps, and 44 (25%) as TSAs (Table 1). HPs and SSA/Ps showed no cellular atypia, whereas TSAs all showed mild or moderate cellular atypia. The mean ages of the patients were in the range of 60~69 years for the three types, showing no significant differences. There was also no significant gender difference. On the other hand, the site of SSA/Ps was significantly different from those of HPs and TSAs ; SSA/Ps were frequently developed in the right colon, whereas HPs and TSAs were frequently developed in the left colon. The average diameters of HPs, SSA/Ps, and TSAs were 7.2, 9.9, and 12.9 mm, respectively, which were significantly different. Macroscopically, many SSA/Ps were superficially/flatly elevated, whereas the majority of HPs and TSAs were protruded, showing significant differences (Table 1).

Immunohistochemical features

Diffuse cytoplasmic expression of maspin was observed throughout the glands of all

Table 2. Immunohistochemical results of maspin expression in the serrated polyps

		Serrated polyps			<i>p</i> -value		
		HP (n = 59)	SSA/P (n = 70)	TSA (n = 44)	HP vs SSA/P	SSA/P vs TSA	HP vs TSA
Maspin	Cytoplasmic	59 (100%)	70 (100%)	44 (100%)	NS	NS	NS
	Nuclear	9 (15%)	9 (13%)	37 (84%)	NS	< 0.01	< 0.01

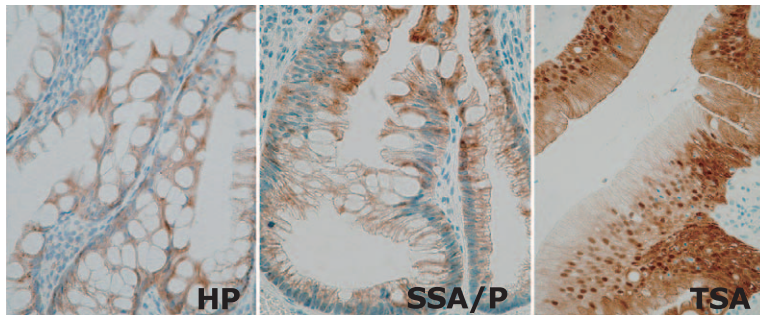


Fig. 2. Immunohistochemical features of three types of serrated polyp. Diffuse cytoplasmic expression of maspin is observed in all three types. In addition, intranuclear localization of maspin is prominent in the traditional serrated adenoma (TSA). HP, hyperplastic polyp; SSA/P, sessile serrated adenoma/polyp.

three types of polyps. In addition, focal or diffuse intranuclear localization of maspin was observed in nine HPs (15%), nine SSA/Ps (13%), and 37 TSAs (84%), showing significant differences between TSAs and the other two types of polyps (Table 2, Fig. 2). Maspin expression was absent or weak in the intact normal epithelium of the background mucosa of all samples.

Discussion

The specimens of this study were lesions excised by endoscopy. This means that the lesions included those excised by different endoscopists on the basis of their own decision. Therefore, the clinicopathological features obtained in this study do not necessarily indicate the true characteristics of colorectal serrated polyps. In particular, many small HPs, which account for the majority of colorectal serrated polyps, would have been excluded from the excisions. This exclusion may have easily affected the data for the frequency, size, and macroscopic shape of lesions. Moreover, the predominance of males seen in all polyp types in this study may also be affected by differences in the frequency of males and females who undergo endoscopic examination. Nevertheless, the clinicopathological features of each

polyp obtained in this study were in agreement with those reported previously²⁰⁾. Namely, HPs frequently develop in the left colon and are relatively small, SSA/Ps frequently develop in the right colon, are relatively large (10 mm diameter on average), and are mostly superficially/flatly elevated, while TSAs frequently develop in the left colon and are larger and mostly protrude. These clinicopathological features seem to be very useful for the diagnosis of serrated polyps.

This is the first paper to investigate and discuss the expression of maspin in colorectal serrated polyps. In previous studies we have demonstrated maspin expression at a high rate in several metaplastic, dysplastic, and precancerous lesions, such as esophageal dysplasia, gastric intestinal metaplasia and adenoma, pancreatic intraepithelial neoplasia, intraductal papillary-mucinous adenoma, and colorectal adenoma¹¹⁻¹⁶⁾. Zheng *et al*¹⁸⁾ and Boltze¹⁹⁾ have also reported a high rate of maspin expression in specimens of colorectal adenomas. Maspin expression is hardly observed in intact normal epithelium, and therefore is considered to be associated with the proliferative changes of colorectal polyps regardless of whether the lesions are hyperplastic or adenomatous, ordinary or serrated.

Maspin acts as a tumor suppressor when overexpressed in aggressive cancer cell lines and is thought to inhibit carcinoma invasion, metastasis and angiogenesis and induce apoptosis¹⁰⁾, but its role in human cancer is controversial because in some studies maspin expression has been associated with a poor prognosis, whereas in others it is associated with a favorable outcome²²⁾. Some investigators found that intranuclear localization of maspin is associated with improved survival and emphasized that the tumor suppressor activity of maspin might require nuclear localization²²⁻²⁵⁾. In addition, Bettstetter and colleagues²⁶⁾ found that elevated nuclear maspin expression was closely correlated with high microsatellite instability. In this study of precancerous serrated lesions, the focal or diffuse intranuclear localization of maspin was exclusively observed in TSAs. Its significance and effect were unclear and we failed to find a relationship between nuclear maspin expression and microsatellite instability in our specimens (data not shown). These findings, however, indicate that nuclear maspin expression might be a key feature in the differential diagnosis of serrated polyps; in addition it is important to consider the two serrated pathways (traditional and sessile) in the pathogenesis of colorectal cancer.

In conclusions, the three types of serrated polyp examined in this study showed distinct clinicopathological features. Maspin expression was frequently observed in all types of polyps and was considered to be associated with cell proliferation, although the underlying mechanism might be different between different types of polyps.

References

- 1) Kambara T, Simms LA, Whitehall VL, Spring KJ, Wynter CV, Walsh MD, Barker MA, Arnold S, McGivern A, Matsubara N, Tanaka N, Higuchi T, Young J, Jass JR and Leggett BA: BRAF mutation is associated with DNA methylation in serrated polyps and cancers of the colorectum. *Gut* **53**: 1137-1144 (2004)

- 2) Jass JR: Serrated adenoma of the colorectum and the DNA-methylator phenotype. *Nat Clin Pract Oncol* **2**: 398-405 (2005)
- 3) O'Brien MJ: Hyperplastic and serrated polyps of the colorectum. *Gastroenterol Clin North Am* **36**: 947-968, viii (2007)
- 4) Goldstein NS, Bhanot P, Odish E and Hunter S: Hyperplastic-like colon polyps that preceded microsatellite-unstable adenocarcinomas. *Am J Clin Pathol* **119**: 778-796 (2003)
- 5) Torlakovic E, Skovlund E, Snover DC, Torlakovic G and Nesland JM: Morphologic reappraisal of serrated colorectal polyps. *Am J Surg Pathol* **27**: 65-81 (2003)
- 6) Jass JR, Whitehall VL, Young J and Leggett BA: Emerging concepts in colorectal neoplasia. *Gastroenterology* **123**: 862-876 (2002)
- 7) Snover DC: Update on the serrated pathway to colorectal carcinoma. *Hum Pathol* **42**: 1-10 (2011)
- 8) Higuchi T and Jass JR: My approach to serrated polyps of the colorectum. *J Clin Pathol* **57**: 682-686 (2004)
- 9) Higuchi T, Sugihara K and Jass JR: Demographic and pathological characteristics of serrated polyps of colorectum. *Histopathology* **47**: 32-40 (2005)
- 10) Maass N, Biallek M, Rosel F, Schem C, Ohike N, Zhang M, Jonat W and Nagasaki K: Hypermethylation and histone deacetylation lead to silencing of the maspin gene in human breast cancer. *Biochem Biophys Res Commun* **297**: 125-128 (2002)
- 11) Ohike N, Nagoshi K, Ishino A, Matsukawa K, Date Y, Iwaku K, Ishino H, Iri M and Morohoshi T: Relationship between maspin tumor suppressor gene expression and progression of esophageal, gastric, and colonic cancer. *Showa Univ J Med Sci* **17**: 137-144 (2005)
- 12) Kato H, Ohike N, Kojima M, Yamazaki T, Kato K and Morohoshi T: Expression of maspin, a cancer suppressor gene, in patients with early colon cancer. *Showa Univ J Med Sci* **19**: 19-25 (2007)
- 13) Ushio J, Ohike N, Kojima M, Nagasaki K, Matsukawa M and Morohoshi T: Expression of the tumor suppressor gene maspin in early gastric carcinoma and its significance: significant correlation with vascular invasion. *Showa Univ J Med Sci* **18**: 13-18 (2006)
- 14) Ishino A, Ohike N, Nagasaki K, Kitayama T, Katou K and Morohoshi T: Tumor suppressor gene maspin induces apoptosis in stomach and colon cancer. *Showa Univ J Med Sci* **19**: 189-194 (2007)
- 15) Kashima K, Ohike N, Mukai S, Sato M, Takahashi M and Morohoshi T: Expression of the tumor suppressor gene maspin and its significance in intraductal papillary mucinous neoplasms of the pancreas. *Hepatobiliary Pancreat Dis Int* **7**: 86-90 (2008)
- 16) Ohike N, Maass N, Mundhenke C, Biallek M, Zhang M, Jonat W, Luttges J, Morohoshi T, Kloppel G and Nagasaki K: Clinicopathological significance and molecular regulation of maspin expression in ductal adenocarcinoma of the pancreas. *Cancer Lett* **199**: 193-200 (2003)
- 17) Nakashima M, Ohike N, Nagasaki K, Adachi M and Morohoshi T: Prognostic significance of the maspin tumor suppressor gene in pulmonary adenocarcinoma. *J Cancer Res Clin Oncol* **130**: 475-479 (2004)
- 18) Zheng H, Tsuneyama K, Cheng C, Takahashi H, Cui Z, Murai Y, Nomoto K and Takano Y: Maspin expression was involved in colorectal adenoma-adenocarcinoma sequence and liver metastasis of tumors. *Anticancer Res* **27**: 259-265 (2007)
- 19) Boltze C: Loss of maspin is a helpful prognosticator in colorectal cancer: a tissue microarray analysis. *Pathol Res Pract* **200**: 783-790 (2005)
- 20) Snover DC, Ahnen DJ, Burt RW and Odze RD: Serrated polyps of the colon and rectum and serrated polyposis. In: *WHO Classification of Tumours of the Digestive System*, 4th ed., Bosman FT, Carneiro F, Hruban RH and Theise ND (Eds), International Agency for Research on Cancer, Lyon, pp 160-165 (2010)
- 21) Japanese Society for Cancer of the Colon and Rectum: *Japanese Classification of Colorectal Carcinoma*, 2nd English ed., Kanehara Shuppan, Tokyo (2009)
- 22) Goulet B, Kennette W, Ablack A, Postenka CO, Hague MN, Mymryk JS, Tuck AB, Giquere V, Chambers AF and Lewis JD: Nuclear localization of maspin is essential for its inhibition of tumor growth and metastasis. *Lab Invest* **91**: 1181-1187 (2011)

- 23) Mohsin SK, Zhang M, Clark GM and Craig Allred D: Maspin expression in invasive breast cancer: association with other prognostic factors. *J Pathol* **199** : 432-435 (2003)
- 24) Sood AK, Fletcher MS, Gruman LM, Coffin JE, Jabbavi S, Khalkhali-Ellis Z, Arbour N, Seftor EA and Hendrix MJ: The paradoxical expression of maspin in ovarian carcinoma. *Clin Cancer Res* **8** : 2924-2932 (2002)
- 25) Marioni G, Staffieri A and Blandamura S: Maspin expression in head and neck carcinoma: subcellular localization matters. *J Oral Pathol Med* **39** : 279-280 (2010)
- 26) Bettstetter M, Woenckhaus M, Wild PJ, Rummele P, Blaszyk H, Hartmann A, Hofstadter F and Dietmaier W: Elevated nuclear maspin expression is associated with microsatellite instability and high tumour grade in colorectal cancer. *J Pathol* **205** : 606-614 (2005)

[Received September 6, 2012 : Accepted September 28, 2012]