

Case Report

A Case of Laparoscopic Ileocecal Resection for Intussusception Secondary to Cecal Cancer

Takahiro UMEMOTO¹⁾, Yoshikuni HARADA¹⁾, Makiko SAKATA¹⁾,
Youhei KITAMURA¹⁾, Hiroki MIZUKAMI¹⁾, Mitsuo SAITO¹⁾,
Gaku KIGAWA¹⁾, Hiroshi NEMOTO¹⁾, Masatsugu NAGAHAMA²⁾,
Hiroshi TAKAHASHI²⁾ and Junichi TANAKA¹⁾

Abstract: An 83-year-old woman presented with a right lower abdominal mass, lower abdominal pain, and distension. She had no medical or surgical history. Clinical examination revealed a right lower abdominal mass, abdominal distension, and decreased bowel sounds in the lower abdomen. Abdominal computed tomography showed an intussusception involving the ileocecal junction. A Gastrografin enema showed a tumor shadow with an irregular defect caused by the intussusception in the transverse colon. The protruding tumor was also pushed back into the cecum by the enema pressure. Colonoscopy revealed a protruding mass at the leading edge of the intussusception in the ascending colon, and biopsy results of the cecal mass indicated an adenocarcinoma. The patient underwent laparoscopic ileocecal resection of the intussuscepted cecal cancer using reduced port surgery. The resected specimen contained a type 1 tumor measuring 40 mm that was histopathologically diagnosed as cecal cancer. The patient remains asymptomatic 8 months after surgery.

Key words: cecal cancer, intussusception, reduced port surgery (RPS)

Introduction

Intussusception is uncommon in adults, accounting for 5% of all intussusceptions and 1% of all bowel obstructions^{1, 2)}. Moreover, colonic intussusception is less common than small intestinal intussusception, and is generally associated with malignancy¹⁾. Intussusception can go undetected for long periods because of its varied presenting symptoms and time course. In fact, intussusception is frequently only diagnosed during laparotomy performed to investigate obstructive symptoms^{2, 3)}. We preoperatively diagnosed intussusception secondary to cecal adenocarcinoma while performing laparoscopic ileocecal resection by reduced port surgery (RPS).

Case Report

An 83-year-old woman presented to the emergency department with a right lower abdominal mass, lower abdominal pain, and distension associated with nausea and vomiting that she had

¹⁾ Department of Gastroenterological and General Surgery, Showa University Fujigaoka Hospital, 1-30 Fujigaoka, Aoba-ku, Yokohama-shi, 227-8501, Japan.

²⁾ Department of Medicine, Division of Gastroenterology, Showa University Fujigaoka Hospital.

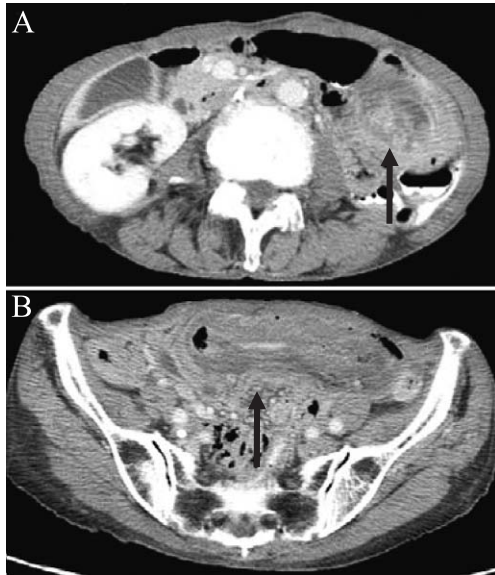


Fig. 1. Abdominal enhanced computed tomography
Abdominal enhanced CT showing an intussusception with the target sign (A, arrow) being an edematous intestine (B, arrow).

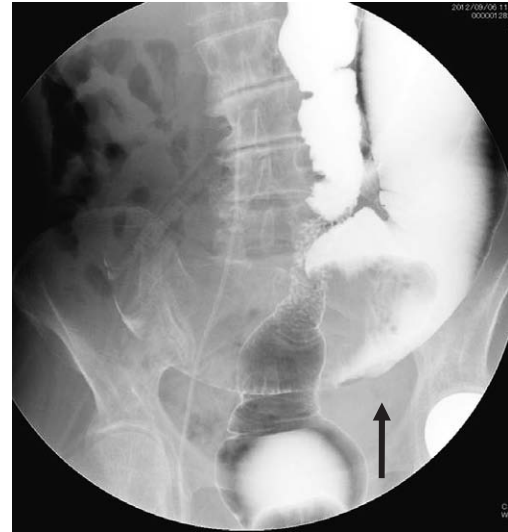

Fig. 2. Gastrografin enema
Gastrografin enema showing a tumor shadow with irregular defect caused by the intussusception in the transverse colon (arrow).

experienced for several days. On arrival, the patient had a body temperature of 36.5°C, blood pressure of 128/80 mmHg, pulse of 70 beats/min, and respiratory rate of 16 breaths/min. She had no history of surgery or major disease. Physical examination revealed a distended and mildly painful abdomen with a palpable mass and tenderness in the right upper quadrant. Results of laboratory testing revealed slightly increased inflammatory markers including a white blood cell count of 8,700/mm³ and a C-reactive protein level of 0.82 mg/dL. The remaining blood test parameters were unremarkable. Abdominal enhanced computed tomography (CT) revealed intussusception signaled by an edematous intestine (Fig. 1). A gastrografin enema showed a tumor shadow with an irregular defect caused by the intussusception in the transverse colon (Fig. 2), and the protruding tumor was pushed back into the cecum by the enema pressure. Subsequent colonoscopy revealed a protruding mass at the leading edge of the intussusception in the ascending colon (Fig. 3), and biopsy results identified this cecal mass as an adenocarcinoma. The patient's serum carcinoembryonic antigen (CEA) tumor marker level was 179 ng/mL (normal range < 5.0 ng/mL) (Table 1).

The patient was placed in the supine position, and a Lap protector (LP) mini was put into the peritoneal space through a 30-mm transumbilical incision. An EZ-access was mounted to the LP, and then three 5-mm ports were placed using the EZ-access. Finally, a 5-mm assist port was inserted into the right lower quadrant. Subsequent RPS with D3 lymph node dissection (Fig. 4) revealed an ileocecal intussusception (terminal ileum, cecum, and ascending colon) that was easily reduced to reveal a tumor in the cecum, measuring approximately 4 cm in diameter. The intussusception was thus resolved, and no ascites, swollen lymph nodes, or

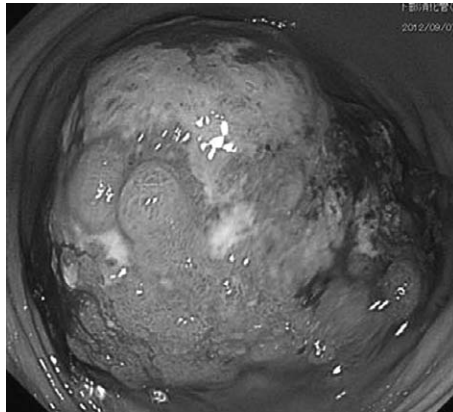


Fig. 3. Colonoscopy
Colonoscopy showing a protruding mass at the leading edge of the intussusception in the ascending colon.

Table 1. Levels of carcinoembryonic antigen (CEA) as a tumor marker

	Before surgery	1 month after surgery	8 months after surgery
CEA (ng/ml)	17.9	4.4	2.8

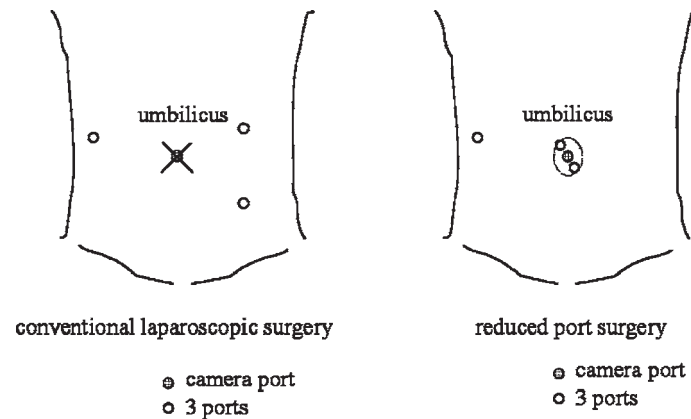


Fig. 4. Port location
For the reduced port surgery a lap protector mini was inserted through a 30-mm transumbilical incision. An EZ-access was mounted to the LP and three 5-mm ports were positioned using the EZ-access. A 5-mm port was also inserted in the right lower quadrant.

peritoneal disseminations were noted. We then performed ileocecal resection with excision of the tumor, retaining margins of 10 cm on the anal side of the tumor, and an ileocolic end-to-end double layer anastomosis. The operative procedure took 170 min with a total blood loss of 25 mL. The resected specimen revealed a round, granular-surfaced tumor measuring 40 mm




Fig. 5. Resected specimen

The resected specimen showed a round, granular tumor measuring 40 mm and protruding into the lumen.

which protruded into the lumen (Fig. 5). The lesion was histologically diagnosed as mucinous adenocarcinoma that was invading the serosa without permeating the lymphatic or venous capillaries. No lymph node metastases were noted, and the patient was followed up without adjuvant chemotherapy. The postoperative course was uneventful with no disease recurrence for 8 months after surgery and serum CEA levels were within normal range at 1 month and 8 months after surgery (Table 1).

Discussion

Malignancy causes intussusception in the colon more frequently than in the small bowel, and ileocecal intussusception can occur from a lead point in the colon, ileum, or appendix. The causative malignancy could be lipoma, polyp, lymphoma, adenocarcinoma of the ileum or cecum, or even a Meckel's diverticulum^{4, 5}). Ultrasonography has been used to evaluate suspected intussusception, with the classic features including the target and doughnut signs; however, ultrasound examination has the possible disadvantage of masking by gas-filled loops of bowel⁶). In the case reported herein, we performed a gastrografenema after CT indicated an intussusception with colonic obstruction. This approach is useful for diagnosing ileocecal intussusception, and in this case, we located a cecal tumor shadow with an irregular defect. Colonoscopy subsequently revealed a protruding mass in the ascending colon that was easily reduced to reveal a mucinous adenocarcinoma. Such preoperative diagnosis is often difficult or delayed because of the nonspecific nature and varying duration of intussusception symptoms, and thus, treatment usually involves formal resection of the involved bowel segment⁷⁻⁹).

Some studies have reported resection of the intussusception without reduction as the preferred treatment in adults because of the high risk of primary cancer^{1, 10, 11}). The downside of reduction prior to resection includes the theoretical risk of intraluminal tumor seeding, reduction

of an externally viable bowel despite mucosal necrosis, venous embolization of malignant cells, spillage of succus through an inadvertent perforation, and anastomotic complications in cases of edematous and weakened bowels^{10, 12)}. In the present case, the patient underwent laparoscopic ileocecal resection by RPS and showed no complications or recurrence during 8 months follow up after surgery. The use of laparoscopic surgery for benign bowel tumors and ileocecal intussusception has recently increased¹³⁻¹⁷⁾. Namikawa *et al*¹²⁾ reported that cases of short-duration adult intussusception, even at colonic sites, could be effectively treated by preoperative reduction followed by minimally invasive surgery using laparoscopy, avoiding extensive and invasive resection. In the present case, RPS was considered more appropriate because the patient showed no intestinal dilatation and the umbilicus hides the scar of surgical incision. Clinically, these cosmetic benefits and reduced postoperative pain are potentially major advantages of RPS because the incisions are few and small. In addition, RPS could reduce the risks of tissue trauma and port-related complications such as organ damage, adhesions, bleeding, wound infection, and hernia, while in cases for which the ileocecal intussusception is not easily reduced, it could be reduced by hand instead through the 30-mm transumbilical incision. We therefore believe that RPS is preferable to conventional laparoscopic surgery as the optimal treatment approach for ileocecal intussusception.

Conflict of interest

The authors have declared no conflict of interest.

References

- 1) Zubaidi A, Al-Saif F, Silverman R. Adult intussusception: a retrospective review. *Dis Colon Rectum*. 2006; **49**:1546-1551.
- 2) Stewardson RH, Bombeck CT, Nyhus LM. Critical operative management of small bowel obstruction. *Ann Surg*. 1978; **187**:189-193.
- 3) d'Silva KJ, Dwivedi AJ, Shetty A, *et al*. An unusual presentation of colon cancer in a young individual. *Dig Dis Sci*. 2005; **50**:1033-1035.
- 4) Tamburrini S, Stilo A, Bertucci B, *et al*. Adult colocolic intussusception: demonstration by conventional MR techniques. *Abdom Imaging*. 2004; **29**:42-44.
- 5) Choi SH, Han JK, Kim SH, *et al*. Intussusception in adults: from stomach to rectum. *AJR Am J Roentgenol*. 2004; **183**:691-698.
- 6) Fujii Y, Taniguchi N, Itoh K. Intussusception induced by villous tumor of the colon: sonographic findings. *J Clin Ultrasound*. 2002; **30**:48-51.
- 7) Marinis A, Yiallourou A, Samanides L, *et al*. Intussusception of the bowel in adults: a review. *World J Gastroenterol*. 2009; **15**:407-411.
- 8) Barussaud M, Regenet N, Briennon X, *et al*. Clinical spectrum and surgical approach of adult intussusceptions: a multicentric study. *Int J Colorectal Dis*. 2006; **21**:834-839.
- 9) Erkan N, Hacıyanlı M, Yildirim M, *et al*. Intussusception in adults: an unusual and challenging condition for surgeons. *Int J Colorectal Dis*. 2005; **20**:452-456.
- 10) Yamada H, Morita T, Fujita M, *et al*. Adult intussusception due to enteric neoplasms. *Dig Dis Sci*. 2007; **52**:764-766.

- 11) Eisen LK, Cunningham JD, Aufses AH Jr. Intussusception in adults: institutional review. *J Am Coll Surg.* 1999; **188**:390-395.
- 12) Namikawa T, Okamoto K, Okabayashi T, *et al.* Adult intussusception with cecal adenocarcinoma: successful treatment by laparoscopy-assisted surgery following preoperative reduction. *World J Gastrointest Surg.* 2012;**4**:131-134.
- 13) Umemoto T, Shinmura K, Saito M, *et al.* A case of single-incision laparoscopic surgery for lipoma of the terminal ileum. *Showa Univ J Med Sci.* 2012;**24**:231-235.
- 14) Fumimoto Y, Nishida T, Hasegawa J, *et al.* A case of adult intussusception due to ileal lipoma diagnosed preoperatively and treated by laparoscopic assisted surgery. *J Jpn Soc Endosc Surg.* 2005;**10**:416-419. (in Japanese).
- 15) Chiu CC, Wei PL, Huang MT, *et al.* Laparoscopic treatment of ileocecal intussusception caused by primary ileal lymphoma. *Surg Laparosc Endosc Percutan Tech.* 2004;**14**:93-95.
- 16) Alonso V, Targarona EM, Bendahan GE, *et al.* Laparoscopic treatment for intussusception of the small intestine in the adult. *Surg Laparosc Endosc Percutan Tech.* 2003;**13**:394-396.
- 17) Tsushimi T, Matsui N, Kurazumi H, *et al.* Laparoscopic resection of an ileal lipoma: report of a case. *Surg Today.* 2006;**36**:1007-1011.

[Received May 21, 2013 : Accepted August 2, 2013]