

Case Report

Transurethral Resection is an Efficacious Surgical Option for Patients with Prostatic Abscesses that Fail Transrectal Ultrasound-guided Drainage : A Case Report

Kazuhiko OSHINOMI*, Yu OGAWA, Takehiko NAKASATO,
Jun MORITA, Atsushi IGARASHI, Takayuki ASO,
Masashi MORITA, Michio NAOE, Kohzo FUJI,
Takashi FUKAGAI and Yoshio OGAWA

Abstract : A 60-year-old man with diabetes mellitus (DM) had a continuous fever and complained of pollakisuria and general fatigue during his hospitalization to establish glycemic control. He was diagnosed with a prostatic abscess by computed tomography and immediately transferred to our hospital. Transrectal, ultrasound-guided, needle aspiration of the prostatic abscess was performed as the initial surgical treatment, but the fluid could not be completely evacuated due to its high viscosity. Aspiration was not sufficient to improve his symptoms, therefore, antibiotics were administered intravenously along with strict control of his DM. Transurethral resection of the prostate (TURP) was carried out to resolve the abscess cavities while the patient awaited improvement of his general condition and inflammatory findings. After TURP, the patient's lower urinary tract symptoms improved, and the abscess in the prostate did not recur.

Key words : prostatic abscess, transrectal ultrasound (TRUS), transurethral resection of the prostate (TURP)

Introduction

A prostatic abscess is a rare condition. Although its symptoms overlap with those of acute prostatitis, prostatic abscess must be suspected when symptoms do not resolve after intravenous antibiotic therapy. In this situation, transrectal ultrasound (TRUS) is useful in making the distinction. In cases of prostatic abscess, TRUS-guided drainage is a good treatment option which is easy to perform and has few complications. However, it is difficult to achieve adequate drainage of the cavity with highly viscous contents, as in the present case. A case of prostatic abscess with unsuccessful TRUS-guided drainage and the effectiveness of transurethral drainage are reported.

Case Report

A 60-year-old man with diabetes mellitus (DM) suffered from continuous high fever,

Department of Urology, Showa University School of Medicine, 1-5-8 Hatanodai, Shinagawa-ku, Tokyo 142-8666, Japan.

* To whom corresponding should be addressed.

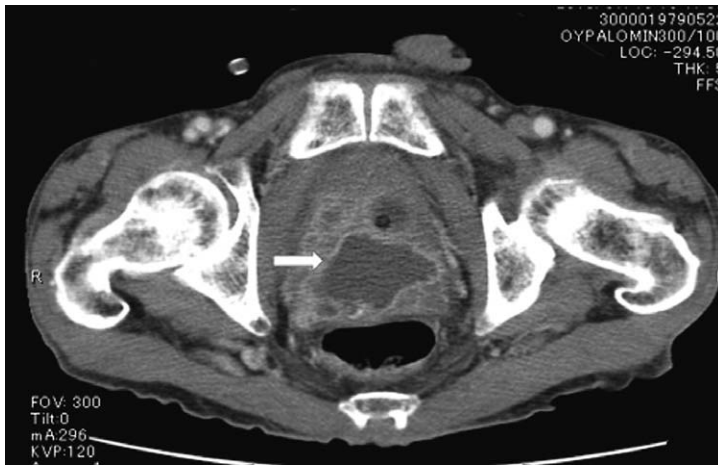

Fig. 1. CT (arrow : abscess cavity)

CT showed prostate abscess with septum. The length of the major axis of the abscess cavity was about 6 cm.

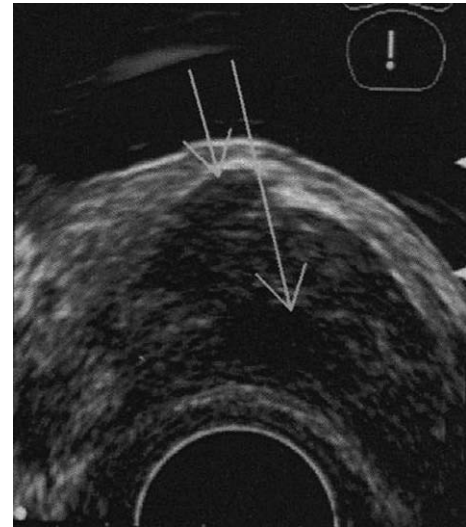

Fig. 2. TRUS (arrow : abscess cavity)

Transrectal ultrasonography showed heterogeneous hypoechoic area in the prostate. (This area is the abscess cavity.)

pollakisuria, dysuria and general fatigue during hospitalization for the purpose of glycemic control (HbA1c 12.3%) in another hospital. He was diagnosed with a prostatic abscess by computed tomography (CT), and needle puncture was performed. However, the contents could not be completely drained because of their high viscosity. Therefore, he was transferred and admitted to our hospital. On physical examination at admission, there were no abnormal findings except for low-grade fever and mild prostatic enlargement. White blood cell (WBC) and CRP levels were elevated (WBC 21200/ μ l, CRP 6.49 mg/dl), and urinalysis showed pyuria (WBC >100/HPF). *Candida albicans* was detected on urine culture. CT showed an irregularly-shaped, heterogeneous, low attenuation area with a septum in the prostate gland. The length of the major axis of the abscess was approximately 6 cm (Fig. 1). Both transrectal and transabdominal ultrasonographic images showed a heterogeneous hypoechoic area in the prostate (Fig. 2). These findings were consistent with prostatic abscess. Transrectal, ultrasound-guided, needle aspiration (21 G) of the prostatic abscess was then performed. Though the fluid could not be completely evacuated because of its high viscosity, the causative organism could be identified as *Streptococcus agalactiae*. Since the patient's subjective and objective symptoms were not improved by needle aspiration alone, antibiotics were administered intravenously along with strict control of his DM (Fig. 3). Transurethral resection of the prostate (TURP) was carried out to resolve the abscess cavities (Fig. 4) while the patient awaited improvement of his general condition and inflammatory findings. The purpose of this procedure was to allow complete drainage of the prostatic abscess, to improve the urination disorder, and to prevent recurrence of infection. After the TURP, the lower urinary tract symptoms improved. The pathological findings showed no malignancy in the prostate tissue. Two months after the TURP, CT showed no residual abscess cavity (Fig. 5).

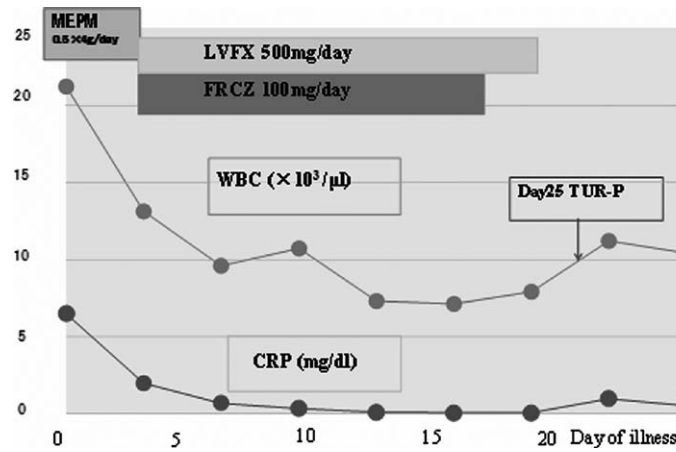


Fig. 3. White blood cell (WBC) and CRP levels were improved by administration of antibiotics and then TURP was carried out.

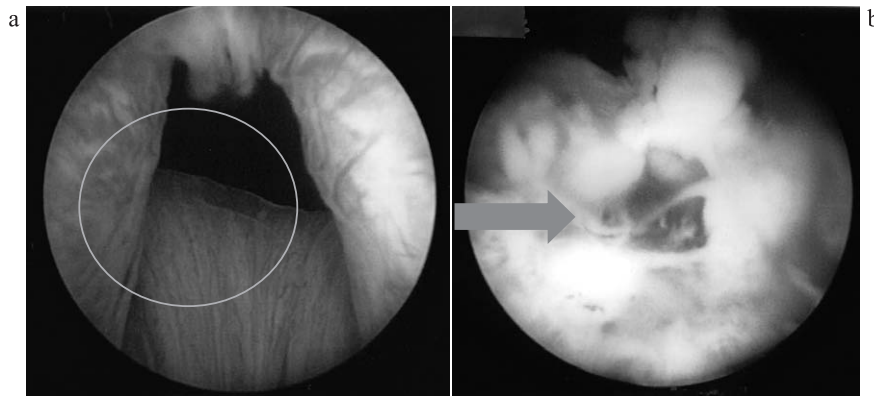


Fig. 4. Operative findings
 a : Before The main area of abscess cavity. (circle : abscess cavity)
 b : After Pus discharge and abscess cavity.

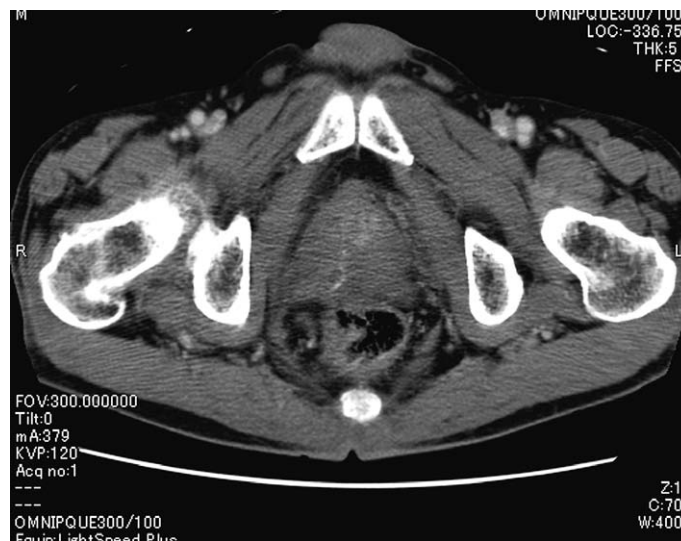

Fig. 5. At two months after transurethral drainage CT showed no recurrence of abscess in the prostate.

	Advantage	Disadvantage
Transrectal	<ul style="list-style-type: none"> • simple procedure • less pain 	<ul style="list-style-type: none"> • incomplete drainage • rectal bleeding • exacerbation of infection
Transperineal (percutaneous)	<ul style="list-style-type: none"> • drainage by large gauge needle 	<ul style="list-style-type: none"> • painful • sexual dysfunction with nerve damage
Transurethral	<ul style="list-style-type: none"> • adequate drainage 	<ul style="list-style-type: none"> • invasive procedure • sexual dysfunction • urethral injury • incontinence • exacerbation of infection

Fig. 6. Comparison of approach for drainage

Discussion

A prostatic abscess is a rare condition, accounting for 0.5% of all prostatic diseases¹⁾. The major pathogens involved are Gram-negative bacilli, which are isolated in 60% to 80% of cases¹⁻⁵⁾. Major risk factors for prostatic abscess are reported to be lower urinary tract obstruction, urethral manipulation (iatrogenic factor), DM, liver disease, and immunodeficiency states. Two pathologic mechanisms, reflux of infected urine and hematogenous dissemination from a primary infected focus, are thought to cause prostatic abscess⁶⁾. The most common causative microorganism is *S. aureus*. However, the frequency of other pathogenic microorganisms is not known. Clinical diagnosis is difficult because the symptoms are nonspecific. This condition presents with micturition pain, perineal pain, fever, and dysuria, but these symptoms overlap with those of acute prostatitis. We should suspect a prostatic abscess and evaluate with appropriate diagnostic imaging when symptoms do not improve after 48 hours of intravenous antibiotic therapy⁶⁾. In this case, the prostate was examined using TRUS and CT, and an accurate diagnosis was obtained. We believe that immediate imaging evaluation is important as these findings allow not only accurate diagnosis but timely and appropriate treatment. According to previous reports, appropriate antibiotics and drainage are optimal therapeutic options for prostatic abscess. For patients who fail to respond to intravenous antibiotic therapy, drainage should be performed immediately. There are three ways to drain such an abscess: transrectal, transperineal, and transurethral (Fig. 6). Each approach has its advantages and disadvantages. TRUS-guided drainage is easy to perform and has few complications and is commonly used in urological examination. Generally, anesthesia is not necessary in TRUS, however, it is difficult to achieve adequate drainage of the cavity when the contents are highly viscous, as a thin gauge needle is used. El-Shazly *et al*⁷⁾ reported that transurethral drainage achieved the highest success rates without major complications compared

to the other two drainage methods. Additional surgical manipulations were unnecessary in most cases treated with transurethral drainage. However, Collado *et al* noted that TRUS-guided drainage should be performed prior to transurethral drainage, because transurethral procedures have a potential risk of sexual dysfunction or severe complications⁶⁾. Furthermore, Vyas *et al* noted that patients with abscesses of larger than 2 cm who suffered from severe lower urinary tract symptoms and / or leukocytosis benefitted from TRUS-guided drainage. They also suggested that transurethral drainage is an efficacious treatment procedure for patients of failed TRUS aspiration⁸⁾. TURP is most commonly used for treating urination disorders caused by benign prostatic hyperplasia. In this case, because the size of the abscess cavity was large and urinary symptoms did not improve after TRUS-guided drainage, we chose to perform transurethral drainage. It is important to assess the size and shape of the abscess using TRUS, CT, and MRI when determining the drainage approach.

References

- 1) Granados EA, Riley G, Salvador J, *et al*. Prostatic abscess: diagnosis and treatment. *J Urol*. 1992;**148**:80-82.
- 2) Jacobsen JD, Kvist E. Prostatic abscess. A review of literature and a presentation of 5 cases. *Scand J Urol Nephrol*. 1993;**27**:281-284.
- 3) Trauzzi SJ, Kay CJ, Kaufman DG, *et al*. Management of prostatic abscess in patients with human immunodeficiency syndrome. *Urology*. 1994;**43**:629-633.
- 4) Bachor R, Gottfried HW, Hautmann R. Minimal invasive therapy of prostatic abscess by transrectal ultrasound-guided perineal drainage. *Eur Urol*. 1995;**28**:320-324.
- 5) Angwafo FF 3rd, Sosso AM, Muna WF, *et al*. Prostatic abscesses in sub-Saharan Africa: a hospital-based experience from Cameroon. *Eur Urol*. 1996;**30**:28-33.
- 6) Collado A, Palou J, Garcia-Penit J, *et al*. Ultrasound-guided needle aspiration in prostatic abscess. *Urology*. 1999;**53**:548-552.
- 7) El-Shazly M, El-Enzy N, El-Enzy K, *et al*. Transurethral drainage of prostatic abscess: points of technique. *Nephrourol Mon*. 2012;**4**:458-461.
- 8) Vyas JB, Ganpule SA, Ganpule AP, *et al*. Transrectal ultrasound-guided aspiration in the management of prostatic abscess: A single-center experience. *Indian J Radiol Imaging*. 2013;**23**:253-257.

[Received March 25, 2014 : Accepted May 2, 2014]