

## Case Report

# A Case of Pneumatosis Cystoides Intestinalis Mimicking Intestinal Perforation

Takahiro UMEMOTO<sup>\*1)</sup>, Yoshikuni HARADA<sup>1)</sup>, Makiko SAKATA<sup>1)</sup>,  
Gaku KIGAWA<sup>1)</sup>, Masatsugu NAGAHAMA<sup>2)</sup>, Hiroshi TAKAHASHI<sup>2)</sup>  
and Junichi TANAKA<sup>1)</sup>

**Abstract:** An 85-year-old man was referred to the Department of Gastroenterological and General Surgery after complaining of abdominal pain and distention. Abdominal computed tomography (CT) revealed intra-abdominal free air, mimicking perforated peritonitis, with air collection within the jejunum bowel wall. On the basis of these findings, we made a diagnosis of pneumatosis cystoides intestinalis (PCI) with intra-abdominal free air. The PCI signs had disappeared completely by Day 7 of hospitalization. The patient was discharged from hospital after 15 days. At the time of writing, the patient's PCI has not reappeared. This case highlights the clinical importance of PCI, and that the lung window settings of abdominal CT are useful tools to enable an accurate diagnosis of PCI.

**Key words:** pneumatosis cystoides intestinalis (PCI), pneumoperitoneum, intestinal perforation

## Introduction

Pneumatosis cystoides intestinalis (PCI) is an uncommon but clinically important condition characterized by the presence of multiple gas-filled cysts containing nitrogen, hydrogen, and carbon dioxide in the subserosal or submucosal wall of the large intestine, small intestine, or both<sup>1)</sup>. Patients are either asymptomatic or they present with gastrointestinal symptoms, including nausea, vomiting, diarrhea, and abdominal pain. Herein, we present a case of PCI associated with pneumoperitoneum mimicking intestinal perforation without inflammation, infection, or ascites.

## Case Report

An 85-year-old man received treatment for cerebral infarction in the Department of Internal Medicine. After complaining of abdominal pain and distention, the patient was referred to the Department of Gastroenterological and General Surgery. The patient did not have a history of heavy alcohol intake or smoking, and no notable family history. At 76 years of age, he had become mildly paralyzed on the right side of his body following a cerebral infarction. In

<sup>1)</sup> Department of Gastroenterological and General Surgery, Showa University Fujigaoka Hospital, 1-30 Fujigaoka, Aoba-ku, Yokohama-shi, 227-8501, Japan.

<sup>2)</sup> Department of Medicine, Division of Gastroenterology, Showa University Fujigaoka Hospital.

\* To whom corresponding should be addressed.

Table 1. Complete blood count and results of blood biochemistry tests

The results of the complete blood count and biochemical tests did not indicate any findings of marked inflammatory reactions.

WBC	6,010 / $\mu$ l	CK	79 mg/dl
RBC	434 10,000/ $\mu$ l	UN	18 mg/dl
Hb	13.7 g/dl	Cr	0.5 mg/dl
Ht	41.2 %	UA	3 mg/dl
PLT	25 10,000/ $\mu$ l	CRP	0.06 mg/dl
TP	7.1 g/dl	Na	136 mEq/l
Alb	4.2 g/dl	K	4.1 mEq/l
T-Bil	0.44 mg/dl	Cl	104 mEq/l
AST	29 IU/l	FBS	108 mg/dl
ALT	18 IU/l	PT-INR	0.9
$\gamma$ GTP	19 IU/l	APTT	28.3 sec
LDH	279 IU/l	D dimer	6.3 $\mu$ g/ml

WBC, white blood cell count; RBC, red blood cell count; Hb, hemoglobin; Ht, hematocrit; PLT, platelet; TP, total protein; Alb, albumin; T-Bil, total bilirubin; AST, aspartate aminotransferase; ALT, alanine aminotransferase;  $\gamma$  GTP,  $\gamma$ -glutamyl transpeptidase; LDH, lactate dehydrogenase; CK, creatine phosphokinase; BUN, blood urea nitrogen; Cr, creatinine; CRP, C-reactive protein; Na, sodium; K, potassium; Cl, chloride; FBS, fasting blood sugar; PT-INR, prothrombin time international normalized ratio; APTT, activated partial thromboplastin time.

addition, he routinely used magnesium oxide and purgatives for chronic constipation.

Upon admission, the patient had abdominal bloating. Only mild tenderness was noted on palpation of his abdomen, with no muscular guarding or rebound tenderness. Physical examination upon admission revealed the following: blood pressure, 130/74 mmHg; body temperature, 36.4°C; pulse rate, 70 beats/min; respiratory rate, 14 breaths/min. There was no indication of a marked inflammatory reaction based on the results of a complete blood count and blood biochemistry tests (Table 1). Abdominal radiography revealed intra-abdominal free air (Fig. 1A), distension of the intestine, and an extra-intestinal gas image, suggesting pneumoperitoneum (Fig. 1B). Although the soft tissue settings of the abdominal computed tomography (CT) did not reveal the cause of the intra-abdominal free air, the lung window settings of the CT revealed intra-abdominal free air (Fig. 2A) and a gas image in the intestinal

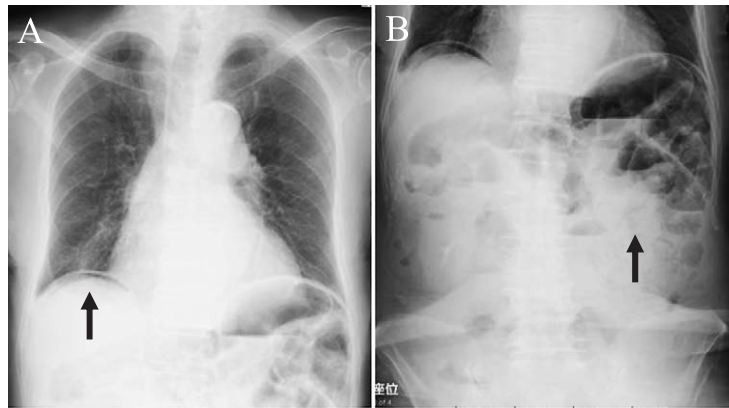

Fig. 1. Abdominal radiography on the day of admission  
Abdominal radiography performed on the day of admission revealed intra-abdominal free air (A; arrow), distension of the intestine, and extra-intestinal gas (B; arrow), suggesting pneumoperitoneum.

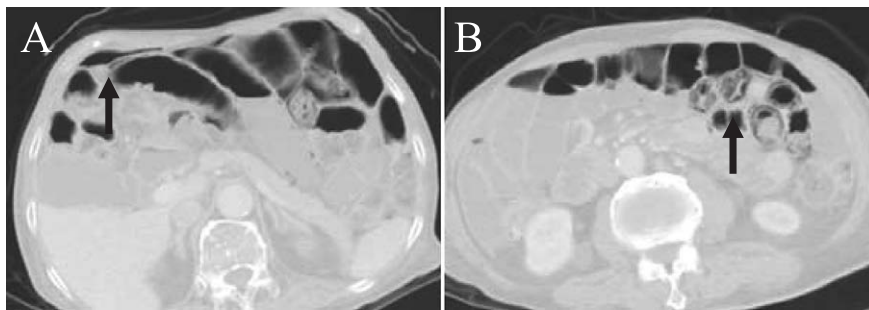


Fig. 2. Abdominal CT performed on the day of admission  
Abdominal CT performed on the day of admission revealed intra-abdominal free air (A; arrow) and a gas image in the intestinal tract wall (B; arrow).

tract wall (Fig. 2B). Intra-abdominal free air indicated the presence of a damaged area. Gas-producing bacteria, such as *Clostridium*, may pass through the intestinal tract wall. On the basis of these findings (i.e. no inflammatory reaction and a gas image in the intestinal tract wall on CT), the patient was diagnosed with PCI accompanied by pneumoperitoneum. Many perforation types with inflammatory reactions were considered as differential diagnoses, including perforations of gastrointestinal ulcerations, gastrointestinal tumors, and intestinal diverticula. Conservative treatment, comprising intestinal rest, fasting, and intravenous feeding, was chosen because of minor increases in the inflammatory reaction and mild abdominal pain. The patient was hospitalized immediately, monitored, and transfused, and instructed to fast. The patient's general status remained stable, and his abdominal bloating became less severe, along with the passage of flatus, on the day after hospitalization. On Day 7 of hospitalization, additional abdominal radiography (Fig. 3) and abdominal CT (Fig. 4) were performed and showed decreased gas. Improvement of the PCI was confirmed, so we allowed the patient to drink water. Because the

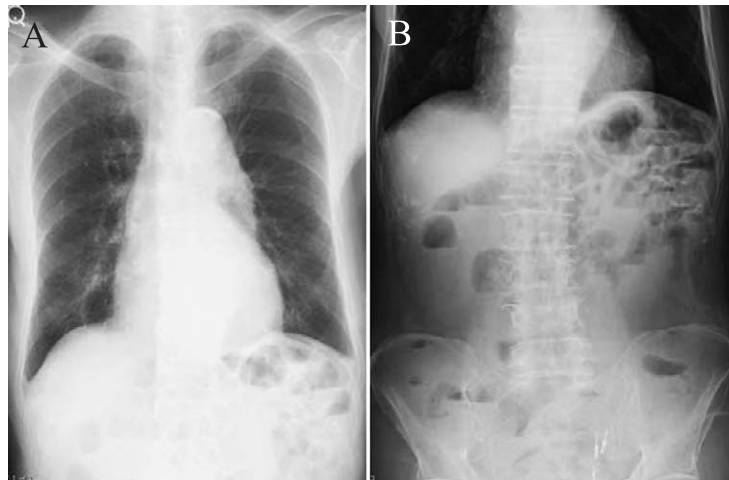


Fig. 3. Abdominal radiography on Day 7 of hospitalization  
Abdominal radiography conducted on Day 7 of hospitalization revealed decreased gas (A, B).

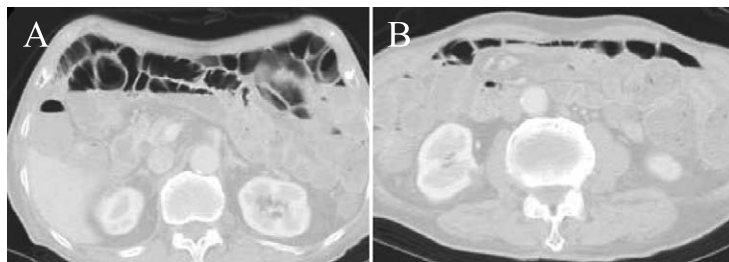


Fig. 4. Abdominal CT on Day 7 of hospitalization  
Abdominal CT performed on Day 7 of hospitalization showed decreased gas (A, B).

patient's symptoms were stable following water intake, dietary intake was started on Day 8 of hospitalization. No exacerbation of the patient's abdominal symptoms was observed thereafter, and he was discharged on Day 15 of hospitalization. At the time of writing, the patient's PCI had not reappeared.

## Discussion

PCI affects men more commonly than women, with a peak incidence at 30~50 years of age<sup>2)</sup>. The incidence of PCI is unknown, because it is usually asymptomatic. Symptoms, if any, are usually secondary to an underlying disease. Non-specific symptoms include abdominal discomfort, diarrhea, constipation, rectal bleeding, tenesmus, or loss of weight; severe complications, including volvulus, intestinal obstruction, tension pneumoperitoneum, bleeding, intussusception, and intestinal perforation, may be seen in 3% of PCI patients<sup>3,4)</sup>. The appropriate treatment for a patient with PCI should be based on evaluations of both the underlying cause and examination results.

PCI associated with massive intraperitoneal free air is extremely uncommon, and is difficult to diagnose differentially from perforated peritonitis. In the present case, abdominal radiography clearly showed intra-abdominal free air under the right side diaphragm. Similarly, CT showed intra-abdominal free air, which enabled intestinal emphysema to be determined as the cause. The rupture of subserosal cysts with PCI resulted in the pneumoperitoneum. Therefore, we were able to make a diagnosis of intestinal emphysema in the small intestine and the patient was able to avoid surgery because he did not have any findings of peritonitis. Conservative approaches, including nasogastric decompression, intestinal rest, antibiotic therapy, and oxygen, are recommended for patients who are radiologically confirmed to have no intestinal ischemia or perforation and who have positive examination findings and normal biochemical parameters<sup>5)</sup>. Conservative management is preferable; however, emergency surgery may be necessary if a patient does not respond to conservative treatment<sup>6)</sup>.

In the present case, abdominal CT was a very important radiologic tool that enabled the accurate diagnosis of PCI. In particular, the lung window settings of CT have been reported to be important in the detection of intramural air, obviating the need for intraluminal contrast to outline the circumferential pattern of PCI<sup>7)</sup>. Given the possible problems associated with surgery, we suggest that the correct imaging is important in the elderly population.

#### References

- 1) Read NW, Al-Janabi MN, Cann PA. Is raised breath hydrogen related to the pathogenesis of pneumatosis coli? *Gut*. 1984;**25**:839-845.
- 2) Sakurai Y, Hikichi M, Isogaki J, *et al*. Pneumatosis cystoides intestinalis associated with massive free air mimicking perforated diffuse peritonitis. *World J Gastroenterol*. 2008;**14**:6753-6756.
- 3) Hwang J, Reddy VS, Sharp KW. Pneumatosis cystoides intestinalis with free intraperitoneal air: a case report. *Am Surg*. 2003;**69**:346-349.
- 4) Ryback LD, Shapiro RS, Carano K, *et al*. Massive pneumatosis intestinalis: CT diagnosis. *Comput Med Imaging Graph*. 1999;**23**:165-168.
- 5) Mizoguchi F, Nanki T, Miyasaka N. Pneumatosis cystoides intestinalis following lupus enteritis and peritonitis. *Intern Med*. 2008;**47**:1267-1271.
- 6) Umemoto T, Shinmura K, Yokomizo K, *et al*. A case of pneumatosis cystoides intestinalis with free air mimicking perforated diffuse peritonitis. *J Jpn Coll Surg*. 2012;**37**:336-339.
- 7) Connor R, Jones B, Fishman EK, *et al*. Pneumatosis intestinalis: role of computed tomography in diagnosis and management. *J Comput Assist Tomogr*. 1984;**8**:269-275.

[Received July 31, 2013 : Accepted February 4, 2014]