

Case Report

A Case of Androgen Receptor-positive Triple Negative Breast Cancer with Good Response to Anti-androgen Therapy

Megumi NAKAJIMA^{1,2)}, Sadako AKASHI-TANAKA^{*1,3)}, Yuko HIROTA⁴⁾,
Murasaki IKEDA¹⁾, Yoko KANADA¹⁾, Rikako HASHIMOTO¹⁾,
Hirotō OYAMA¹⁾, Reiko YOSHIDA¹⁾, Takashi KUWAYAMA¹⁾,
Katsutoshi ENOKIDO^{1,3)}, Terumasa SAWADA¹⁾ and Seigo NAKAMURA¹⁾

Abstract: Anti-androgen therapy has been proposed to be effective in the treatment of androgen receptor (AR)-positive triple negative breast cancer (TNBC). Herein, we report on the case of a 91-year-old female patient with AR-positive TNBC who underwent anti-androgen therapy and had a good response. Because of dementia, the patient lives in an aged care facility. It was here that a staff member noticed a mass with a rash on the patient's breast. Consequently, the patient was sent for further examination. Ultrasonography revealed an irregularly shaped, indistinct hypoechoic mass measuring 19×18×9 mm located in the upper outer quadrant of the left breast. Core needle biopsy (CNB) was performed and the mass was diagnosed as apocrine carcinoma. Further immunohistochemical analysis showed that the mass was AR-positive TNBC. Anti-androgen therapy was determined to be the optimal treatment option for this patient. The Institutional Review Board approval the off-label use of an anti-androgen for the treatment of this patient, who was subsequently treated with the anti-androgen flutamide. After 8 months, the size of the tumor had reduced to 15×9×5 mm.

Key words: triple negative breast cancer, androgen receptor, anti-androgen therapy, hormone therapy

Introduction

Triple negative breast cancer (TNBC) is a breast cancer subtype defined by a lack of expression of both estrogen (ER) and progesterone (PR) receptors, as well as a lack of overexpression of human epidermal growth factor receptor 2 (HER2). This subtype of breast cancer is associated with aggressive behavior and poor prognosis. To date, only chemotherapy has been found to be effective for in the treatment of TNBC and no therapeutic targets have yet been established.

Recently, gene expression profiling identified six distinct molecular subtypes of TNBC: two

¹⁾ Division of Breast Surgical Oncology, Department of Surgery, Showa University School of Medicine, 1-5-8 Hatanodai, Shinagawa-ku, Tokyo 142-8666, Japan.

²⁾ Department of Surgery, Hokuto Hospital.

³⁾ Department of Breast Surgical Oncology, Showa University Koto Toyosu Hospital.

⁴⁾ Department of Pathology, Showa University School of Medicine.

* To whom corresponding should be addressed.

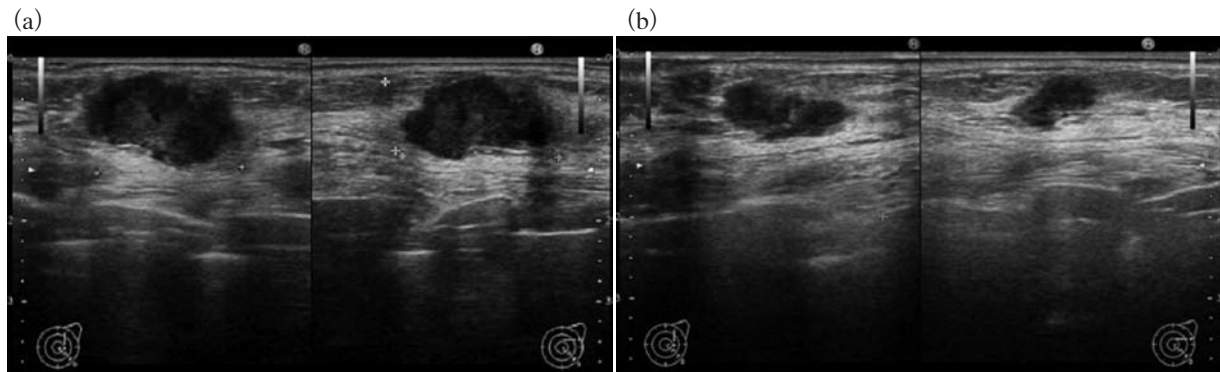


Fig. 1. (a) Ultrasonography before the patient started flutamide revealed an irregularly shaped, hypoechoic mass with an indistinct margin measuring $19 \times 18 \times 9$ mm located at the upper outer quadrant of the left breast. (b) After 8 months treatment with flutamide, the size of the tumor had reduced to $15 \times 9 \times 5$ mm.

basal types (BL1 and BL2), two mesenchymal-like subgroups (M and MSL), an immunomodulatory group (IM), and a luminal androgen group (LAR). The prevalence of LAR tumors is 11% (62/587) of TNBCs or 2% (62/3247) of all breast cancers. Importantly, the LAR subtype is characterized by androgen receptor (AR) signaling and it has been shown to be sensitive to bicalutamide, an AR antagonist, both in vitro and in xenograft models¹. Therefore, therapies targeting the AR may be effective against tumors that express this hormone receptor.

Herein we report on the case of a patient with AR-positive triple negative apocrine carcinoma who underwent anti-androgen therapy and had a good response.

Case report

A 91-year-old female patient, who suffers from dementia and lives in an aged care facility, visited Showa University Hospital in March 2012 because a staff member at the aged care facility had noticed a mass with a rash on the patient's left breast 3 weeks earlier.

Physical examination revealed an elastic, hard, protuberant tumor with an irregular surface just beneath the skin. Neither axillary nor supraclavicular lymph nodes were palpable. Ultrasonography revealed an irregularly shaped, hypoechoic mass with an indistinct margin measuring $19 \times 18 \times 9$ mm located at the upper outer quadrant of the left breast (Fig. 1a). Mammography and magnetic resonance imaging were not performed because the patient could not keep still. Indeed, for the core needle biopsy (CNB), the patient's family and a nurse were required to help hold her down. Diagnosis of the biopsy revealed that the tumor was apocrine carcinoma, as indicated by cancer cells with large, round nuclei and plump, eosinophilic, granular, and sharp-bordered cytoplasm (Fig. 2a). The nuclear grade was determined to be 1. Immunohistochemical staining of the biopsy specimen revealed that the cancer was negative for ER, PR, and HER2, and the Ki67 index was 10%–20%. It was decided that surgery under general anesthesia and hospital care would worsen the patient's general status and that surgery under local anesthesia would be impossible based on the difficulties encountered when performing the CNB. Moreover, because the patient's cancer was both ER- and PR-negative, hormone therapy was

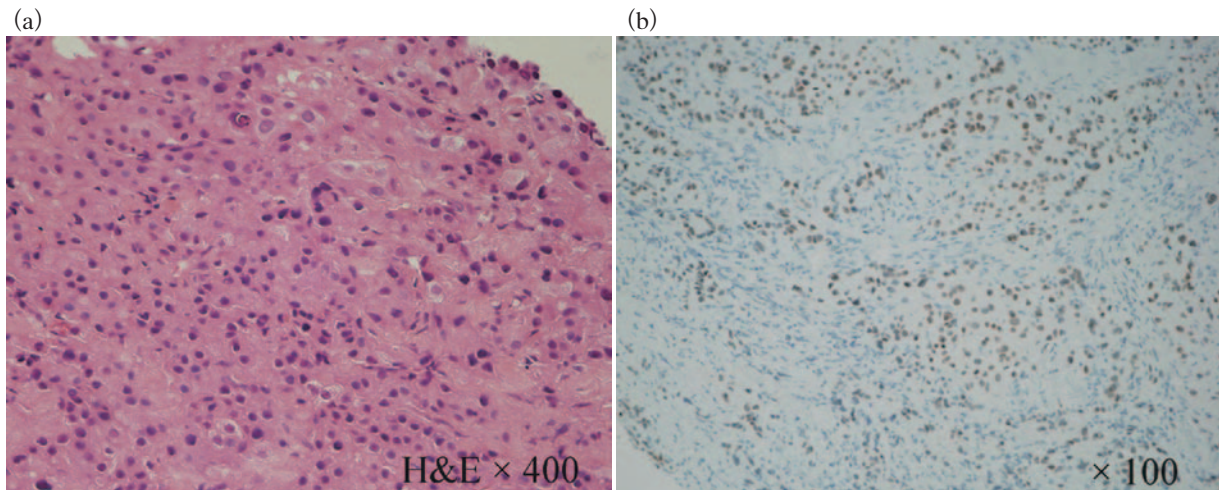


Fig. 2. (a) Diagnosis of the biopsy revealed that it was apocrine carcinoma, as indicated by cancer cells with large, round nuclei and plump, eosinophilic, granular, and sharp-bordered cytoplasm (hematoxylin and eosin [H&E]; original magnification $\times 400$).
 (b) The tumor was androgen receptor positive, as determined by immunohistochemistry using the clone AR27 antibody (Novocastra; original magnification $\times 100$).

not an option despite her general condition. We thought that anti-androgen therapy may be an effective alternative treatment that would be less damaging than chemotherapy if the tumor was AR positive. Indeed, we reasoned that anti-androgen therapy could control cancer progression without significantly affecting the patient's quality of life. Consequently, we determined the AR status of the tumor using the clone AR27 antibody (Novocastra) and the results were positive (Fig. 2b). Approval was then obtained from the Institutional Review Board to commence off-label anti-androgen therapy for the patient, which was also explained in detail to her family. The patient's family provided written informed consent and the patient was prescribed a daily dose of 250 mg flutamide, an anti-androgen. After 1 month, the size of the tumor had reduced to $19\times 12\times 7$ mm, and the tumor continued to shrink over a period of 8 months to $15\times 9\times 5$ mm (Fig. 1b). No obvious adverse events were observed, including changes to blood components as determined by blood testing. After 1 year, an abnormal vaginal discharge was noted, but further gynecological examinations could not be performed because of the patient's dementia, and it was unclear whether this discharge was caused by the flutamide treatment. At the time of writing, 1 year and 10 months after starting on flutamide therapy, the patient remains alive.

Discussion

The LAR subgroup of TNBC has been reported to be driven by AR signaling. In addition, these tumors have been shown to be sensitive to the effects of anti-androgens *in vitro* and in xenograft models¹. Therefore, it has been proposed that anti-androgen therapy may be effective for the treatment of AR-positive TNBC, which is frequently seen in apocrine carcinoma². Consequently, clinical trials are underway using anti-androgen therapy³.

The AR is a nuclear receptor that binds testosterone and dihydrotestosterone in the cyto-

Table 1. Comparison of major studies investigating the clinical features of androgen receptor-positive triple-negative breast cancer

Study	Year	No. patients	No. AR+	Positivity	LN metastasis	Grade	DFS, OS	Other observations
Tsutsumi <i>et al.</i> ²⁾	2012	51	21 (41 %)	≥ 1 %		Lower ^A		Ki-67 labeling was higher in AR-negative TNBC
Luo <i>et al.</i> ⁷⁾	2010	137	38 (28 %)	H score	Negative	Lower ^A	Longer ^A	AR positivity was associated with postmenopausal status
He <i>et al.</i> ⁸⁾	2012	287	74 (26 %)	≥ 5 %	Negative		Longer ^A	
Rakha <i>et al.</i> ⁹⁾	2007	282	36 (13 %)	> 0 %		Lower ^A		In node-positive patients, AR negativity was associated with the development of recurrence and distant metastasis
McGhan <i>et al.</i> ¹⁰⁾	2013	94	22 (23 %)	≥ 10 %	Positive			AR positivity was associated with an older patient age and a higher TNM stage
Hu <i>et al.</i> ¹¹⁾	2011	211	78 (37 %)	≥ 1 %			Shorter ^A	

^ACompared with androgen receptor-positive triple-negative breast cancer.

Positivity : The judging criteria of the immunostaining as androgen receptor-positive.

AR, androgen receptor; LN, lymph node; DFS, disease-free survival; OS, overall survival; TNBC, triple negative breast cancer; TNM, tumor-node-metastasis.

plasm, then translocates to the nucleus, where it regulates gene transcription. The AR has been reported to be expressed in 70%–80% of breast cancers and in 10%–43% of TNBCs^{2,4-11)}.

The role of AR expression in TNBC is unclear. Many studies have documented that AR expression in TNBC is associated with favorable prognostic factors, including lack of lymph node metastasis^{7,8)}, low histological grade^{2,7,9)}, long disease-free and overall survival^{7,8)}, and low rates of recurrence and distant metastasis⁹⁾ (Table 1). Tsutsumi reported that the mean Ki-67 labeling index, an indicator of proliferation, was higher in AR-negative than AR-positive TNBC (58% vs 37%, respectively; $P < 0.01$)²⁾. Together, these results suggest that AR-positive TNBC is associated with a less aggressive phenotype.

In contrast with these observations, some reports suggest that AR positivity is associated with negative features in TNBC. McGhan *et al.*¹⁰⁾ observed that there was a tendency for more advanced disease in AR-positive than AR-negative TNBC patients, as indicated by a greater proportion of patients with Stage II and III tumors (73% vs 44%), angiolymphatic invasion (27% vs 19%), lymph node metastases (45% vs 14%), and a larger mean tumor size (2.9 vs 2.2 cm) in the former group. In that study, Stage I and II patients had similar recurrence-free and overall survival rates regardless of AR status¹⁰⁾. In contrast, patients with Stage III AR-positive TNBC had a worse prognosis than AR-negative TNBC patients, although this trend was not statistically significant. This may imply a degree of chemotherapy resistance in the AR-positive subgroup¹⁰⁾. Hu *et al.*¹¹⁾ observed that overall mortality was 83% higher in women with AR-positive TNBC

than in women with AR-negative TNBC (multivariate hazard ratio 1.83; 95% confidence interval [CI] 1.11–3.01; $P = 0.02$).

There are many possible reasons for the apparent discrepancies between studies regarding the relationship between AR expression and the clinicopathological features of TNBC, including variations in the definition of AR positivity and the approaches used for its detection (e.g. type of antibody clone, antibody concentration, and antigen-retrieval methods).

Several drugs have been developed that target AR signaling. Bicalutamide is a widely available, orally active, non-steroidal anti-androgen that competitively inhibits the actions of androgens by binding to cytosolic ARs in target tissues. One published Phase II trial has explored the efficacy of bicalutamide in AR-positive, ER-negative, PR-negative metastatic breast cancer patients³). In that trial, patients were eligible to receive bicalutamide at a dose of 150 mg daily if either the primary or a metastatic site was AR positive. The 6-month clinical benefit rate was found to be 19% (95% CI 7%–39%). The median progression-free survival was found to be 12 weeks (95% CI 11–22 weeks). The most common, possibly drug-related, toxicities of any grade were fatigue (21%), hot flashes (21%), limb edema (21%), and elevations in aspartate aminotransferase (25%) and alkaline aminotransferase (21%). Grade 1 toxicities were reported by more than 10% of patients. There were a few Grade 2 or 3 toxicities, but no Grade 4 or 5 toxicities. Recently, a case report has been published on the complete response of metastatic AR-positive breast cancer to bicalutamide after 4 months, which is ongoing 12 months after treatment started¹²). Bicalutamide caused only Grade 1 fatigue and Grade 1 hot flashes (CTCAE criteria v4.03 http://evs.nci.nih.gov/ftp1/CTCAE/CTCAE_4.03_2010-06-14_QuickReference_8.5x11.pdf).

Enzalutamide, another AR inhibitor, targets multiple steps in the AR signaling pathway in tumor cells. It achieves this through competitive inhibition of androgen binding to ARs, as well as blockade of both AR nuclear translocation and AR interaction with DNA. A Phase II trial aiming to validate the clinical activity and safety of enzalutamide is currently enrolling women with advanced AR-positive TNBC and will be terminated in 2016 (ClinicalTrials.gov Identifier NCT01889238).

Orteronel is an oral non-steroidal androgen synthesis inhibitor that selectively inhibits 17 β HSD lyase. This enzyme, which is present in both the testes and adrenal glands, is central to the production of steroidal androgens. A Phase II trial testing orteronel as monotherapy in patients with metastatic AR-positive breast cancer commenced in January 2014 (ClinicalTrials.gov Identifier NCT01990209).

In conclusion, the AR has been demonstrated to play a role in breast cancer. From a clinical perspective, AR expression may be associated with a favorable prognosis. However, more studies are needed to clarify the relationships between AR, breast cancer, and the efficacy of anti-androgen therapy. The present case report supports the efficacy of anti-androgen therapy for AR-positive TNBC. Further evaluation of AR expression will be important for the development of new treatment strategies for AR-positive TNBC.

Conflict of interest disclosure

The authors declare that they have no conflicts of interest.

References

- 1) Lehmann BD, Bauer JA, Chen X, *et al.* Identification of human triple-negative breast cancer subtypes and pre-clinical models for selection of targeted therapies. *J Clin Invest.* 2011;**121**:2750–2767.
- 2) Tsutsumi Y. Apocrine carcinoma as triple-negative breast cancer: novel definition of apocrine-type carcinoma as estrogen/progesterone receptor-negative and androgen receptor-positive invasive ductal carcinoma. *Jpn J Clin Oncol.* 2012;**42**:375–386.
- 3) Gucalp A, Tolane S, Isakoff SJ, *et al.* Phase II trial of bicalutamide in patients with androgen receptor-positive, estrogen receptor-negative metastatic breast cancer. *Clin Cancer Res.* 2013;**19**:5505–5512.
- 4) Park S, Koo J, Park HS, *et al.* Expression of androgen receptors in primary breast cancer. *Ann Oncol.* 2010;**21**:488–492.
- 5) Ogawa Y, Hai E, Matsumoto K, *et al.* Androgen receptor expression in breast cancer: relationship with clinicopathological factors and biomarkers. *Int J Clin Oncol.* 2008;**13**:431–435.
- 6) Niemeier LA, Dabbs DJ, Beriwal S, *et al.* Androgen receptor in breast cancer: expression in estrogen receptor-positive tumors and in estrogen receptor-negative tumors with apocrine differentiation. *Mod Pathol.* 2010;**23**:205–212.
- 7) Luo X, Shi YX, Li ZM, *et al.* Expression and clinical significance of androgen receptor in triple negative breast cancer. *Chin J Cancer.* 2010;**29**:585–590.
- 8) He J, Peng R, Yuan Z, *et al.* Prognostic value of androgen receptor expression in operable triple-negative breast cancer: a retrospective analysis based on a tissue microarray. *Med Oncol.* 2012;**29**:406–410.
- 9) Rakha EA, El-Sayed ME, Green AR, *et al.* Prognostic markers in triple-negative breast cancer. *Cancer.* 2007;**109**:25–32.
- 10) McGhan LJ, McCullough AE, Protheroe CA, *et al.* Androgen receptor-positive triple negative breast cancer: a unique breast cancer subtype. *Ann Surg Oncol.* 2014;**21**:361–367.
- 11) Hu R, Dawood S, Holmes MD, *et al.* Androgen receptor expression and breast cancer survival in postmenopausal women. *Clin Cancer Res.* 2011;**17**:1867–1874.
- 12) Arce-Salinas C, Riesco-Martinez MC, Hanna W, *et al.* Complete response of metastatic androgen receptor-positive breast cancer to bicalutamide: case report and review of literature. *J Clin Oncol* (Internet). 2014. (accessed 2014 June 2). Available from: <http://jco.ascopubs.org/cgi/doi/10.1200/JCO.2013.49.8899>

[Received February 19, 2015 : Accepted March 9, 2015]