

Original

Assessment of the Diagnostic Value and Image Quality of Dual-source Computed Tomography in Lumbar Vertebral Fractures : Comparison with Magnetic Resonance Imaging

Jumpei SUYAMA^{*1)}, Yoichi KATAYAMA¹⁾, Masumi TAKAHASHI²⁾,
Kazunari NOZIMA²⁾, Kenji HASHIGAYA²⁾, Hiroaki TSUJI²⁾,
Haruhiko KAWASAKI²⁾, Yoshikazu HOSHIKAWA²⁾, Rei KOBAYASHI³⁾,
Jiro MUNESHIKA³⁾, Takehiko GOKAN³⁾ and Kouji NIKAIDO⁴⁾

Abstract : The aim of this study was to assess the performance of virtual non-calcium images from dual-energy computed tomography (DECT), using dual-source CT (DSCT). Forty-one patients suspected of having traumatic vertebral fractures who underwent DSCT with virtual non-calcium imaging were included in this study. For comparison, radiation exposure was measured in 11 patients receiving DSCT with a radiation exposure reduction system, and in 14 patients receiving conventional multi-detector-row CT scans. Radiation exposure, detectability of fractures and visual image quality were assessed and compared between the groups. Radiation exposure was less with the non-calcium image than with the other methods. The CT number (x-ray absorption coefficient of a pixel in a CT) for the affected vertebrae was significantly higher than for normal vertebrae. When the threshold of the CT number was determined as -25.6 HU, the sensitivity was 100% and specificity was 92.6%. In most cases, the quality of the virtual non-calcium image was inferior to the fat-suppressed T2-weighted magnetic resonance images. The virtual non-calcium image technique obtained using DSCT can be a useful part of the clinical diagnosis of vertebral fractures.

Key words : vertebral fracture, dual-energy CT, dual-source CT, virtual non-calcium CT

Introduction

Magnetic resonance imaging (MRI) has been the main method used to detect vertebral fractures. In particular, short tau inversion recovery (STIR) or fat-suppressed T2-weighted image sequences make it easy to diagnose acute fractures, because these sequences have the advantage of detecting bone marrow edema, which appears not only in acute compression fractures but also with bone bruises and load^{1,2)}. Recent technology using dual-energy or two-detector-row computed tomography (DECT) has become widespread, and this technique permits the detection of bone marrow edema by using a virtual non-calcium technique³⁾. The clinical utility of this

¹⁾ Faculty of Health Sciences, Shonan University of Health Sciences, 16-48 Ueshinano, Totsuka-ku, Yokohama 244-0806, Japan.

²⁾ Department of Radiology, Shonan Tobu General Hospital.

³⁾ Department of Radiology, Showa University School of Medicine.

⁴⁾ Department of Radiology, Shonan Tobe General Hospital.

* To whom corresponding should be addressed.

technique has been reported in a variety of situations, including the diagnosis of acute vertebral fractures. However it is difficult to predict whether this method will become a routine examination. One of the main reasons is that the dual-energy method increases radiation exposure. However, the recent progression of dual-source CT (DSCT) had lead to the use of dual-energy method employing a radiation exposure reduction system. The aim of this study was to assess the clinical utility of a virtual non-calcium technique, with MRI sequences serving as the reference standard.

Materials and methods

Forty-one patients with suspected lumbar vertebral fractures who underwent both MRI and virtual non-calcium DECT with DSCT, no more than 2 days apart, at the Shonan Tobu General Hospital between June 2014 and January 2015 were included in this study. The region from the lower thoracic to sacral vertebrae was the target area for the study. For comparison of radiation exposure, 11 patients who underwent conventional scans on DSCT equipment using the optimal Combined Applications to Reduce Exposure (CARE) system and 14 patients who underwent conventional scans with a multi-detector 16-row CT (MDCT) were also included.

Virtual non-calcium DECT images and optimal CARE images were produced with a DSCT scanner (SOMATOM Definition Flash CT; Siemens Healthcare, Forchheim, Germany). For the virtual non-calcium image acquisition, two corresponding detectors were orientated in the gantry with an angular offset of 95° using the dual-energy protocol (collimation 32×0.5 cm; pitch 0.8; rotation time 0.5 s). The MDCT images were obtained with a conventional 16-row MDCT (SOMATOM Emotion16; Siemens Healthcare). MRIs were acquired using a 3 T-MRI (MAGNETOM Verio; Siemens Healthcare) and a 1.5 T-MRI (Signa Horizon LX HiSpeed Plus; GE, Milwaukee, WI, USA).

The two-tube voltages were determined as 140 kV and 80 kV and a virtual 120 kV series with a ratio of 0.4 was generated as the non-calcium image. The data was reconstructed as axial and sagittal planes in 5 mm slices.

Comparison of radiation exposure

Patients who had 9-10 vertebrae scanned were included in the radiation exposure comparison. A total of 23 of 41 patients satisfied the criteria for the virtual non-calcium DECT group (NC group). Two control groups were selected; one group underwent radiation exposure-suppressed single-energy CT using the optimal CARE system (CARE group), and the other underwent conventional 16-row MDCT scans (MDCT group). For statistical analysis, *t* tests were performed to compare the patients' clinical data. A normal distribution could not be obtained for the radiation exposure data, thus Mann-Whitney *U* tests were performed.

Comparison of CT numbers

The region of interest (ROI) was set on the center of the bone marrow edema region on the sagittal view of the virtual non-calcium image, with the T2-weighted sagittal MRI view as the

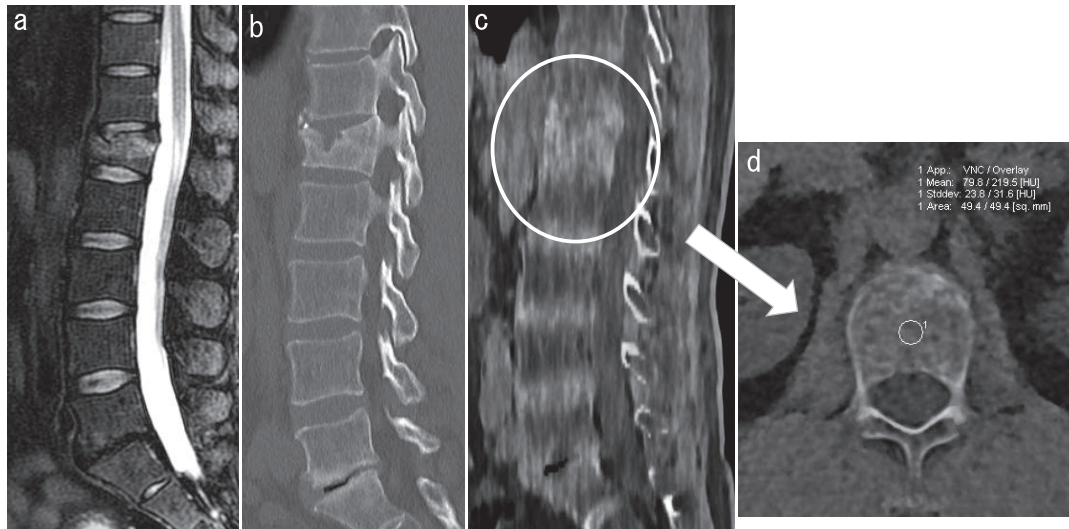


Fig. 1. Images from a male patient in his 50's
 a : Short tau inversion recovery magnetic resonance image. An acute fracture with bone marrow edema can be seen in the L1 vertebra.
 b : Computed tomography sagittal multiplanar reconstruction image. A change in the topographic anatomy can be seen.
 c : Virtual non-calcium dual-energy computed tomography image. The high attenuation area indicates bone marrow edema.
 d : Measurement of the CT number (pixel brightness value) in the L1 vertebra (encircled region from Fig. 1c).

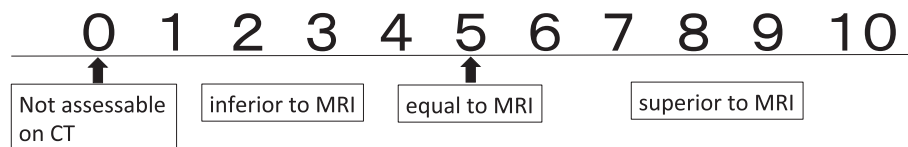

Fig. 2. The visual assessment scale : comparison to magnetic resonance imaging (MRI)

reference (Fig. 1). The ROI was defined as approximately 5 mm^2 . When the ROI was hard to set at 5 mm^2 in a narrow edema region, the ROI was set as large as possible. For statistical analysis, a *t* test was performed to compare the pixel brightness values (CT numbers).

Visual evaluation

The diagnostic value was evaluated on the virtual non-calcium images. The fat-suppressed T2-weighted image was defined as the gold standard. The evaluation was conducted in 14 patients with a diagnosis of acute vertebral fracture on MRI; a total of 18 of 133 vertebrae were affected. In order to calculate any difference in the quality of visual assessment, two experienced radiologists evaluated the quality of the virtual non-calcium images and the fat-suppressed T2-weighted image by consensus to detect the bone marrow edema region, using a 10-point scale (Fig. 2). The average number scored by the two radiologists for the virtual non-calcium images was compared to MRI findings.

Table 1. Age and gender data for each patient group.

Group	Number	Age (years) [†]	Gender (M : F)
NC	23	67.2 ± 17.5*	8 : 16
CARE	11	46.7 ± 26.3	6 : 7
MDCT	14	71.3 ± 16.4*	8 : 7

[†]Values are mean ± standard deviation ; *significantly different to the CARE group ($P < 0.05$).

NC, virtual non-calcium dual-energy computed tomography (CT); CARE, dual-source CT using Combined Applications to Reduce Exposure ; MDCT ; multi-detector 16-row CT.

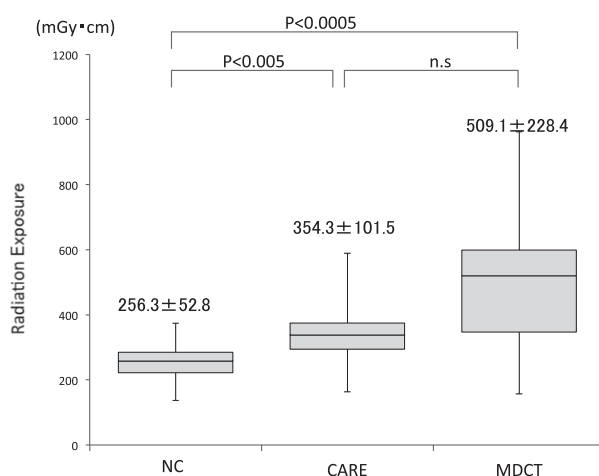


Fig. 3. The radiation exposure (mean ± standard deviation) of virtual non-calcium dual-energy computed tomography (NC ; $n = 23$), dual-source computed tomography using Combined Applications to Reduce Exposure (CARE ; $n = 11$), and multi-detector 16-row computed tomography (MDCT ; $n = 14$).

Results

Table 1 shows the average age and gender of the patient groups. The average age of the CARE group was significantly younger than the other groups, while there was no difference in the average age or gender between the NC group and MDCT group. Fig. 3 shows the differences in radiation exposure between the three groups. Radiation exposure in the NC group (256.3 ± 52.8 mGy.cm) was significantly lower than in both the CARE group (354.3 ± 101.5 mGy.cm ; $P < 0.005$) and the MDCT group (509.1 ± 228.4 mGy.cm ; $P < 0.0005$). There was no difference in radiation exposure between the CARE group and MDCT group.

The CT numbers for the fractured vertebrae were significantly higher than those for the normal vertebrae ($P < 0.0001$; Fig. 4). When the threshold was set at -25.6 HU, which resulted in the highest diagnostic value, the sensitivity was 100% and, specificity was 92.6%. The results of the visual diagnosis assessment are shown in Table 2. The NC image revealed a high diagnostic value compared with the MRI results ; sensitivity was 83.0%, and specificity was 93.0%. In the

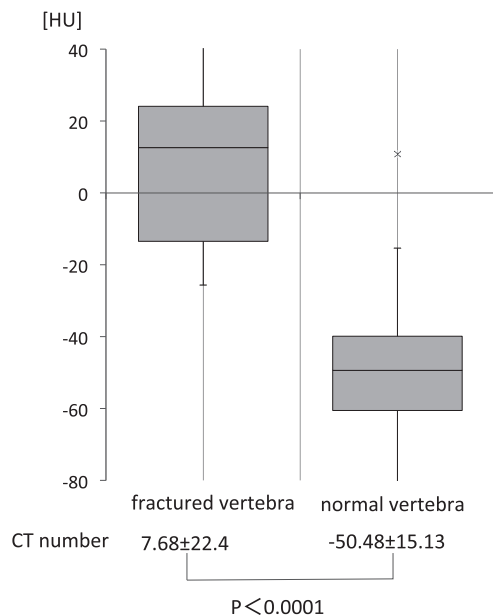


Fig. 4. The CT number (mean \pm standard deviation) of affected (n = 25) and normal (n = 25) vertebrae, calculated from the virtual non-calcium images.

Table 2. The diagnostic value for visual assessment of dual-energy computed tomography (CT), compared to magnetic resonance imaging (MRI).

MRI diagnosis	CT diagnosis	
	positive	negative
positive	15	3
negative	8	107
Sensitivity = 100%		
Specificity = 92.6%		

visual image quality analysis, the image quality was mostly lower for the virtual non-calcium image than for MRI (Fig. 5). Only three affected vertebrae were assessed to have equal findings to the MRI findings. No cases showed superiority of the virtual non-calcium images.

Discussion

In the diagnosis of bone marrow edema, MRI has been widely used, because it is the most feasible technique for detecting anatomic structure and bone marrow edema at the same time^{1,2,4}. Bone scintigraphy facilitates evaluation of the acuteness of vertebral fractures, however the findings are mostly nonspecific and its spatial resolution is obviously inferior to CT and MRI. The development of DECT has enabled the discrimination between two materials^{5,6}, and virtual non-calcium DECT images were developed by the technique of subtracting calcium. The edematous

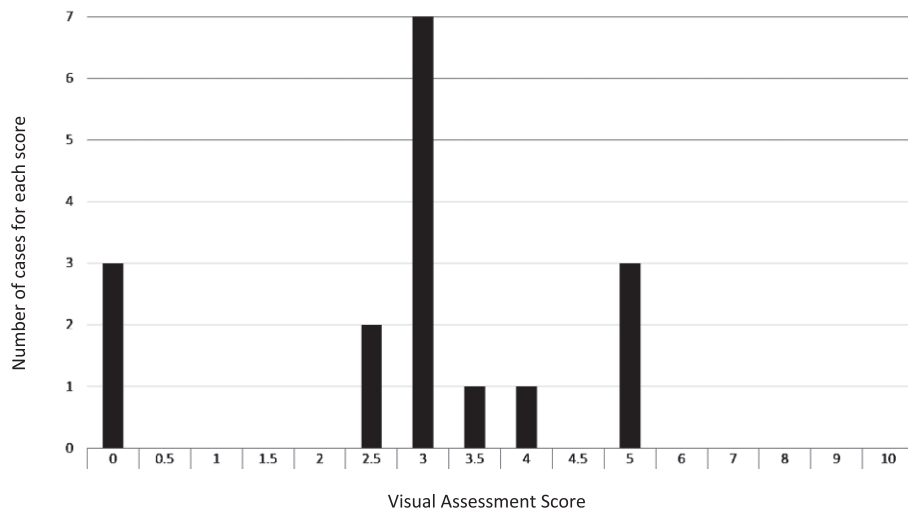


Fig. 5. Breakdown of the visual assessment score, comparing the image quality of virtual non-calcium dual-energy computed tomography images and magnetic resonance images.

region causes an increase in the CT number⁷⁾. Because this technique facilitates the detection of bone marrow edema on CT images, it is now possible to diagnose the “freshness” of fractures without using MRI⁸⁾. The diagnosis of bone marrow edema is really important because its presence indicates an acute phase bone bruise or fracture and may be the precursor of degenerative change^{8,9)}.

Generally, the main concern regarding DECT is its increased radiation exposure rather than its high signal-noise ratio, however, the CT system used in this study was equipped with a radiation exposure reduction system. The two groups imaged using DSCT showed significantly lower radiation exposure, and thus the safety of radiation exposure was shown in this study. The radiation exposure of the NC group was the lowest, however the result was unclear because the two populations (NC and CARE) were significantly different.

To our knowledge, all previous studies have shown apparent advantages of virtual non-calcium DECT to evaluate acute vertebral fractures^{1,3,4)}, and the present study is in accordance with these results. Generally, there are two choices for lower voltage - 100 KeV and 80 KeV. One study advocated 100 KeV because a lower voltage can cause artifacts⁴⁾, however we selected 80 KeV for the lower tube voltage, as a more sensitive resolution can be expected. Based on our experience, the appearance of artifacts does not occur frequently. The CT values of the virtual non-calcium DECT images in our study varied from previous studies and so the threshold should be set for each piece of equipment in accordance with the existing conditions.

The results of this study show the high detectability of acute vertebral fractures using virtual non-calcium DECT images, and our results were equal or superior to previous studies. In our study, all of the false negative cases were considered to be due to the small size of the bone marrow edema region. Wang *et al*⁴⁾ reported that highly calcified vertebrae cannot be properly evaluated, and when vertebrae with regions of calcium density of over 50% were avoided, the

sensitivity reached 96.3%. However, in the present study there was no case where highly calcified vertebrae affected the evaluation of bone marrow edema. This may be due to differences in patient populations depending on the characteristics of the hospitals.

The visual image assessment of virtual non-calcium DECT was mostly inferior to MRI. These results seemed to be due to differences in spatial resolution. Currently, MRI is superior in terms of both detectability and image quality, and so generally, MRI scans should be used as much as possible to evaluate vertebral fractures. However, in situations where an MRI scan is difficult to conduct because of timing constraints, CT scans seem to be sufficient to diagnose vertebral fractures.

There are some limitations in this study. This study focused on bone marrow edema; however, it is only a single aspect of acute vertebral fractures, and thus more detailed diagnostic criteria would be needed if this method is to be used clinically. The number of patients in this study was small and may be biased because the study was conducted in a single general hospital. This is especially true for radiation exposure, as the age distributions were significantly different between the test groups. However, the exposure of both DSCT groups was less than for conventional CT scans. Finally, image quality was only assessed subjectively without a quantitative method, and the diagnostic criteria were also defined only by image diagnosis on MRI.

In conclusion, virtual non-calcium DECT imaging allows the evaluation of vertebral fractures using DSCT scanners and it will possibly play a viable role in the clinical diagnosis of these fractures in the future.

Conflict of interest disclosure

The authors declare that they have no conflict of interest.

References

- 1) Jung HS, Jee WH, McCauley TR, *et al.* Discrimination of metastatic from acute osteoporotic compression spinal fractures with MR imaging. *Radiographics.* 2003;**23**:179-187.
- 2) Mirowitz SA, Apicella P, Reinus WR, *et al.* MR imaging of bone marrow lesions: relative conspicuousness on T1-weighted, fat-suppressed T2-weighted, and STIR images. *AJR Am J Roentgenol.* 1994;**162**:215-221.
- 3) Pache G, Krauss B, Strohm P, *et al.* Dual-energy CT virtual noncalcium technique: detecting posttraumatic bone marrow lesions--feasibility study. *Radiology.* 2010;**256**:617-624.
- 4) Wang CK, Tsai JM, Chuang MT, *et al.* Bone marrow edema in vertebral compression fractures: detection with dual-energy CT. *Radiology.* 2013;**269**:525-533.
- 5) Johnson TR, Krauss B, Sedlmair M, *et al.* Material differentiation by dual energy CT: initial experience. *Eur Radiol.* 2007;**17**:1510-1517.
- 6) Petersilka M, Bruder H, Krauss B, *et al.* Technical principles of dual source CT. *Eur J Radiol.* 2008;**68**:362-368.
- 7) Thiryayi WA, Thiryayi SA, Freemont AJ. Histopathological perspective on bone marrow oedema, reactive bone change and haemorrhage. *Eur J Radiol.* 2008;**67**:62-67.
- 8) Pache G, Krauss B, Strohm P, *et al.* Dual-energy CT virtual noncalcium technique: detecting posttraumatic bone marrow lesions--feasibility study. *Radiology.* 2010;**256**:617-624.
- 9) Barr MS, Anderson MW. The knee: bone marrow abnormalities. *Radiol Clin North Am.* 2002;**40**:1109-1120.

[Received March 10, 2016 : Accepted April 6, 2016]