

Difficulty in surgical procedure selection for myelopathy with atlantoaxial instability in a highly aged patient: A case report of an 85-year-old female who required additional occipitocervical fusion after C1 laminectomy

Ryoji Usui, Yoshifumi Kudo*, Chikara Hayakawa,
Ryo Yamamura, Hiroshi Maruyama, Akira Matsuoka,
Koji Ishikawa, Soji Tani, Katsunori Inagaki
and Tomoaki Toyone

Received: 30 April 2021 / Accepted: 8 June 2021

Abstract

Myelopathy with atlantoaxial instability is a relatively rare condition. It is treated with various surgical methods to treat upper cervical problems, including atlantoaxial fusion, occipitocervical fusion, and C1 laminectomy. However, the choice of surgical method, especially in highly aged (≥ 80 years) patients, is controversial. This case report describes the difficulty of selecting the appropriate surgical procedure for upper cervical and occipitocervical diseases in highly aged patients. An 85-year-old woman complained of neck pain and bilateral hand numbness. The Japanese Orthopedic Association score for cervical myelopathy (C-JOA) of the patient was 9 out of a possible score of 17. Plain radiographs showed atlantoaxial subluxation (AAS) and vertical subluxation (VS), whereas magnetic resonance imaging showed spinal cord compression and myelomalacia at C1–2. The patient underwent a C1 laminectomy to minimize invasive procedures. After surgery, her symptoms improved, and her C-JOA score increased to 12. Fifteen months after surgery, her neurological conditions gradually deteriorated again. Her VS progressed postoperatively, with spinal canal restenosis at the craniovertebral junction. After an additional occipitocervical fusion, her symptoms improved, and she had no evidence of recurrence at her final follow-up. Although surgeons tend to choose less-invasive procedures when treating highly aged patients, appropriate surgical procedures may be required (even if invasive for the patient) when less-invasive treatments failed. Hence, it is important to avoid over-selecting less-invasive surgical procedures for highly aged patients.

Key words :nonrheumatoid arthritis, myelopathy, atlantoaxial instability, postoperative vertical subluxation, occipitocervical fusion

Introduction

Myelopathy with atlantoaxial instability is a relatively rare condition. It occurs in patients with rheumatoid arthritis (RA) and congenital diseases, including Down's syndrome^{1–3}. Recently, as the aging population has grown, more older patients have reported problems in the upper cervical region⁴. Various surgical methods,

including atlantoaxial (C1–2) fusion, occipitocervical (OC) fusion, and C1 laminectomy, have been used to treat upper cervical problems^{5–7}. Apart from the nature of the disease, the patient's background (age, anatomical features, and comorbidities) influences treatment choice. However, selecting the appropriate surgical methods, especially for highly aged (≥ 80 years) patients, remains controversial. Fusion surgery is risky because low bone quality results in instrumentation failure and nonunion, and the invasiveness of the surgery could cause major complications⁸.

This case concerns an 85-year-old (non-RA) woman with myelopathy associated with C1–2 instability. She underwent a C1 laminectomy; however, she

* Corresponding author

✉ Yoshifumi Kudo
kudo_4423@med.showa-u.ac.jp

subsequently required OC fusion because of progressive VS and neurological symptom deterioration.

Case presentation

This is the case of an 85-year-old woman who presented to our hospital with neck pain and bilateral hand numbness. Her symptoms began three months earlier with no known trigger. She had dyspraxia of the hands with pathological reflexes and gait disturbance. However, there was no obvious muscle weakness except for abduction in both shoulders. The patient has a Japanese Orthopedic Association score of 9 for cervical myelopathy (C-JOA score).

Plain radiograph findings showed an increased Atlantodental interval (ADI) of 5.6 mm in the natural position, 5.8 mm in flexion, and 3.5 mm in extension, indicating AAS. The Redlund-Johnell and Ranawat values were 33.4 mm and 11.5 mm, respectively, suggesting VS (Fig. 1A). Magnetic resonance imaging (MRI) findings showed spinal cord compression and myelomalacia at C1-2 (Fig. 1B). We suspected RA considering the myelopathy with C1-2 instability; however, laboratory data did not support this diagnosis. Considering the patient's age, we performed a C1 laminectomy instead of C1-2 fusion to minimize invasive procedures. The patient provided written informed consent for the risk of additional fusion surgery (Fig. 2A). Postoperative external fixation was required with a neck collar for one month. After the surgery, the numbness and motor function of both upper extremities and gait

improved, and her C-JOA score increased to 12. A postoperative MRI revealed effective decompression of the spinal cord (Fig. 2B).

Fifteen months after the surgery, her neurological state gradually deteriorated again. She complained of recurring neck pain, numbness in both upper extremities, and gait disturbance. Her C-JOA score decreased to 9. Radiological analysis showed worsened ADI (7.5 mm in the natural position, 7.1 mm in flexion, and 5.9 mm in extension) and a Redlund-Johnell value of 29 mm (Fig. 3A). Computed tomography (CT) and MRI findings indicated increased VS compared to her postoperative results, and there was spinal canal restenosis at the craniovertebral junction (Fig. 3B, C). Thus, performing OC fusion eighteen months after the first surgery has been decided.

Firstly, VS has been reduced by a halo vest fixation under fluoroscopy before surgery. Following improvement in neurological symptoms, the patient underwent OC fusion without additional intraoperative reduction. We fixed six bi-cortical screws to the occipital bone, lateral mass screws to C2-5, and pedicle screws to C7 (Fig. 4A). We completed postoperative external fixation using a cervical-thoracic orthosis for three months. After the surgery, the numbness and motor function of both upper extremities and gait improved, and the patient's C-JOA score returned to 12. Postoperative radiographs and CT findings revealed an improvement in ADI and basilar invagination (Fig. 4B), and MRI findings showed an improvement in spinal canal stenosis at

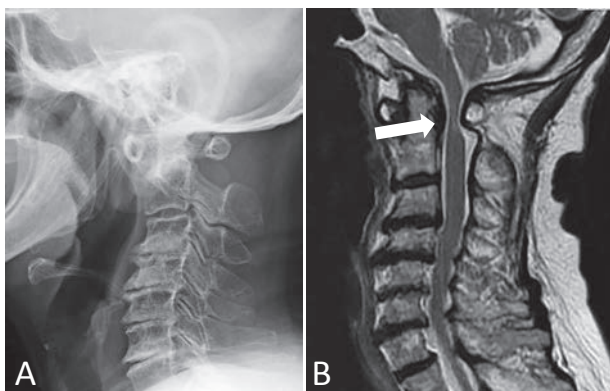


Fig. 1. Cervical spine images of the patient on admission
A: Preoperative lateral radiograph showing atlantoaxial and vertical subluxation (Atlantodental interval, 5.6 mm; Redlund-Johnell value, 33.4 mm; Ranawat value, 11.5 mm).
B: Preoperative sagittal T2-weighted magnetic resonance imaging findings showing compression of the spinal cord at the C1-2 level (Arrow).

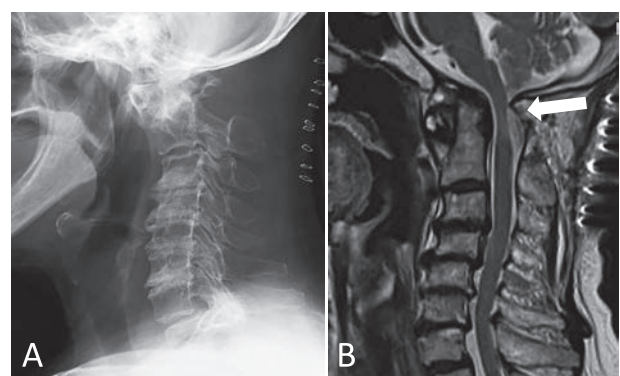


Fig. 2. Cervical spine images after C1 laminectomy
A: Postoperative lateral radiograph.
B: Postoperative sagittal T2-weighted magnetic resonance imaging findings showing effective decompression of the spinal cord (Arrow).

the craniovertebral junction (Fig. 4C). No evidence of recurrence was observed at the final follow-up, and the C-JOA score remained at 12.

Discussion

There are various surgical strategies proposed for myelopathy associated with C1-2 instability. However, clinical decision-making for surgical procedures is challenging, especially in highly aged patients. Takemoto *et al.* reported ten retro-odontoid pseudotumors and myelopathy cases that were treated with C1 laminectomy without fusion. They reported that C1 laminectomy alone was effective and that instability did not progress in eight patients. The remaining two patients with increased ADI showed no clinical problems⁴. Yamada *et al.* reported 30 cases of spinal surgeries performed for AAS patients,

with C1 laminectomy and C1-2 fusion in 11 and 19 cases, respectively: They indicated that C1-2 fusion techniques effectively led to neurological recovery. However, complication rates were higher in C1-2 fusion compared with those in C1 laminectomy. They concluded that C1 laminectomy should be considered for high-risk cases, including those in highly aged patients⁷. Oda *et al.* stated that in RA patients, C1-2 fusion might be effective for AAS alone; however, in AAS with VS, C1-2 fusion is not sufficient, and OC fusion is recommended because there is a risk of deterioration of VS after C1-2 fusion⁹.

Although there is a risk of additional fusion surgery for VS deterioration, we only performed the minimally invasive C1 laminectomy for the following reasons: There was no RA diagnosis, and the patient was of advanced age with a low activity level. Fusion would have reduced her quality of life.

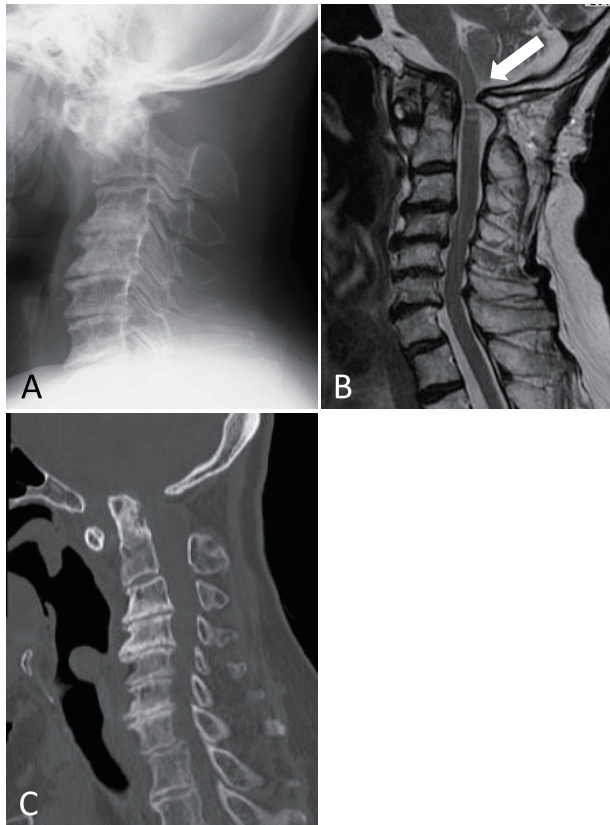


Fig. 3. Cervical spine images before additional occipitocervical fusion surgery

- A: Lateral radiograph showing a worsened Atlantoaxial interval (7.5 mm in the natural position, 7.1 mm in flexion, and 5.9 mm in extension) and Redlund-Johnell value of 29 mm.
 B: Sagittal T2-weighted magnetic resonance imaging findings. The vertical dislocation had increased compared to postoperative results, and spinal canal stenosis was observed at the craniovertebral junction (Arrow).
 C: Sagittal computed tomography imaging findings.

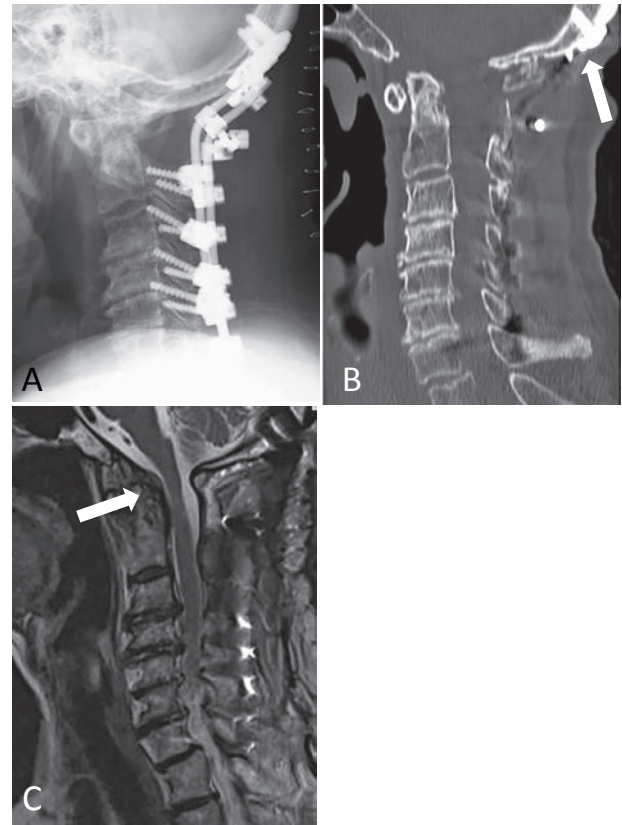


Fig. 4. Cervical spine images after occipitocervical fusion surgery

- A: Lateral radiograph after additional surgery showing a reduction in atlantoaxial and vertical subluxation.
 B: Sagittal computed tomography imaging findings at the final follow-up showing no evidence of implant failure.
 C: Sagittal T2-weighted magnetic resonance imaging findings showing decompression of the spinal cord at the craniovertebral junction (Arrow).

There was an increased risk of instrumentation failure due to poor bone quality, and the patient and her family did not want invasive surgery. Although her symptoms improved post-laminectomy, she eventually required invasive OC fusion because of the increased severity of AAS and VS.

Since such symptoms are caused by instability, C2 fusion might be necessary regardless of the patient's age. However, which surgical procedure (C1-2 or OC fusion) is most suitable for this case remains controversial. Clarke *et al.* reported the clinical outcomes of 20 cases of OC fusion surgery in highly aged patients (over 65 years; average, 75.3 years): Perioperative mortality and major morbidity occurred in 5% and 10% of patients, respectively. With careful medical management and monitoring of perioperative complications, OC fusion is recommended for significant neurologic recovery even in highly aged patients¹⁰.

The decision about the caudal extent of the fusion is an important issue. In most cases, the caudal extent of the fusion is C2 or C3¹¹. However, in selected conditions, including degenerative changes in the middle or lower cervical levels, involving these levels in the fusion is recommended¹². The fusion was extended down to C7, considering the poor bone quality and degenerative change in our patient's mid-cervical spine. There was bone union at the final follow-up visit, with no evidence of screw loosening. In OC fusion surgery in highly aged patients, bone quality could be one of the important determinants of the fusion level.

Wang *et al.* reported that the risk of complications and mortality in cervical spine surgery increases significantly with age. In patients aged 65–74 years and those >75 years, the odds of having any complication were 2 and 3.1 times higher than average, respectively, and the odds of death during admission were 3.8 and 9.5 times higher, respectively¹³. A higher risk of complications and mortality is expected in highly aged patients; however, the risk of nonsurgical management is even higher⁷. Surgeons should consider the results of this report when deciding on a suitable treatment for similar patients.

Conclusions

This is a case of a highly aged patient with myelopathy who underwent C1 laminectomy and subsequently required OC fusion due to progressive VS. Although surgeons tend to choose less-invasive procedures when treating highly aged patients, appropriate surgical procedures may be required

(even if invasive for the patient) when less-invasive treatments failed. Hence, it is important to avoid over-selection of less-invasive surgical procedures for highly aged patients.

Conflicts of interest disclosure

The authors have no conflicts of interest to declare.

Source of funding

None

Acknowledgments

Ryoji Usui and Yoshifumi Kudo acquired and interpreted the clinical data and wrote the manuscript. Yoshifumi Kudo and Tomoaki Toyone edited and revised the manuscript critically for important content. Chikara Hayakawa, Ryo Yamamura, Akira Matsuoka, Hiroshi Maruyama, Koji Ishikawa, Soji Tani, and Katsunori Inagaki revised the manuscript.

Ethical approval

An Institutional Review Board review was waived due to the article type.

Informed consent

The patient provided written informed consent for the publication of this case report.

References

1. Bolm M, Creemers MC, Kievit W, *et al.* Long-term follow-up of the cervical spine with conventional radiographs in patients with rheumatoid arthritis. *Scand J Rheumatol.* 2013;**42**:281–288.
2. Yurube T, Sumi M, Nishida K, *et al.* Incidence and aggravation of cervical spine instabilities in rheumatoid arthritis: a prospective minimum 5-year follow-up study of patients initially without cervical involvement. *Spine (Phila Pa 1976).* 2012;**37**:2136–2144.
3. Elliott S, Morton R, Whitelaw RA. Atlantoaxial instability and abnormalities of the odontoid in Down's syndrome. *Arch Dis Child.* 1988;**63**:1484–1489.
4. Betsch M, Blizzard S, Shinseki M, *et al.* Prevalence of degenerative changes of the atlanto-axial joints. *Spine J.* 2015;**15**:275–280.
5. Takemoto M, Neo M, Fujibayashi S, *et al.* Clinical and radiographic outcomes of C1 laminectomy without fusion in patients with cervical myelopathy that is associated with a retro-odontoid pseudotumor. *Clin Spine Surg.* 2016;**29**:E514–E521.
6. Kakutani K, Doita M, Yoshikawa M, *et al.* C1 laminectomy for retro-odontoid pseudotumor without

- atlantoaxial subluxation: review of seven consecutive cases. *Eur Spine J.* 2013;**22**:1119–1126.
7. Matsunaga S, Sakou T, Onishi T, *et al.* Prognosis of patients with upper cervical lesions caused by rheumatoid arthritis: comparison of occipitocervical fusion between C1 laminectomy and nonsurgical management. *Spine (Phila Pa 1976)*. 2003;**28**:1581–1587; discussion 1587.
 8. Yamada T, Yoshii T, Matsukura Y, *et al.* Retrospective analysis of surgical outcomes for atlantoaxial subluxation. *J Orthop Surg Res.* 2019;**14**:75. (accessed 2021 Apr 23) Available from: https://www.ncbi.nlm.nih.gov/pmc/articles/PMC6407200/pdf/13018_2019_Article_1112.pdf
 9. Oda T, Fujiwara K, Yonenobu K, *et al.* Natural course of cervical spine lesions in rheumatoid arthritis. *Spine (Phila Pa 1976)*. 1995;**20**:1128–1135.
 10. Clarke M, Toussaint LG 3rd, Kumar R, *et al.* Occipitocervical fusion in elderly patients. *World Neurosurg.* 2012;**78**:318–325.
 11. Helgeson MD, Lehman RA Jr, Sasso RC, *et al.* Biomechanical analysis of occipitocervical stability afforded by three fixation techniques. *Spine J.* 2011;**11**:245–250.
 12. Kukreja S, Ambekar S, Sin AH, *et al.* Occipitocervical fusion surgery: review of operative techniques and results. *J Neurol Surg B Skull Base.* 2015;**76**:331–339.
 13. Wang MC, Chan L, Maiman DJ, *et al.* Complications and mortality associated with cervical spine surgery for degenerative disease in the United States. *Spine (Phila Pa 1976)*. 2007;**32**:342–347.