

Case Report

A Cluster of Respiratory Syncytial Virus Infections in a Hospital Ward for Adult Immunocompromised Patients

Yasuhiro NAGATOMO*¹⁾, Takahiro TAKUMA¹⁾, Issei TOKIMATSU¹⁾,
Yoshihiko NIKI¹⁾, Shun FUJIWARA²⁾, Ayaka NAKATA²⁾,
Youhei SASAKI²⁾, Shotaro SHIMADA²⁾, Megumi WATANUKI²⁾,
Maasa ABE²⁾, So MURAI²⁾, Yuta BABA²⁾,
Yukiko KAWAGUCHI²⁾, Nana ARAI²⁾, Nobuyuki KABASAWA²⁾,
Tomoharu MATSUI²⁾, Hiroyuki TSUKAMOTO²⁾, Yui UTO²⁾,
Norimichi HATTORI²⁾, Bungo SAITO²⁾, Kouji YANAGISAWA²⁾
and Tsuyoshi NAKAMAKI²⁾

Abstract : Four male patients admitted to the same ward in the first half of September 201Y were identified to have respiratory syncytial virus (RSV) infection. Their ages ranged from 49 to 85 years (median 72.5). One patient was infected with human immunodeficiency virus and three patients had hematological malignancies. Following immuno-chromatological testing with a nasal cavity swab, RSV infection was diagnosed. Although blood and sputum cultures were performed in three patients, no significant bacteria were detected. Two cases responded to supportive therapy. However, one patient died secondary to multiple myeloma, and another patient developed pneumonia and died with an exacerbation of leukemia. RSV infections in immunocompromised hosts are associated with a poor prognosis. Early diagnosis will facilitate isolation of infected individuals to prevent hospital outbreaks.

Key words :respiratory syncytial virus, immunocompromised host, adult onset, summertime development, outbreak

Introduction

Respiratory syncytial virus (RSV) is the etiologic agent of an important seasonal respiratory infection in young children. Approximately 10% of children under 5 years old require inpatient care for RSV infection¹⁾. The infection typically peaks during winter months²⁾. RSV recently emerged as an important pathogen and etiologic agent of lower respiratory infections in elderly adults^{3,4)}. Additionally, cases of RSV infection during the summer months have been reported⁵⁾. Of critical concern, outbreaks of RSV infection in patients with hematologic disorders or immunocompromised patients have been reported^{6,7)}. We report four cases of immunocompromised adults, admitted to the same ward, who developed RSV disease.

¹⁾ Department of Medicine, Division of Clinical Infection Diseases, Showa University School of Medicine, 1-5-8, Hatanodai, Shinagawa-ku, Tokyo 142-8555, Japan.

²⁾ Department of Medicine, Division of Hematology, Showa University School of Medicine.

* To whom corresponding should be addressed.

Background and clinical course (Table 1, Figure 1)

Case 1

A 49-year-old man, previously diagnosed with HIV infection and receiving treatment with combination anti-retroviral therapy, was admitted to the hospital on September X, 201Y, for evaluation and treatment of anemia. Laboratory findings on admission revealed pancytopenia, including a white blood cell count (WBC) of 3,300 / μ l, hemoglobin (Hb) of 6.9 g/dl, and a platelet count (Plts) of 37,000 / μ l. He developed a persistent fever ($> 38^{\circ}\text{C}$) and nasal discharge that was refractory to treatment with pazufloxacin (PZFX) which was initiated on the 9th day of hospitalization. Because RSV was prevalent at the time, an immuno-chromatological test (Prime Check[®] RSV; Alfresa Pharma Co., Ltd., Osaka, Japan) was performed on a nasal cavity swab resulting in a diagnosis of acute RSV infection. The infection ultimately resolved with supportive therapy. Following improvement in anemia, he was discharged from the hospital.

Case 2

An 85-year-old man, previously diagnosed with multiple myeloma (IgG, κ type), was admitted to the hospital on September X + 5, 201Y with a chief complaint of generalized bone pain. Laboratory findings on admission included pancytopenia, with a WBC of 2,200 / μ l, Hb of 9.8 g/dl, and Plt of 140,000 / μ l associated with hyperglobulinemia (total protein of 12.5 g/dl and total IgG of 6,265 mg/dl). He was treated with carfilzomib on the day of admission. Five days later, 2 days following the onset of fever in Case 1, he developed a high fever and nasal discharge. Rapid diagnostic tests for influenza and mycoplasma pneumoniae were negative. RSV infection was diagnosed as described for Case 1. The RSV infection resolved gradually over eight days. However, he died secondary to multiple myeloma.

Table 1. Background and clinical characteristics of four patients during RSV diagnosis

Case	Hematologic disease	Complication	Laboratory data at onset of RSV infection	Culture	Treatment	Outcome
Age/Sex			WBC (/ μ l) CRP (mg/dl)	Blood Sputum	Oxygen Antimicrobials Steroid	
1 49/M	HIV	Lung nodule	2,600 11.4	N.D Negative	No PZFX No	Recovered and discharged on 28 HD
2 85/M	Multiple myeloma	None	1,200 4.2	Negative Negative	No MEPM No	Died from myeloma progression on 49 HD
3 77/M	Chronic lymphocytic leukemia	COPD	17,700 7.3	Negative N.D	Yes CFPM Yes	Died from pneumonia and leukemia on 33 HD
4 68/M	Malignant lymphoma	None	800 0.2	N.D N.D	Yes CFPM + AMK Yes	Recovered and discharged on 17 HD

RSV, respiratory syncytial virus; HIV, Human immunodeficiency virus; COPD, chronic obstructive pulmonary disease; N.D, not done; PZFX, Pazufloxacin; MEPM, Meropenem; CFPM, Cefepime; AMK, Amikacin; HD, hospital day

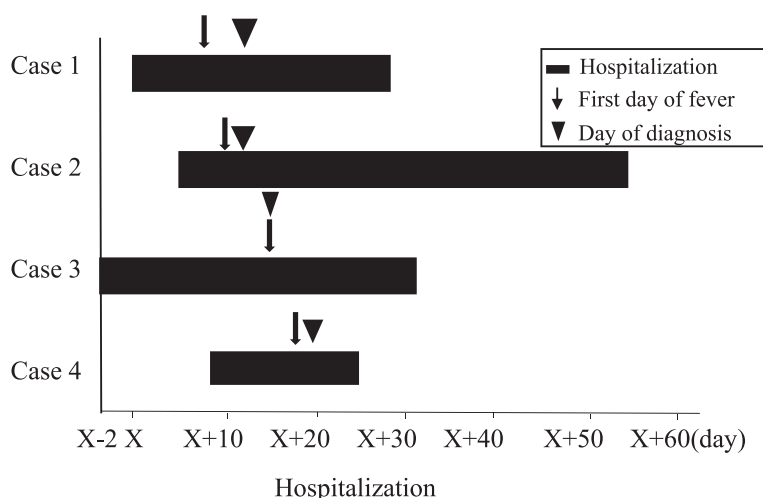


Fig. 1. Clinical courses of four patients with respiratory syncytial virus infection

Case 3

A 77-year-old man, previously diagnosed with chronic lymphocytic leukemia (CLL) and chronic obstructive pulmonary disease (COPD), presented to our hospital on September X-2, 201Y for evaluation and treatment of an exacerbation of his leukemia. Laboratory findings on admission included a marked lymphocytosis, WBC of 17,400/ μ l with 94.5% abnormal lymphocytes. He was treated with ofatumumab on the 10th day following admission. On hospital day 17, 7 days after the onset of fever in Case 1, he developed a high fever and nasal discharge, which was diagnosed as RSV infection, as described for Case 1. He died from pneumonia and an exacerbation of his leukemia.

Case 4

A 68-year-old man previously diagnosed with malignant lymphoma was admitted to our hospital on September X + 8, 201Y to begin round six of his chemotherapeutic regimen. On admission, laboratory findings included pancytopenia, with a WBC of 3,200/ μ l, and a Hb of 7.6 g/dl, and hypoglobulinemia (IgG, 526 mg/dl). Chemotherapy was initiated on the day of admission. Nine days later, 9 days following the onset of fever in Case 1, he developed a high fever and nasal discharge. RSV infection was diagnosed, as described for Case 1. His RSV infection resolved with supportive therapy, and following the completion of chemotherapy, he was discharged from the hospital.

As noted above, four adult males, age 49–85 years (median 72.5), were admitted to the same ward of our hospital during the first half of September 201Y. All four were temporarily admitted to the same room. As noted in the case reports, underlying disorders included HIV infection, multiple myeloma, CLL, and malignant lymphoma (Table 1). Lung disease was identified as a comorbidity in two of the patients. One of these exhibited a ground glass nodule on imaging, and the other was diagnosed with COPD. All four had nasal discharge and fever at the onset of RSV

infection. After obtaining a nasal cavity swab, a definitive diagnosis of RSV infection was made using rapid antigen testing. Upon diagnosis, each patient was isolated in a private room, as per hospital protocol, for prevention of airborne droplet exposure and contact infection.

Laboratory findings at the onset of RSV infection were as follows: WBC ranged from 800 to 17,700 / μ l (median 1,900 / μ l), and C-reactive protein levels ranged from 0.2 to 11.4 mg/dl (median 5.8 mg/dl) (Table 1). Blood and sputum cultures were performed in two patients with negative results.

The 77-year-old patient with a primary diagnosis of CLL (Case 3) and COPD developed pneumonia. At the onset of RSV infection, his percutaneous oxygen saturation dropped to 70%, and he was provided with oxygen therapy (Figure 2).

Based on our observations, Case 1 was the index and a typical case of RSV infection. He experienced four days of high fever during the second week of admission. Subsequently, another patient (Case 2) developed a fever, potentially via exposure to airborne droplets. On day 4 of his fever, he was isolated due to severe cough. The other two patients, Cases 3 and 4, exhibited continuous fever lasting from 7 to 16 days.

All cases were treated with supportive therapy, including antimicrobial agents: cefepime for two patients, PZFX for one patient, and meropenem for one patient (Table 1). Additionally, two patients were treated with steroids. Prior to discharge, two of the cases of RSV infection resolved. In Case 2, the patient died secondary to his hematological disorder on hospital day 49. Case 3 died on hospital day 33 due to pneumonia and complications associated with his primary hematological disorder (Table 1). Chest computed tomography (CT) on the seventh day following RSV infection in Case 3 revealed bilateral ground glass infiltrates and infiltration shadows (Figure 3). In response to this outbreak, members of the medical staff were directed to pay careful attention to hand hygiene and to wear surgical masks while on duty. No staff members developed RSV infection.

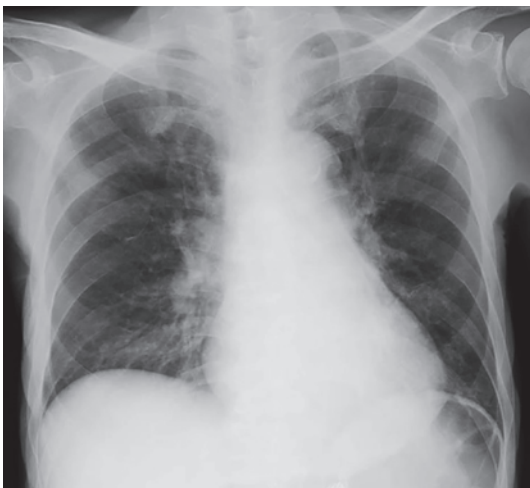

Fig. 2. Chest X ray during respiratory syncytial virus diagnosis (Case 3)
Ground glass shadow in the right lower field.

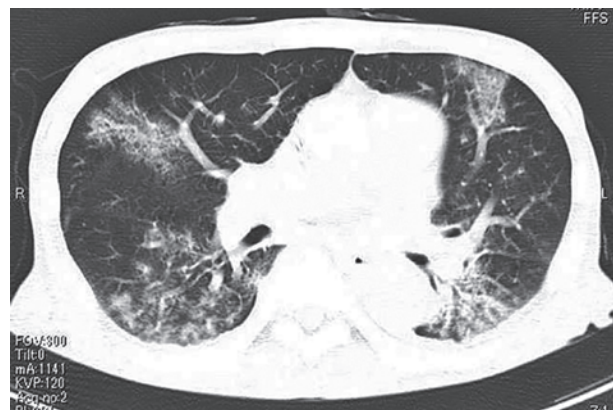

Fig. 3. Chest CT 7 days after respiratory syncytial virus diagnosis (Case 3)
Infiltration and ground glass shadows in bilateral lung fields.

Discussion

RSV infection in childhood does not result in permanent immunity, as individuals may experience recurrent infections throughout their lifetime⁸⁾. Falsey *et al* reported that RSV infections developed in 3% to 7% of healthy elderly patients annually and in 4% to 10% of patients with chronic heart or lung disease during a four-year prospective surveillance⁹⁾. Another recent study found that the fatality rate for RSV infections in the elderly was elevated and similar to that reported for seasonal influenza¹⁰⁾. Our four cases were all males, three were over the age of 65, and one died at the age of 77 from complications related to RSV.

RSV infections occur worldwide with a seasonal prevalence, primarily during the winter. It is believed that low temperatures are one of the major reasons for an outbreak. However, in tropical areas, such as those around the equator, RSV infections can occur year-round, and they are prevalent during the rainy season which has been attributed to increased humidity²⁾. Specifically, RSV cases have been reported during a damp summer in Japan⁵⁾. In the cases noted in this report, RSV was contracted during a warm September prior to the onset of the cooler fall months.

RSV causes infection by the nasal cavity, pharynx, and eyelid mucosal membranes coming into contact with respiratory tract secretions and contaminated fomites. The incubation period ranges from three to five days, and the disease lasts approximately one to two weeks. All four patients were initially admitted into the same hospital room. We believe that Case 1 contracted RSV from contact with a visitor to the ward. Immunocompromised hosts can excrete the virus into the environment for a prolonged period of time, and the viral shedding persists even after symptom improvement. Therefore, once RSV infection occurs in a ward of immunocompromised patients, there is a serious risk of an outbreak with an associated poor prognosis. We also recognized that RSV infection corresponded to an epidemic period in our cases. Jensen *et al*⁶⁾ reported 12 adult immunocompromised patients and one staff member on a hematology ward becoming infected with RSV, and two of them ultimately died. Lehnert *et al*⁷⁾ evaluated 40 patients with RSV lower respiratory tract infection on a hematology and transplantation ward. Of these 40, 35% died due to concomitant fungal and bacterial infections making a determination of the primary cause of death difficult⁷⁾. On multivariate analysis, reduced concentrations of serum IgG were associated with their fatalities. Since IgG was not measured in Case 3, we cannot evaluate this relationship.

If a typical case of RSV infection appears on a ward, early diagnosis is extremely important, and early isolation of the patient is necessary to prevent an outbreak. Prime check[®] RSV is a rapid antigen test using an immunochromatographic method with point-of-care testing that facilitates early confirmation of RSV infection. In a recent systematic review and meta-analysis¹¹⁾, the rapid antigen test exhibited a sensitivity of 80% and a specificity of 97% when compared to results obtained using reverse transcriptase-polymerase chain reaction (RT-PCR), immunofluorescence, or viral culture. Of the 71 publications reviewed by Chartrand *et al*¹¹⁾, in the largest study, with 794 culture-confirmed RSV infections, 643 were determined as positive by the rapid antigen test. The rapid antigen test is a common diagnostic modality in current clinical practice;

however, the results depend on timing, and there are concerns about false negative results in some adults¹²⁾. As such, virus quantification by the real-time RT-PCR method is the most sensitive test, and is highly accurate diagnostically. It has been reported that the viral RNA concentration is correlated with the risk of respiratory failure¹³⁾. Unfortunately, the PCR method is relatively expensive as it requires well-trained technicians and fully contamination-free facilities.

Miller *et al* reported that a chest CT may be useful to detect centrilobular airway patterns, bronchial wall thickening, and occasionally infiltration shadows associated with RSV pneumonia¹⁴⁾. A chest CT of Case 3 noted bilateral ground glass lesions and discrete infiltration shadows associated with RSV pneumonia. Unfortunately, because of an exacerbation of COPD and his overall deteriorating condition, fiber optic bronchoscopy and sputum culture could not be performed. Therefore, we could not completely rule out the possibility of concomitant infection with bacteria and/or fungi and/or pulmonary invasion with leukemic cells. It has been reported that 6%–7% of cases with COPD exacerbation were caused by RSV^{15,16)}.

No anti-RSV-specific antiviral agent is available for clinical use. In some facilities, ribavirin inhalation therapy is used, and its efficacy has been reported¹⁷⁾. However, its efficacy remains controversial, and more effective and safer antiviral agents are needed. Although a trial of montelukast, a leukotriene antagonist, was carried out for the treatment of respiratory symptoms in pediatric bronchiolitis caused by RSV infection, its efficacy was not established¹⁸⁾. Furthermore, a trial of an orally administered steroid, dexamethasone, showed no evidence of effect in pediatric bronchiolitis¹⁹⁾. For these reasons, supportive therapies such as oxygen inhalation and intravenous rehydration are the mainstays for RSV infection. If patients present with a bacterial infection, they are treated with antimicrobial drugs. In our four cases, even though blood and sputum cultures were negative, all cases received antimicrobials drugs in consideration of their immunocompromised status.

Similarly, no vaccines are currently available for prophylaxis against RSV infection. The only available preventative treatment is palivizumab for high risk infants. This is a monoclonal antibody with a strong neutralizing effect against RSV infection and is effective in immunocompromised infants²⁰⁾.

At present, RSV infections in elderly adults are frequently not recognized²¹⁾. Moreover, because the chief complaints associated with adult RSV infection resemble those of the common cold, the population with disease is not captured accurately. Nevertheless, an outbreak of RSV infection can occur in outpatient settings such as a cancer center²²⁾ or nursing home²³⁾. Therefore, we must consider RSV infections in adults with common-cold-like acute respiratory symptoms even if it is not winter and pay attention to local information about the infection. Early diagnosis of RSV infection, patient isolation, and infection control via contact and airborne droplet precautions are necessary to maintain the health and safety of patients and medical staff in the hospital setting.

Conflict of interest disclosure

The authors declare that they have no conflicts of interest.

References

- 1) Shi T, McAllister DA, O'Brien KL, *et al.* Global, regional, and national disease burden estimates of acute lower respiratory infections due to respiratory syncytial virus in young children in 2015: a systematic review and modeling study. *Lancet.* 2017;**390**:946–958.
- 2) Welliver RC. Temperature, humidity, and ultraviolet B radiation predict community respiratory syncytial virus activity. *Predict Infect Dis J.* 2007;**26**(11 Suppl):S29–S35.
- 3) Sundaram ME, Meece JK, Sifakis F, *et al.* Medically attended respiratory syncytial virus infections in adults aged ≥ 50 years: clinical characteristics and outcomes. *Clin Infect Dis.* 2014;**58**:342–349.
- 4) Falsey AR, McElhaney JE, Beran H, *et al.* Respiratory syncytial virus and other respiratory viral infections in older adults with moderate to severe influenza-like illness. *J Infect Dis.* 2014;**209**:1873–1881.
- 5) Shobugawa Y, Takeuchi T, Hibino A, *et al.* Occurrence of human respiratory syncytial virus in summer in Japan. *Epidemiol Infect.* 2017;**145**:272–284.
- 6) Jensen TO, Stelzer-Braid S, Willenborg C, *et al.* Outbreak of respiratory syncytial virus (RSV) infection in immunocompromised adults on a hematology ward. *J Med Virol.* 2016;**88**:1827–1831.
- 7) Lehnert N, Schnitzler P, Geis S, *et al.* Risk factors and containment of respiratory syncytial virus outbreak in a hematology and transplant unit. *Bone Marrow Transplant.* 2013;**48**:1548–1553.
- 8) Russell CD, Unger SA, Walton M, *et al.* The human immune response to respiratory syncytial virus infection. *Clin Microbiol Rev.* 2017;**30**:481–502.
- 9) Falsey AR, Hennessey PA, Formica MA, *et al.* Respiratory syncytial virus infection in elderly and high-risk adults. *N Engl J Med.* 2005;**352**:1749–1759.
- 10) Lee N, Lui GC, Wong KT, *et al.* High morbidity and mortality in adults hospitalized for respiratory syncytial virus infections. *Clin Infect Dis.* 2013;**57**:1069–1077.
- 11) Chartrand C, Tremblay N, Renaud C, *et al.* Diagnostic accuracy of rapid antigen detection tests for respiratory syncytial virus infections: systematic review and meta-analysis. *J Clin Microbiol.* 2015;**53**:3738–3749.
- 12) Casiano-Colon AE, Hulbert BB, Mayer TK, *et al.* Lack of sensitivity of rapid antigen tests for the diagnosis of respiratory syncytial virus infection in adults. *J Clin Virol.* 2003;**28**:169–174.
- 13) Lee N, Chan MC, Lui GC, *et al.* High viral load and respiratory failure in adults hospitalized for respiratory syncytial virus infection. *J Infect Dis.* 2015;**212**:1237–1240.
- 14) Miller WT, Mickus TJ, Barbosa E, *et al.* CT of viral lower respiratory tract infections in adults: comparison among viral organisms and between viral and bacterial infections. *AJR Am Roentgenol.* 2011;**197**:1088–1095.
- 15) Falsey AR, Formica MA, Hennessey PA, *et al.* Detection of respiratory syncytial virus in adults with chronic obstructive pulmonary disease. *Am J Respir Crit Care Med.* 2006;**173**:639–643.
- 16) De Serres G, Lampron N, La Forge J, *et al.* Importance of viral and bacterial infections in chronic obstructive pulmonary disease exacerbations. *J Clin Virol.* 2009;**46**:129–133.
- 17) Shah DP, Ghantaji SS, Shah JN, *et al.* Impact of aerosolized ribavirin on mortality in 280 allogeneic haematopoietic stem cell transplant recipients with respiratory syncytial virus infections. *J Antimicrob Chemother.* 2013;**68**:1872–1880.
- 18) Bisgaard H, Flores-Nunez A, Goh A, *et al.* Study of montelukast for the treatment of respiratory symptoms of post-respiratory syncytial virus bronchiolitis in children. *Am J Respir Crit Care Med.* 2008;**178**:854–860.
- 19) Corneli HM, Zorc JJ, Mahajan P, *et al.* A multicenter, randomized, controlled trial of dexamethasone for bronchiolitis. *N Engl J Med.* 2007;**357**:331–339.
- 20) Mori M, Onodera M, Morimoto P, *et al.* Palivizumab use in Japanese infants and children with immunocompro-

- mised conditions. *Pediatr Infect Dis J.* 2014;**33**:1183–1185.
- 21) Branche AR, Falsey AR. Respiratory syncytial virus infections in older adults: an under-recognized problem. *Drug Aging.* 2015;**32**:261–269.
 - 22) Chu HY, Englund JA, Podczervinski S, *et al.* Nosocomial transmission of respiratory syncytial virus in an outpatient cancer center. *Biol Blood Marrow Transplant.* 2014;**20**:844–851.
 - 23) Doi I, Nagata N, Tsukagoshi H, *et al.* An outbreak of acute respiratory infections due to human respiratory syncytial virus in a nursing home for the elderly in Ibaraki, Japan, 2014. *Jpn J Infect Dis.* 2014;**67**:326–328.

[Received March 23, 2020 : Accepted June 19, 2020]