MYC expression and translocation in DLBCL-type iatrogenic immunodeficiency-associated lymphoproliferative disorder

Nobuyuki Kabasawa,[1)2)] Eisuke Shiozawa,[1)] So Murai,[1)] Mayumi Homma,[1)] Yuka Uesugi,[2)] Tomoharu Matsui,[2)] Ayaka Nakata,[2)] Shotaro Shimada,[2)] Yohei Sasaki,[2)] Yuta Baba,[2)] Megumi Watanuki,[2)] Nana Arai,[2)] Shun Fujiwara,[2)] Yukiko Kawaguchi,[2)] Hiroyuki Tsukamoto,[2)] Yui Uto,[2)] Kouji Yanagisawa,[2)] Norimichi Hattori,[2)] Hirotaka Sakai,[3)] Hiroshi Harada,[3)] Tsuyoshi Nakamaki,[2)] Masafumi Takimoto,[1)] Toshiko Yamochi-Onizuka[1)]

[1)] Department of Pathology, Showa University School of Medicine, Tokyo, Japan, [2)] Division of Hematology, Department of Medicine, Showa University School of Medicine, Tokyo, Japan, [3)] Division of Hematology, Department of Medicine, Showa University Fujigaoka Hospital, Kanagawa, Japan

Corresponding author: Nobuyuki Kabasawa

Department of Pathology, Showa University School of Medicine, 1-5-8 Hatanodai, Shinagawa-Ku, Tokyo 142-8666, Japan

Fax: +81-3-3784-8250

E-mail: n.kabasawa@med.showa-u.ac.jp

Running title: MYC translocation in DLBCL type LPD

Abstract

C-MYC protein expression and gene translocation are prognostic markers for diffuse large B-cell lymphoma, not otherwise specified (DLBCL, NOS). Few published reports exist on MYC expression and translocation in DLBCL-type iatrogenic immunodeficiency-associated lymphoproliferative disorder (DLBCL-type LPD); therefore, its pathological features remain unclear. We examined and compared clinicopathological features, especially MYC aberration status, in DLBCL-type LPD and DLBCL, NOS. In 2007–2017, 25 patients were diagnosed with post-transplantation lymphoproliferative disorders (PTLDs) and other iatrogenic immunodeficiency-associated LPDs (OIIA-LPDs). Thirty patients with DLBCL, NOS were selected for comparison. Among 25 patients with PTLDs and OIIA-LPDs, 13 patients had the DLBCL type. The histological subtype nongerminal center B-cell-like type was found in all (100%) patients with DLBCL-type LPD and in 57% of patients with DLBCL, NOS ($p=0.003$). With regard to the expression of EBER-ISH in tumor cells, 8 (62%) of 13 patients with DLBCL-type LPD and 1 (3%) patient with DLBCL, NOS had positive results ($p<0.001$). MYC expression was positive in 7 (54%) of 13 patients with DLBCL-type LPD and in 9 (30%) of 30 patients with DLBCL, NOS ($p=0.178$). The fluorescence in situ hybridization analysis of MYC translocation revealed that no (0%) patient with DLBCL-type LPD and 13% of patients with DLBCL, NOS had positive results ($p=0.026$); this difference was significant. Lack of MYC translocation is a pathological feature of DLBCL-type LPD but not DLBCL, NOS. Thus, DLBCL-type LPD is pathologically different from DLBCL, NOS in MYC abnormalities. These factors may result in clinical differences, including therapy responses and clinical courses.

Keywords: MYC protein expression, MYC translocation, diffuse large B-cell lymphoma, iatrogenic immunodeficiency-associated lymphoproliferative disorder

INTRODUCTION

Diffuse large B-cell lymphoma, not otherwise specified (DLBCL, NOS) is a common type of aggressive B-cell non-Hodgkin's lymphoma and consists of a heterogeneous group of diseases.[1] c-MYC protein expression and gene translocation have been used as prognostic markers in DLBCL, NOS.[2,3] c-MYC locus translocation combined with other genetic abnormalities also affects the chromosomes of patients with lymphoma, thereby causing "double-hit" lymphoma. The prognosis of double-hit lymphomas is generally poor with a median overall survival of 0.2–1.5 years.[4–6] Several studies have indicated that patients with DLBCL, NOS with MYC rearrangement have a lower overall survival (OS) than do patients without MYC rearrangement[7]; therefore, MYC is absolutely necessary as a prognostic factor.

DLBCL, NOS is a heterogeneous diagnostic category. This disease develops through various mechanisms of oncogenic activation. It has different molecular subtypes and different gene expression patterns.[8] DLBCL, NOS is the most common subtype of non-Hodgkin lymphoma and requires cytotoxic chemotherapy. The 5-year progression-free period and OS rates of DLBCL, NOS are 60% and 65%, respectively, with rituximab plus cyclophosphamide, doxorubicin, vincristine, and prednisone (R-CHOP) therapy.[9] Spontaneous regression and remission of DLBCL, NOS is rare and has few reports to date. However, a unique characteristic of DLBCL-type iatrogenic immunodeficiency-associated lymphoproliferative disorders (DLBCL-type LPDs)—which can be classified as post-transplantation lymphoproliferative disorders (PTLDs) and other iatrogenic immunodeficiency-associated LPDs (OIIA-LPDs) [10]—is regression after immunosuppressive drug withdrawal. [11]

The most common iatrogenic immunodeficiency-associated LPD is methotrexate-associated LPD (MTX-LPD) in patients with rheumatoid arthritis. Previous reports[10,11] showed that the prevalence of DLBCL-type of MTX-LPD (an EBV-positive

subtype, not otherwise specified) regressed without relapse or a regrowth event with 50% of patients requiring additional chemotherapy and a survival rate of 97% for autoimmune disease, after the withdrawal of immunosuppressive drugs. The diagnosis of these diseases is not based on pathological differences, but is based on a history of autoimmune disease and the use of transplant-related immunosuppressive drugs. Therefore, the distinction between DLBCL-type LPD and DLBCL, NOS is based on clinical immunodeficiency rather than on histopathology.

We speculated that differences between DLBCL-type LPD and DLBCL, NOS exist in the immunodeficiency status and in the pathological findings, based on tumor biological etiologies. In particular, in DLBCL-type LPD, few reports exist on the expression and translocation of MYC, and its pathological features are unknown. We compared the clinicopathological features of DLBCL-type LPD and DLBCL, NOS, especially the MYC aberration status.

MATERIALS AND METHODS

Patients

Patients with PTLD/OIIA-LPD from whom lymph nodes, bone marrow, and tumors had been resected were selected retrospectively from the records of the Department of Pathology, Showa Medical University School of Medicine (Tokyo, Japan). In total, 25 patients were diagnosed with PTLD/OIIA-LPD in 2007–2017 (Table 1). These 25 patients were reviewed and 13 patients with DLBCL type LPD were selected by a hematopathologist. Thirty patients with DLBCL, NOS were selected for comparison, including patients diagnosed with EBV-positive DLBCL, NOS. The reason we selected DLBCL, NOS requiring R-CHOP-based chemotherapy for comparison was to histologically examine DLBCL-type

LPD, which can regress only with the discontinuation of immunosuppressive drugs. In addition, to compare the EBV positivity of DLBCL-type LPD and DLBCL, NOS, we included EBV-positive DLBCL, NOS in the DLBCL, NOS group. Therefore, we selected 30 consecutive cases of DLBCL, NOS at our institution, regardless of the EBV positivity status. Clinical information was obtained from the patients' clinical charts and attending physicians. We excluded patients with congenital immunodeficiency or human immunodeficiency virus infection. All patients underwent imaging studies with positron emission tomography and computed tomography to evaluate clinical staging.

PTLD is histopathologically categorized as (1) classic Hodgkin lymphoma (CHL)-type PTLD and (2) monomorphic PTLD B- and T-natural killer (NK) cell type. The histological findings of OIIA-LPD were categorized into the following six types, based on the World Health Organization (WHO) classification scheme[10]: (1) DLBCL, (2) CHL, (3) polymorphic LPD, (4) peripheral T-cell lymphoma, (5) follicular lymphoma, and (6) angioimmunoblastic T-cell lymphoma. This study was conducted in accordance with the Helsinki Declaration. The Research Ethics Committee at Showa University Hospital approved the protocol (approval number 2479).

Histology and immunohistochemistry

Excised tissue specimens were fixed in 10% formalin and embedded in paraffin wax. We cut serial 3-μm sections from the paraffin blocks and stained the sections with hematoxylin and eosin. Immunohistochemical (IHC) staining was performed by applying a panel of monoclonal antibodies to the formalin-fixed tumor samples. The antibody, dilution, clone, and source were as follows: CD3 (1:50, PS1; Leica, Newcastle upon Tyne, UK), CD5 (1:50, 4C7; Leica), CD10 (1:50, 56C6; Leica), CD15 (1:50, Carb-3; Dako, Glostrup, Denmark), CD20 (1:100, L26; Leica), CD30 (1:30, Ber-H2; Dako), BCL2 oncoprotein (1:50,

124; Dako), BCL6 oncoprotein (1:100, LN22, Leica), multiple myeloma oncogene 1 (MUM1) (1:50, MUM1p; Dako), cyclin D1 (1:100, DCS-6; Nichirei Biosciences Inc., Tokyo, Japan), c-MYC (1:200, Y69; Abcam plc, Cambridge, UK), and p53 protein (1:50, DO-7; Dako Cytomation), and Ki-67 (1:100, MIB-1; Dako). After conducting the heat-induced epitope retrieval procedure, IHC staining was performed by using an automated immunostainer (Histostainer 36 A; Nichirei Biosciences, Inc.) in accordance with the manufacturer's protocol.

Patients with DLBCL-type LPD and DLBCL, NOS were assigned to the germinal center B-cell-like (GCB) group or the non-GCB group, based on the classification method of Hans et al.[12] Hans subsequently reported that the immunohistochemical expression pattern of CD10, BCL6, and MUM1 can be used to categorize DLBCL-type LPD and DLBCL, NOS into the GCB and non-GCB phenotypes with an outcome similar to that predicted by cDNA microarray analysis. These studies showed a significantly better survival rate in patients with the GCB subtype of DLBCL, NOS than in patients with the non-GCB subtype. For the purpose of this study, a cut-off point of ≥50% was used for MYC because of the worst prognosis for patients with a high (i.e., ≥50%) MYC expression.[3]

In situ hybridization

Epstein–Barr encoding mRNA (EBER) was used in an autostainer (Bond-III; Leica Biosystems, Newcastle, UK) using a polymer-based detection system (Bond Polymer Refine Detection; Leica Biosystems) with an EBV-specific probe [Bond *in situ* hybridization (ISH) EBER probe] and 3,3′-diaminobenzidine (DAB) as the chromogen. We set the cut-off value for the positive expression of EBER at 20% or more of malignant cells.[13]

A dual-color break-apart rearrangement probe for LSI 8q24/*MYC* was purchased from Abbott Molecular, Inc. (Des Plaines, IL, USA). The probe set of 8q24/*MYC* consisted of

a mixture of a 407-kb spectrum green-labelled 3′*MYC* probe and a 277-kb spectrum orange-labelled 5′*MYC* probe that hybridizes to the 8q24 region. The fluorescence in situ hybridization (FISH) assays were performed, based on the manufacturer's instructions, with minor modifications. In brief, formalin-fixed paraffin-embedded tissue sections were deparaffinized with xylene, rehydrated in graded ethanol, pretreated at 98°C, digested with pepsin and hybridized with FISH probes at 37°C overnight. After staining with DAPI I, the stained slides were stored at 4°C. The FISH images were scanned and analyzed by using the Biozero all-in-one fluorescence microscope (BZ-8100; Keyence, Higashi-Yodogawa, Osaka, Japan). In FISH assays with the dual-color break-apart rearrangement probe, a cell without translocation typically has two fusion signals: green and red. A cell with the typical translocation contains a pair of signals: one green and one red. Fusion signals were counted for more than 200 cells.

RESULTS

No patient was diagnosed with congenital immunodeficiency or human immunodeficiency virus infection among the current cases. Table 1 summarizes the clinical and immunophenotypical findings of the PTLD and OIIA-LPD patients. Patients #22–#25 had no evidence of MTX use, based on a detailed analysis of their immunosuppressive history. However, the current WHO classification of OIIA-LPD is defined as "lymphocyte proliferation or lymphoma occurring in patients treated with immunosuppressive agents for an autoimmune disease or condition other than in the post-transplant setting."[10] We therefore selected them as cases.

Among 27 patients with PTLD and OIIA-LPD, 13 patients had DLBCL-type LPD (Table 2). Nineteen patients with DLBCL, NOS and eight patients with DLBCL-type LPD had positive Epstein–Barr encoding mRNA in situ hybridization (EBER-ISH) results. The

expression of MYC protein was positive in seven patients (Figure 1). The FISH analysis revealed that MYC was not rearranged in any patient (Figure 2).

Table 3 shows the comparisons of the histological findings between patients with DLBCL-type LPD and patients with DLBCL, NOS—especially in the histological subtype, expression of EBER-ISH in tumor cells, expression of MYC, and translocation of MYC.

With regard to histological subtypes, the non-GCB type was found in all patients with DLBCL-type LPD, but in 17 of 30 patients with DLBCL, NOS. The two disease groups differed significantly (100% for DLBCL-type LPD vs. 57% for DLBCL, NOS; p=0.003).

The expression of EBER-ISH in tumor cells was positive in 8 of 13 patients with DLBCL-type LPD but only 1 of 30 patients with DLBCL, NOS, non-GCB type. DLBCL-type LPD was more strongly associated with EBV infection than was DLBCL, NOS (62% vs. 3%, p<0.001).

MYC expression was positive in 7 of 13 patients with DLBCL-type LPD and in 9 of 21 patients with DLBCL, NOS, including three patients who had the GCB type, and six patients who had the non-GCB type. In the FISH analysis of MYC translocation, no patient was positive in the DLBCL-type LPD group, whereas 4 of 30 patients were positive in the DLBCL, NOS group, including one patient who had the GCB type, and three patients who had the non-GCB type. Overall, these results confirmed no significant difference existed in MYC expression between DLBCL-type LPD and DLBCL, NOS (54% vs. 30%, p=0.178), but we observed significant differences in MYC translocation between the two groups (0% [DLBCL-type LPD] vs. 13% [DLBCL-NOS], p=0.026).

DISCUSSION

We examined pathological factors, especially the histological subtype, the expression of EBER-ISH in tumor cells, the expression of MYC, and the translocation of MYC. These

factors have attracted attention as prognostic factors for DLBCL, NOS. No previous reports have focused on the pathological differences between DLBCL-type LPD and DLBCL, NOS.

Hans et al.[12] showed that DLBCL, NOS was divided into the GCB and non-GCB subtypes, which had a prevalence of 42% and 58%, respectively. However, a previous report[14] indicated that the GCB subtype of DLBCL, NOS was significantly less frequent than the non-GCB subtype in Asian countries, especially Japan (29% vs 71%, $p<0.001$). In our study, the cases of DLBCL-type LPDs were all of the non-GCB type. However, in a previous review,[15] approximately two-thirds of large B-cell type MTX-LPD cases were of the non-GCB type. All patients with DLBCL-type LPDs in the present study had a background of immunosuppressive treatment for autoimmune diseases or organ transplant, based on a detailed medical history. However, the population in previous studies had MTX-related DLBCL, which suggests that the results may have differed from those of our study. The finding of the predominance of non-GCB type in DLBCL type LPD suggested that it is derived from activated B lymphocytes, which is consistent with a background of immunodeficiency due to the use of immunosuppressants. This feature is a clear pathological difference from DLBCL, NOS, including the GCB type, in approximately one-half of cases, which derived from peripheral mature B-cell of germinal center origin. Previous reports[12] have shown that the GCB group was superior to the non-GCB group in the 5-year OS of DLBCL, NOS. However, recent analysis has suggested that the addition of bortezomib, lenalidomide, and ibrutinib chemotherapy to R-CHOP is effective for treating DLBCL, NOS of the non-GCB subtype,[16,17] and that the outcomes with standard chemotherapy and R-CHOP are lower in non-GCB than in GCB DLBCL.[18] DLBCL-type LPD, which has a high percentage of non-GCB types, regresses and goes into remission after immunosuppressants are discontinued. It may be more responsive than DLBCL, NOS, which requires chemotherapy, and may offer a better prognosis.[11]

EBV-positive DLBCL, NOS involves EBV-positive clone B-cell lymphocyte proliferation. It is an independent disease category and tends to occur in older patients, and seems to be associated with immunosenescence.[9] This study showed that EBER-ISH positivity was detected in 61% and 3% of DLBCL-type LPD patients and DLBCL, NOS patients, respectively. The higher ratio of EBV positivity in DLBCL-type LPD suggested that it is similar to EBV-positive DLBCL, NOS rather than EBV-negative DLBCL, NOS with regard to the status of EBV infection. Therefore, EBV positivity may reflect immunodeficiency backgrounds, not specific etiologies, in these diseases.

C-MYC protein expression and gene translocation have been used as prognostic markers in DLBCL, NOS. However, MYC expression and translocation in DLBCL-type LPD has not been reported, and its pathological features are unclear. Double-expressor lymphoma is defined as the overexpression of MYC and BCL2 proteins, independent of the underlying chromosomal rearrangement.[19,20] In this study, no significant difference in MYC expression existed between DLBCL-type LPD and DLBCL, NOS. We propose that the lack of a significant difference in MYC expression indicated that MYC expression is defined by various MYC abnormalities such as amplification and translocations. Some DLBCL, NOS diseases are MYC driven and defined as a double-hit or triple-hit lymphoma with BCL2 and/or BCL6 rearrangements. MYC translocation is an important prognostic factor in DLBCL, NOS.[21,22] In high grade B-cell lymphoma (HGBL) with MYC and BCL2 and/or BCL6 rearrangement, the overall response rate with standard chemotherapy is shorter than that of DLBCL, NOS without MYC.[23] Furthermore, patients with double-hit HGBL have poorer outcomes than do patients with HGBL and NOS with no MYC rearrangement.[24,25] Patients with DLBCL, NOS inadequately respond to standard chemotherapy regimens such as R-CHOP and they have a very poor prognosis[26]; therefore, the identification of MYC translocations is important in clinical practice.

Current clinical trials are investigating bortezomib, lenalidomide, and ibrutinib as novel agents to add to the R-CHOP regimen. The appropriate selection and randomization of DLBCL, NOS patients in these trials requires predictors, based on tumor biology, of which MYC translocation is an important factor.[27] An interesting finding in our analysis of MYC translocations was that no translocation occurred in DLBCL-type LPD patients, whereas translocations occurred in 10%–15% of DLBCL, NOS patients. The difference was significant. The images of both types show the same DLBCL tissue type, but with different treatment concepts (R-CHOP vs. MTX discontinuation) and responses (5-year survival: 50% with R-CHOP vs. 80% with MTX discontinuation alone) for MYC translocation with pathological genetics supporting clinical features.

In this study, the expression of MYC proteins was not statistically significantly different between DLBCL-type LPD and DLBCL, NOS (53% vs. 30%), and no case of DLBCL-type LPD with MYC translocation occurred. Lack of MYC translocation is a pathological feature of DLBCL-type LPD that distinguishes it from DLBCL, NOS. This pathological difference between the diseases may be associated with differences in the response to chemotherapy and in their prognosis.

In conclusion, this study revealed that DLBCL-type LPD is pathologically different from DLBCL, NOS with regard to MYC abnormalities, status of EBV infection, and histological subtype of GCB type/non-GCB type. The impact and relevance of MYC expression and translocation on the outcome of DLBCL-type LPD need to be investigated in more cases in the future. Highly accurate studies are expected to reveal differences in treatment efficacy and in the clinical course through the analysis of cases.

ACKNOWLEDGEMENTS

We express our grateful thanks to Yosuke Sasaki for the technical assistance in IHC staining and FISH analyses.

CONFLICT OF INTEREST

The authors declare no conflict of interest.

REFERENCES

1. Smith A, Roman E, Howell D, et al. The Haematological Malignancy Research Network (HMRN):a new information strategy for population based epidemiology and health service research. Br J Haematol. 2010; 148:739-753.
2. Yan LX, Liu YH, Luo DL, et al. MYC expression in concert with BCL2 and BCL6 expression predicts outcome in Chinese patients with diffuse large B-cell lymphoma, not otherwise specified. PLoS One. 2014; 9:1-16.
3. Perry AM, Alvarado-Bernal Y, Laurini JA, et al. MYC and BCL2 protein expression predicts survival in patients with diffuse large B-cell lymphoma treated with rituximab. Br J Haematol. 2014; 165:382-391.
4. Oki Y, Noorani M, Lin P, et al. Double hit lymphoma: The MD Anderson Cancer Center clinical experience. Br J Haematol. 2014; 166:891-901.
5. Bertrand P, Maingonnat C, Ruminy P, et al. Comment to: The clinical presentation and prognosis of diffuse large B-cell lymphoma with t(14; 18) and 8q24/c-MYC rearrangement. Haematologica 2007; 92: 1335-1342. Haematologica. 2008;93:e53.
6. Hasserjian RP, Zukerberg LR, Jeremy S. Rearrangements are aggressive neoplasms with clinical and pathologic features distinct from Burkitt lymphoma and diffuse large B-cell lymphoma. Am J Surg Pathol. 2010; 34:327-340.
7. Rosenwald A, Bens S, Advani R, et al. Prognostic significance of *MYC* rearrangement and translocation partner in diffuse large B-cell lymphoma: a study by the Lunenburg Lymphoma Biomarker Consortium. J Clin Oncol. 2019; 37:3359-3368.
8. Destefano CB, Desai SH, Shenoy AG, et al. Management of post-transplant lymphoproliferative disorders. Br J Haematol. 2018; 182:330-343.
9. Park S, Lee J, Ko Y, et al. The impact of Epstein-Barr virus status on clinical outcome in diffuse large B-cell lymphoma. Blood. 2007; 110:972-978.

10. Gaulard P, Swerdlow SH, Harris NL, et al. Other iatrogenic immunodeficiency associated lymphoproliferative disorders. In: Swerdlow SH, Campo E, Harris NL, et al. (eds): WHO Classification of Tumours of Haematopoietic and Lymphoid Tissues, Revised 4th Ed., Lyon, International Agency for Research on Cancer. 2017; pp. 462-464.

11. Tokuhira M, Tamaru J, Kizaki M. Clinical management for other iatrogenic immunodeficiency-associated lymphoproliferative disorders. J Clin Exp Hematop. 2019; 59:72-92.

12. Hans CP, Weisenburger DD, Greiner TC, et al. Confirmation of the molecular classification of diffuse large B-cell lymphoma by immunohistochemistry using a tissue microarray. Blood. 2004; 103:275-282.

13. Sehn LH, Gascoyne RD. Diffuse large B-cell lymphoma: optimizing outcome in the context of clinical and biologic heterogeneity. Blood. 2015; 125:22-32.

14. Shiozawa E, Yamochi-Onizuka T, Takimoto M, Ota H. The GCB subtype of diffuse large B-cell lymphoma is less frequent in Asian countries. Leuk Res. 2007; 31:1579-1583.

15. Momose S, Tamaru J. Iatrogenic immunodeficiency-associated lymphoproliferative disorders of B-cell type that develop in patients receiving immunosuppressive drugs other than in the post-transplant setting. J Clin Exp Hematop. 2019; 59:48-55.

16. Dunleavy K, Pittaluga S, Czuczman MS, et al. Differential efficacy of bortezomib plus chemotherapy within molecular subtypes of diffuse large B-cell lymphoma. Blood. 2009; 113:6069-6076.

17. Wilson WH, Young RM, Schmitz R, et al. Targeting B cell receptor signaling with ibrutinib in diffuse large B cell. Nat Med. 2015; 21:922-926.

18. Meyer PN, Fu K, Greiner TC, et al. Immunohistochemical methods for predicting cell

of origin and survival in patients with diffuse large B-cell lymphoma treated with rituximab. J Clin Oncol. 2011; 29:200-207.

19. Riedell PA, Smith SM. Double hit and double expressors in lymphoma: definition and treatment. Cancer. 2018; 124:4622-4632.

20. Swerdlow SH, Campo E, Pileri SA, et al. The 2016 revision of the World Health Organization classification of lymphoid neoplasms. Blood. 2016; 127:2375-2390.

21. Barrans S, Crouch S, Smith A, et al. Rearrangement of MYC is associated with poor prognosis in patients with diffuse large B-Cell lymphoma treated in the era of rituximab not known. J Clin Oncol. 2010; 28:3360-3365.

22. Tzankov A, Xu-monette ZY, Gerhard M, et al. Rearrangements of MYC gene facilitate risk stratification in diffuse large B-cell lymphoma patients treated with rituximab-CHOP. Mod Pathol. 2014; 27:958-971.

23. Tomita N. BCL2 and MYC dual-hit lymphoma/leukemia. J Clin Exp Hematop. 2011; 51:7-12.

24. Cook JR, Goldman B, Tubbs RR, et al. Clinical significance of MYC expression and/or “high-grade” morphology in non-Burkitt, diffuse aggressive B-cell lymphomas: a SWOG S9704 correlative study. Am J Surg Pathol. 2014; 38:494-501.

25. Perry AM, Crockett D, Dave BJ, et al. B-cell lymphoma, unclassifiable, with features intermediate between diffuse large B-cell lymphoma and Burkitt lymphoma: study of 39 cases. Br J Haematol. 2013; 162:40-49.

26. Aukema SM, Siebert R, Schuuring E, et al. Double-hit B-cell lymphomas. Blood. 2011; 117:2319-2331.

27. Vaidya R, Witzig TE. Prognostic factors for diffuse large B-cell lymphoma in the R(X)CHOP era. Ann Oncol. 2014; 25:2124-2133.

Table 1. Clinicopathological findings of 25 patients with PTLD and OIIALPD

Patient	Disease category	Sex	Age (y)	History of primary disease	Immunosuppressive agent/therapy	Number of sites	Biopsy site	Histology
1	PTLD	M	58	ALL	CBT	1	BM	CHL
						2	LN	CHL
						3	LN	CHL
2	PTLD	M	43	Kidney transplantation	CsA, MMF		Brain	DLBCL
3	PTLD	F	42	Kidney transplantation	TAC, PSL		Pleural	DLBCL
4	OIIALPD	F	77	RA	MTX		LN	CHL,MC
5	OIIALPD	F	81	RA	MTX		Adrenal glands	DLBCL
6	OIIALPD	M	74	RA	MTX		LN	AITL
7	OIIALPD	M	68	RA	MTX		LN	CHL,MC
8	OIIALPD	F	70	RA	MTX		LN	DLBCL
9	OIIALPD	M	65	RA	MTX		LN	CHL
10	OIIALPD	F	67	RA	MTX		Oral mucosa	LPD
11	OIIALPD	F	60	RA	MTX		Tonsil	DLBCL
12	OIIALPD	F	78	RA	MTX		LN	DLBCL
13	OIIALPD	F	75	RA	MTX		LN	CHL
14	OIIALPD	F	67	RA	MTX		Gums	DLBCL
15	OIIALPD	F	81	RA	MTX		Pharynx	DLBCL
16	OIIALPD	M	76	RA	MTX		LN	LPD
17	OIIALPD	F	84	RA	MTX, SASP		LN	FL,grade3
18	OIIALPD	F	84	RA	MTX, SASP		Lung	DLBCL
19	OIIALPD	F	84	RA	MTX, TAC		BM	LPD
20	OIIALPD	M	76	RA	MTX+PSL, BUC, ETN		LN	CHL,NS

21	OIIALPD	F	82	RA	PSL, SASP, BUC, MTX, TAC		Lung	DLBCL
22	OIIALPD	M	56	RA	BUC, SASP, PSL		LN	DLBCL
23	OIIALPD	M	69	RA	D-Pc, PSL		Mediastinum	DLBCL
24	OIIALPD	F	79	MCTD	PSL, TAC		LN	DLBCL
25	OIIALPD	M	69	SLE	PSL, TAC	1	Skin	PTCL,NOS
						2	LN	PTCL,NOS

PTLD, post-transplant lymphoproliferative disorder; OIIALPD, other iatrogenic immunodeficiency associated lymphoproliferative disorder; M, male; ALL, acute lymphoid leukemia; CBT, cord blood transplantation; BM, bone marrow; CHL, classic Hodgkin lymphoma; LN, lymphoid node; CsA, cyclosporin A; MMF, mycophenolate mofetil; DLBCL, diffuse large B-cell lymphoma; F, female; TAC, tacrolimus; PSL, prednisolone; RA, rheumatoid arthritis; MTX, methotrexate; MC, mixed cellularity; AITL, angioimmunoblastic T-cell lymphoma; LPD, lymphoproliferative disorder; SASP, salazosulfapyridine; FL, follicular lymphoma; BUC, bucillamine; ETN, etanercept; D-Pc, D-penicillamine; MCTD, mixed connective tissue disease; SLE, systemic lupus erythematosus; PTCL, peripheral T-cell lymphoma; NOS, not otherwise specified

Table 2. Clinicopathological findings of 13 patients with DLBCL-type LPD

Patient	Disease category	Sex	Age	Histology	EBV	CD20	CD3	CD5	CD10	CD30	BCL2	BCL6	MUM1	Cyclin D1	Ki67 (%)	MYC (%)	MYC translocation
2	PTLD	M	43	DLBCL, non-GCB	+	+	-	-	-	+(p)	NA	NA	NA	NA	NA	0	0
3	PTLD	F	42	DLBCL, non-GCB	+	+	-	-	-	+(p)	-	-	+	NA	90	60	0
5	OIILPD	F	81	DLBCL, non-GCB	-	+	-	-	-	-	+	-	+	-	70	50	0
8	OIILPD	F	70	DLBCL, non-GCB	-	+	-	-	-	-	+	+	+	-	60	20	0
11	OIILPD	F	60	DLBCL, non-GCB	+	+	-	-	-	+	+	-	NA	-	80	30	0
12	OIILPD	F	78	DLBCL, non-GCB	+	+	-	-	-	-	+	-	-	-	65	50	0
14	OIILPD	F	67	DLBCL, non-GCB	+	+	-	-	-	+	-	-	+	-	90	20	NA
15	OIILPD	F	81	DLBCL, non-GCB	+	+	-	NA	-	+	NA	-	+	NA	NA	50	0
18	OIILPD	F	84	DLBCL, non-GCB	+	+	-	-	-	+(p)	+(p)	-	+	NA	80	20	0
21	OIILPD	F	82	DLBCL, non-GCB	+	+	-	-	-	+(p)	+(p)	-	+	-	80	30	NA
22	OIILPD	M	56	DLBCL, non-GCB	Δ	+	-	-	-	+	+	-	+	-	75	50	0
23	OIILPD	M	69	DLBCL, non-GCB	-	+	+	+	-	-	-	+	+	-	70	50	0

24	OIILPD	F	79	DLBCL, non-GCB	-	+	-	-	-	-	+	-	+	-	60	60	0

DLBCL type LPD, diffuse large b-cell lymphoma-type iatrogenic immunodeficiency-associated lymphoproliferative disorder; PTLD, post-transplant lymphoproliferative disorder; OIIALPD, other iatrogenic immunodeficiency associated lymphoproliferative disorder; +(p), partial positive; GCB, germinal center B-cell-like; NA, not available

The triangle (△) indicates that Epstein–Barr encoding mRNA (EBER)-positive cells, but not tumor cells, were in the background.

Table 3. Comparison of DLBCL type LPD versus DLBCL, NOS patients' histological findings

	DLBCL type LPD		DLBCL, NOS (EBV+/-)			
	N=13	(%)	N=30		(%)	p
Histological subtype			GCB	non-GCB		
GCB	0	0	13		43	0.003
non-GCB	13	100		17	57	
EBER-ISH (tumor cells)						
positive	8	62	0	1	3	<0.001
negative	5	38	13	16	97	
c-MYC expression						
positive	7	54	3	6	30	0.178
negative	6	46	10	11	70	
c-MYC translocation						
positive	0	0	1	3	13	0.026
negative	11	85	3	2	17	
not available	2	15	9	12	70	

DLBCL type LPD, diffuse large b-cell lymphoma-type iatrogenic immunodeficiency-associated lymphoproliferative disorders; DLBCL, NOS, diffuse large b-cell lymphoma, not otherwise specified; EBV, Epstein-Barr virus; GCB, germinal center B-cell-like; EBER-ISH, Epstein–Barr encoding mRNA in situ hybridization

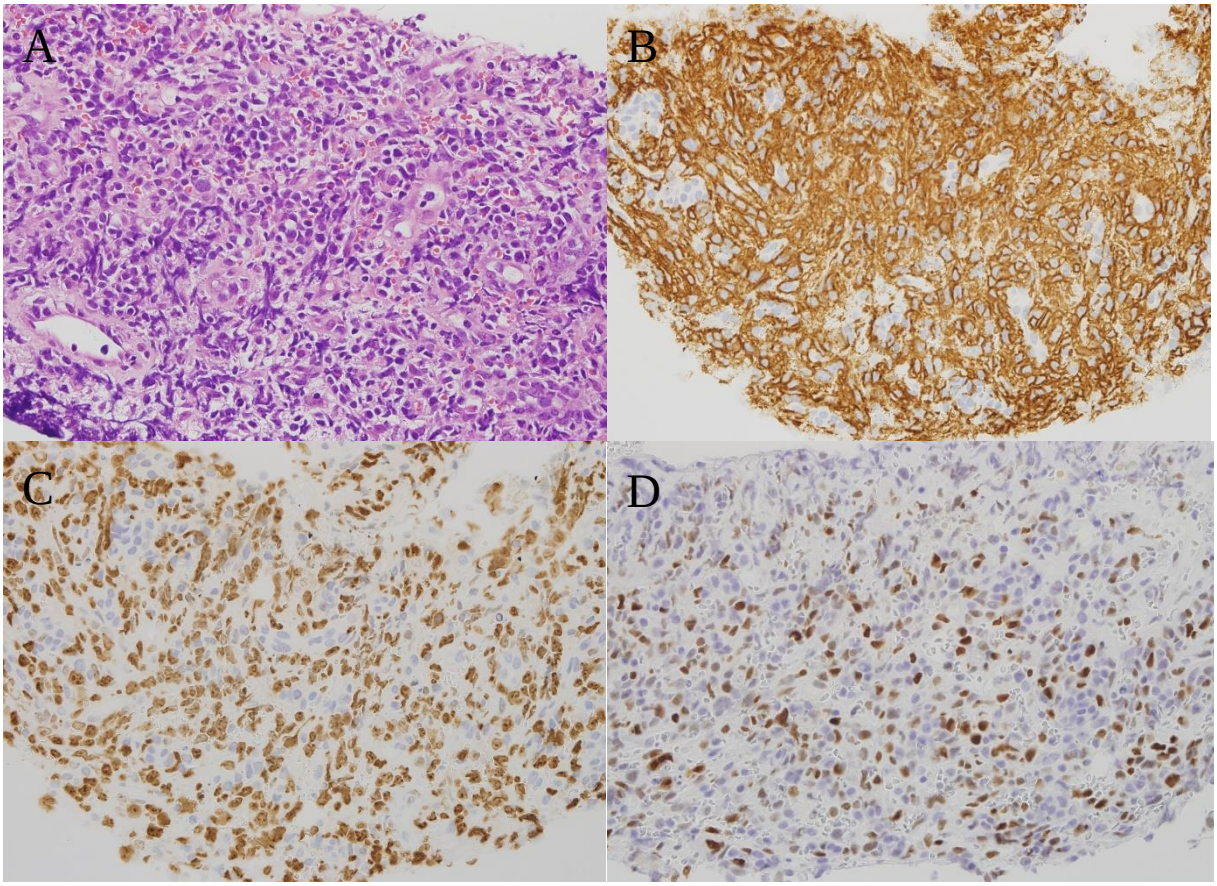

Fig. 1. Histological findings of a patient with DLBCL (Case 18). (***A***) Diffuse infiltration of lymphoid cells on the lymphoid node (hematoxylin and eosin stain). The tumor cells show (***B***) immunohistochemical positivity for the B-cell marker L26 and (***C***) high expression of Ki-67. (***D***) Approximately 60% of tumor cells express MYC.

DLBCL, diffuse large B-cell lymphoma

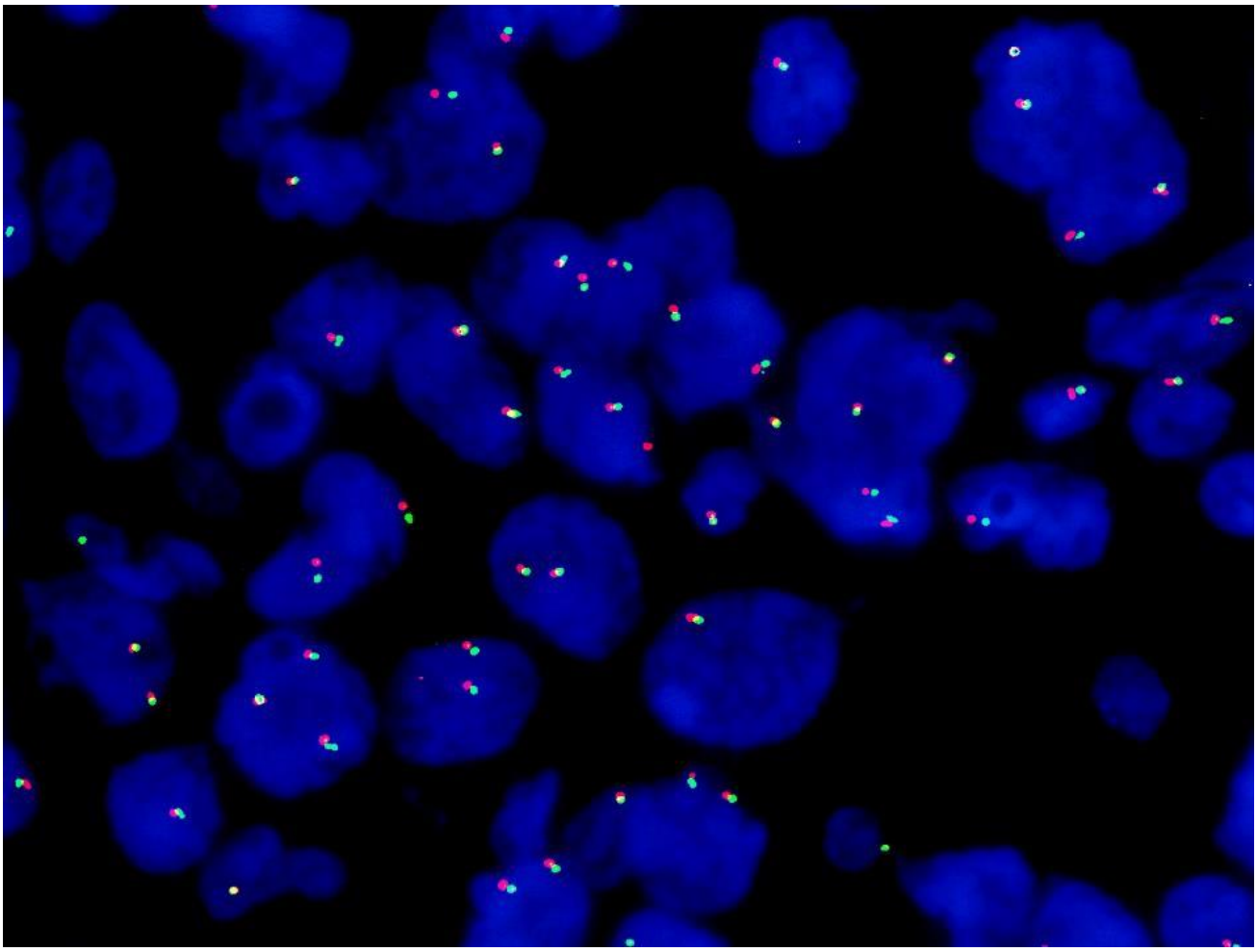

Fig. 2. Fluorescence *in situ* hybridization (FISH) analysis shows MYC expression in the cells of a patient with DLBCL (case 18). A dual-color signal is not present.