

Case Report

Complete Response Using Sorafenib Monotherapy for Advanced Hepatocellular Carcinoma with Multiple Lymph Node and Bone Metastases: A Case Report

Norihiro NOMURA*, Takayoshi ITO, Hiroki SHINOHARA,
Nobukazu SHIMA, Masashi SATOU, Dai SAKUMA,
Junichi EGUCHI, Naoyuki URAGAMI, Yoshio DEGUCHI,
Noboru YOKOYAMA and Haruhiro INOUE

Abstract : Hepatocellular carcinoma (HCC) is the sixth most commonly diagnosed cancer worldwide. Sorafenib is an oral multikinase inhibitor used in the palliative treatment of advanced HCC. However, there were no reported cases of complete response (CR) from two previous large phase III clinical trials. Here, we report a case of CR in a patient with advanced HCC with multiple lymph node and bone metastases, treated with sorafenib monotherapy for 8 months. To our knowledge, this is the first evidence showing CR following sorafenib monotherapy for HCC with bone metastasis.

Key words : sorafenib, hepatocellular carcinoma, complete response, bone metastasis

Introduction

Hepatocellular carcinoma (HCC) is the sixth most commonly diagnosed cancer and the fourth leading cause of cancer-related mortality¹⁾. The majority of HCC patients present with advanced and multifocal disease at the time of diagnosis, with a median survival of less than 6 months. Satisfactory outcomes have not been achieved by traditional treatment of advanced HCC using conventional antineoplastic drugs^{2,3)}. Sorafenib, a multi-target tyrosine kinase inhibitor used in the palliative treatment of advanced HCC, was shown to improve patient survival in two randomized, double-blind, placebo-controlled trials: the Sorafenib HCC Assessment Randomized Protocol (SHARP) trial and a trial conducted in the Asia-Pacific region^{4,5)}. However, neither study reported complete response (CR) to treatment. Here, we present a case of a 67-year-old man with HCC with multiple lymph node and bone metastases who achieved CR following treatment using sorafenib monotherapy for 8 months.

Case report

This report involves a 67-year-old Japanese man with known hypertension and hyperuricemia, who was diagnosed with liver injury and hepatitis C virus infection, which he chose not to treat, during a medical examination in 2006.

Digestive Diseases Center, Showa University Koto Toyosu Hospital, 5-1-38 Toyosu, Koto-ku, Tokyo 135-8577, Japan.

* To whom corresponding should be addressed.

In 2009, he presented with general malaise and sought treatment. Upon examination, computed tomography (CT) revealed a 37-mm HCC at segment 5 (S5) of the liver; hence, he subsequently underwent partial hepatectomy. Histopathological examination revealed moderately differentiated HCC with chronic hepatitis (New-Inuyama F3/A2). His resection stump was negative. Two years post-partial hepatectomy, he was treated using pegylated interferon (IFN) α -2b and ribavirin therapy for 48 weeks and achieved a sustained virological response. However, in July 2012, CT showed multiple new HCCs (four locations: S3 and S5) in both lobes. Recurrence of the S5 HCC was also determined. The S3 and S5 HCCs were treated using enucleation, while the others were treated with radiofrequency ablation.

In March 2013, CT showed multiple lymph node metastases around the liver. Three months later, he also exhibited a 12-mm local recurrence around the S5 operation site along with multiple bone metastases located within the cervical spine (C3), thoracic spine (Th4), and lumbar spine (L1, L2, L4, and L5), identified using magnetic resonance imaging (Fig. 1). The patient, however, was asymptomatic. His Child-Pugh score was A and his Eastern Cooperative Oncology Group performance status was 0. His α -fetoprotein (AFP) levels were 57 ng/ml and his protein induced by vitamin K absence or antagonist (PIVKA II) was 57 mAU/ml.

Conventional transcatheter arterial chemoembolization was initially performed for the local recurrence at the S5 operation site. In August 2013, sorafenib monotherapy was initiated with a dose of 400 mg orally once daily due to the patient's low body mass index of 17.3 kg/m². Three weeks later, a dose reduction (200 mg once daily) was necessary due to grade 3 hand-foot syndrome (HFS), based on the Common Terminology Criteria for Adverse Events (version

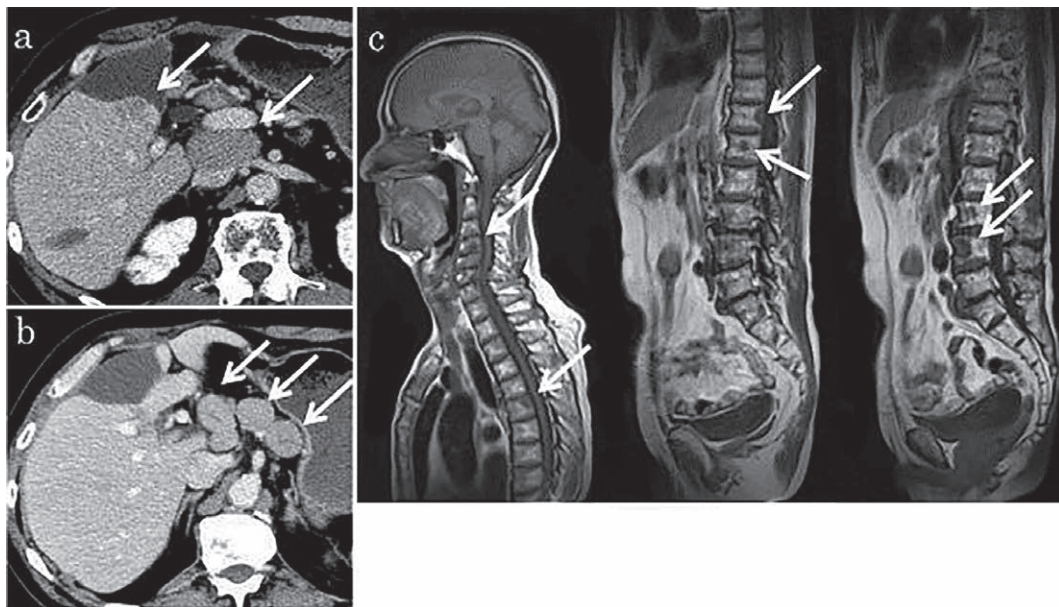


Fig. 1. Baseline abdominal computed tomography (a, b), and whole-spine magnetic resonance imaging (c). Arrows show recurrence of hepatocellular carcinoma (12 mm) around the segment 5 operation site and multiple lymph node metastases around the liver (a, b), and multiple bone metastases in the spine (C3, Th4, L1, L2, L4 and L5).

4.0). Seven weeks later, he presented with acute cholangitis, that was treated and controlled by antibiotics (Fig. 2), during which sorafenib was temporarily discontinued. Approximately one month later (3 months after initialization of treatment), sorafenib was resumed at a dose of 200 mg every other day. During this time, tumor markers decreased to normal levels (AFP, 3.8 ng/ml; PIVKA II 33 mAU/ml). After one month, his condition was continuously stable, therefore, the dose was increased to 200 mg per day. In April 2014 (after 8 months), upon magnetic resonance imaging, the previously identified masses had disappeared, judged to be CR by the Response Evaluation Criteria in Solid Tumors (Fig. 3). Since then, the patient continued

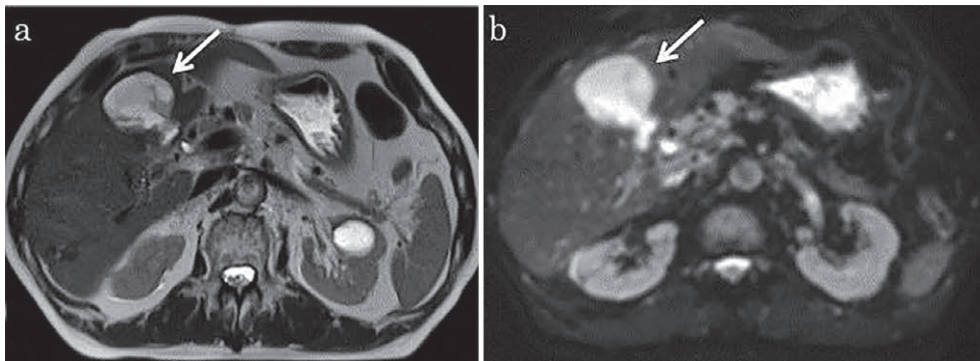


Fig. 2. Abdominal magnetic resonance imaging after 7 weeks of treatment. T2-weighted image (a) and diffusion image (b). Arrows show the segment 5 operation site with acute cholangitis that improved well with antibiotics.

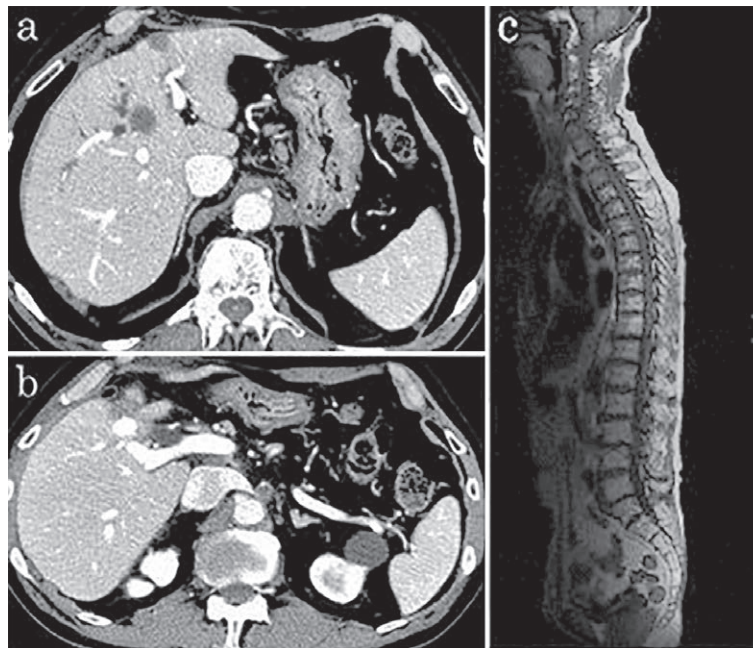


Fig. 3. Abdominal computed tomography (a, b) and whole-spine magnetic resonance imaging (c) after 8 months of treatment. There was no evidence of hepatocellular carcinoma recurrence around the segment 5 operation site (a), and multiple lymph node (b) and bone (c) metastases had disappeared.

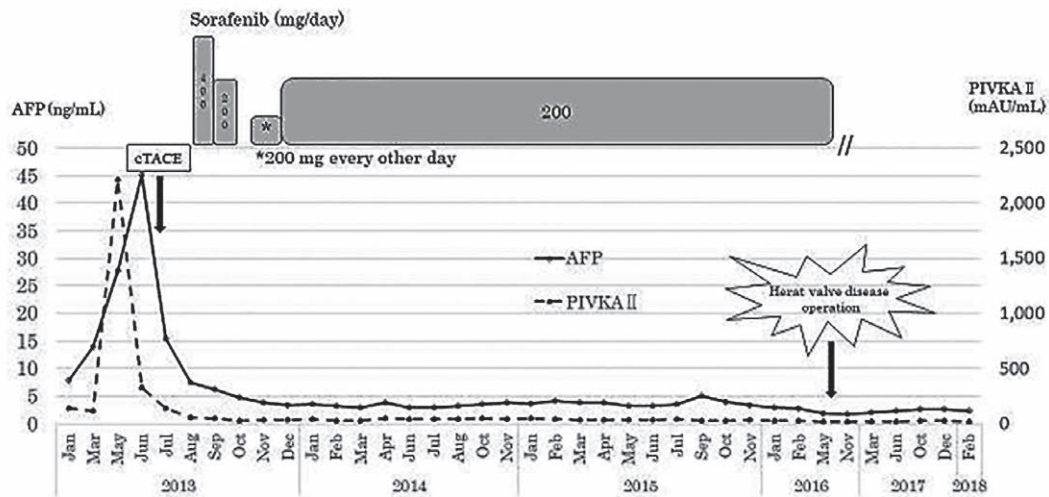


Fig. 4. Changes in α -fetoprotein (AFP) and protein induced by vitamin K absence or antagonist (PIVKA II) levels. The duration of treatment with sorafenib is indicated by the gray bars. cTACE, conventional transcatheter arterial chemoembolization.

treatment. However, in May 2016, the treatment was interrupted as a result of a surgical procedure for heart valve disease. As of February 2018, he is in a continuous CR state with no medications being taken (Fig. 4).

Discussion

Sorafenib is the only multikinase inhibitor that blocks receptor tyrosine kinases, such as vascular endothelial growth factor receptor and platelet-derived growth factor receptor, as well as RAF serine/threonine kinases along the RAF/MEK/ERK pathway⁶). Thus, sorafenib targets both tumor cell proliferation and angiogenesis.

The efficacy of sorafenib has been demonstrated in two multicenter, phase III, double-blind, placebo-controlled trials. The SHARP trial looked at over 600 patients with advanced HCC and Child-Pugh A cirrhosis, previously untreated with systemic therapy. The trial randomized patients to sorafenib 400 mg twice daily or placebo. Among patients treated with sorafenib, only seven (2%) were considered responders according to the Response Evaluation Criteria in Solid Tumors. The study was stopped early when results revealed a longer overall median survival for patients treated with sorafenib versus placebo (10.7 vs. 7.9 months; hazard ratio, 0.69; $P < 0.001$) with a 31% relative reduction in risk of death⁴). Similar results were found in a second phase III clinical study carried out in the Asia-Pacific region (3.3% partial response; overall survival with sorafenib vs. placebo, 6.2 vs. 4.1 months; hazard ratio, 0.67, $P < 0.016$)⁵). However, no CRs were reported in the second study.

A nationwide survey conducted in Japan reported 18 cases of CR after sorafenib in patients with advanced HCC, among 3,047 patients (CR rate, 0.6%)⁷). Other studies conducted in Korea, Spain, and Italy showed CR rates of 1.3% (7 of 523), 1.1% (12 of 1,119), and 1.1% (3 of 278), respectively⁸⁻¹⁰). It should be noted however, that there were no reports of bone metastases

in CR cases from any study. A literature search of case reports revealed only 2 HCC patients with bone metastases who achieved CR with sorafenib therapy in combination with a different agent^{11,12}. The first case was a 64-year-old man with hepatitis B virus infection, who developed bone metastases 9 months after resection of HCC. Sorafenib therapy plus zoledronic acid was initiated. The patient achieved CR after 15 months of therapy and there was no sign of recurrence 12 months following treatment cessation. Regarding toxicity, the patient developed a grade 2 HFS reaction that required a temporary 50% dose reduction of sorafenib¹¹. The second case was a 60-year-old man who developed extrahepatic metastases in bone, peritoneum, and lymph nodes after hepatectomy for HCC. As a pretreatment for sorafenib, the patient was treated using a combination therapy of oral fluoropyrimidine anticancer agent S-1, IFN, and zoledronic acid; however, it was a progressive disease. Therefore, the patient was treated with sorafenib (800 mg/day) but developed a grade 3 HFS reaction. He continued to be treated with sorafenib at a very low dose (200–400 mg/week) plus denosumab. The response to combination therapy was graded as CR achieved at 6 months. Sorafenib was continued for 8 months and the patient remained in CR for 11 months¹².

Bone metastasis leads to skeletal-related events, including pathologic fractures, a need for radiation or surgical treatment, and spinal cord compression, all of which impair the patient's quality of life. Clinical studies have shown that bone-modifying agents such as zoledronic acid and denosumab can reduce the incidence of skeletal-related events^{13–15}. The first case involved combination therapy with zoledronic acid. Katamura *et al*¹³ reported that zoledronic acid delayed the progression of bone metastases from HCC. The second case involved combination therapy using denosumab. Surprisingly, in this case, the dose of sorafenib was very low. Nakano *et al*¹² proposed that either sorafenib or denosumab produced an effective response for bone metastases, and a late response to IFN was possible. In any event, these two cases did not use monotherapy, but used combination therapy instead. Sorafenib monotherapy was used in our case due to the patient's request of not using a bone-modifying agent for his treatment. To our knowledge, this represents the first evidence of CR to sorafenib monotherapy for HCC with bone metastases. It is well known that bone-modifying agents are effective, and we believe that bone-modifying agents should be used in combination with sorafenib for similar cases of bone metastases in the future.

In our case, we started sorafenib monotherapy at a half-dose of 400 mg/day due to the patient's age of 67 years and a slender body type (body mass index of 17.3 kg/m²). Despite a decrease in the initial dosage, our patient still experienced adverse events; therefore, the dose was further reduced. At 3 months after initialization of treatment, by continuing low-dose treatment, the patient's AFP normalized, and CR was achieved by 8 months. He maintained a CR state for more than 2 years without any new adverse events. After 31 months, treatment was discontinued as a result of a surgical procedure for heart valve disease. To date, 22 months after discontinuation, he still maintains a CR state.

In summary, we report the first case of CR in a patient with advanced HCC with multiple lymph node and bone metastases treated with sorafenib monotherapy for 8 months.

Conflict of interest disclosure

All authors have no conflicts of interest to declare.

Patient consent

Obtained.

References

- 1) Ferlay J, Shin HR, Bray F, *et al*. Estimates of worldwide burden of cancer in 2008: GLOBOCAN 2008. *Int J Cancer*. 2010;**127**:2893–2917.
- 2) Lopez PM, Villanueva A, Llovet JM. Systemic review: evidence-based management of hepatocellular carcinoma—an updated analysis of randomized controlled trials. *Aliment Pharmacol Ther*. 2006;**23**:1535–1547.
- 3) Nowak AK, Chow PK, Findlay M. Systemic therapy for advanced hepatocellular carcinoma: a review. *Eur J Cancer*. 2004;**40**:1474–1484.
- 4) Llovet JM, Ricci S, Mazzaferro V, *et al*. Sorafenib in advanced hepatocellular carcinoma. *N Engl J Med*. 2008;**359**:378–390.
- 5) Cheng AL, Kang YK, Chen Z, *et al*. Efficacy and safety of sorafenib in patients in the Asia-Pacific region with advanced hepatocellular carcinoma: a phase III randomised, double-blind, placebo-controlled trial. *Lancet Oncol*. 2009;**10**:25–34.
- 6) Wilhelm SM, Carter C, Tang L, *et al*. BAY 43-9006 exhibits broad spectrum oral antitumor activity and targets the RAF/MEK/ERK pathway and receptor tyrosine kinases involved in tumor progression and angiogenesis. *Cancer Res*. 2004;**64**:7099–7109.
- 7) Shiba S, Okusaka T, Ikeda M, *et al*. Characteristics of 18 patients with hepatocellular carcinoma who obtained a complete response after treatment with sorafenib. *Hepatol Res*. 2014;**44**:1268–1276.
- 8) Park JG. Long-term outcomes of patients with advanced hepatocellular carcinoma who achieved complete remission after sorafenib therapy. *Clin Mol Hepatol*. 2015;**21**:287–294.
- 9) Rimola J, Diaz-Gonzalez A, Damell A, *et al*. Complete response under sorafenib in patients with hepatocellular carcinoma: relationship with dermatologic adverse events. *Hepatology*. 2017;**67**:612–622.
- 10) D’Angelo S, Germano D, Zolfino T, *et al*. Therapeutic decisions and treatment with sorafenib in hepatocellular carcinoma: final analysis of GIDEON study in Italy. *Recenti Prog Med*. 2015;**106**:217–226. (in Italian).
- 11) Natori T, Yamaguchi M. Complete response after sorafenib therapy plus zoledronic acid for advanced hepatocellular carcinoma with bone metastasis: a case report. *Gan To Kagaku Ryoho*. 2013;**40**:635–637. (in Japanese).
- 12) Nakano N, Kawaoka T, Aikata H, *et al*. Complete response to short-term sorafenib treatment alone for hepatocellular carcinoma with bone, lymph node and peritoneum metastasis. *Hepatol Res*. 2016;**46**:1402–1408.
- 13) Katamura Y, Aikata H, Hashimoto Y, *et al*. Zoledronic acid delays disease progression of bone metastases from hepatocellular carcinoma. *Hepatol Res*. 2010;**40**:1195–1203.
- 14) Stopeck AT, Lipton A, Body JJ, *et al*. Denosumab compared with zoledronic acid for the treatment of bone metastases in patients with advanced breast cancer: a randomized, double-blind study. *J Clin Oncol*. 2010;**28**:5132–5139.
- 15) Fizazi K, Carducci M, Smith M, *et al*. Denosumab versus zoledronic acid for treatment of bone metastases in men with castration-resistant prostate cancer: a randomised, double-blind study. *Lancet*. 2011;**377**:813–822.

[Received July 17, 2019 : Accepted August 19, 2019]