

**Original**

**Potential of Panoramic Radiography as a Screening Method for Oral Hypofunction in the Evaluation of Hyoid Bone Position**

Migiwa KURODA\*, Yukiko MATSUDA,  
Emi ITO and Kazuyuki ARAKI

**Abstract** : The hyoid bone is located in the middle of the cervical muscles involved in oral masticatory function. The position of the hyoid bone is commonly determined by lateral cephalometric analysis. Although cephalometric radiography is commonly used in orthodontic treatment, the modality remains rare ; routine dental care would benefit from precise identification of hyoid bone location using a more common modality, such as panoramic radiography. The purpose of this study was to investigate the usefulness of panoramic radiography compared to lateral cephalometric radiography for evaluating hyoid bone position as a potential screening method for oral hypofunction. The study included 347 patients referred for both a panoramic radiograph and a lateral cephalometric radiograph. The patients were divided into the following five groups according to the appearance of the hyoid bone in the panoramic radiograph : Group 1 : hyoid bone could not be observed, or part of the greater horn was observed ; Group 2 : part of the hyoid body was observed, but not the most supero-anterior point of the hyoid bone ; Group 3 : the most supero-anterior point of the hyoid bone was observed ; Group 4 : all of the hyoid body was observed ; Group 5 : the hyoid body overlapped the mandible. The gold standard for measurement of hyoid bone position is the lateral cephalometric radiograph. Hyoid bone position as revealed by lateral cephalometric radiograph was compared among the groups. Hyoid bones that were observed in higher positions on lateral cephalometric radiograph were also observed in higher positions on panoramic radiograph. Hyoid bone position can be assessed by panoramic radiography, and this modality might be useful as a screening method for oral hypofunction.

**Key words** : panoramic radiography, cephalometric radiography, hyoid bone, oral hypofunction

**Introduction**

Frailty is highly prevalent in older adults and is considered to contribute to the risk of falls, disability, hospitalization, and mortality<sup>1)</sup>. Slight signs of frailty in the oral and maxillofacial area might be initial symptoms of serious systemic frailty. In 2014, the Japanese Society of

---

*Department of Oral Diagnostic Sciences, Division of Radiology, Showa University School of Dentistry, 2-1-1 Kitasenzoku, Oota-ku, Tokyo 145-8515, Japan.*

\* To whom corresponding should be addressed.

Gerodontology made several recommendations on the concept of “oral hypofunction” being the stage at which recovery can be expected by performing dental treatment before oral dysfunction occurs<sup>2)</sup>.

The hyoid bone, located in the middle of the cervical muscles involved in oral masticatory function, is considered a useful reference in assessing oral function. Numerous studies have analyzed the relationships between the position of the hyoid bone and aging and dysphagia using various imaging procedures such as videofluorography, contrast radiography, computed tomography (CT) and ultrasonography<sup>3-8)</sup>.

The position of the hyoid bone is commonly determined by lateral cephalometric analysis, for purposes including maxillofacial surgery, diagnosis of sleep apnea, and analysis of skeletal patterns and occlusions<sup>9-11)</sup>. Although cephalometric radiography is commonly used in orthodontic treatment, the modality remains rare; routine dental care would benefit from precise identification of hyoid bone location using a more common modality, such as panoramic radiography.

Panoramic radiographic imaging enables a wide view of the jawbone and thus could be useful as a method to screen for certain lesions that can occur in the maxillofacial area without symptoms. For example, some studies have reported incidental findings such as carotid artery calcification and osteoporosis<sup>12-14)</sup>.

The purpose of this study was to investigate the usefulness of panoramic radiography in the evaluation of hyoid bone position.

## **Materials and methods**

### *Selection of subjects*

This retrospective study included patients referred for both a panoramic radiograph and a lateral cephalometric radiograph during their course of orthodontic treatment from June 2013 to April 2016. This research was approved by the Doctors’ Ethical Committee at Showa University (Approval number 2013-03). Patients with a history of trauma, surgery, mandibular growth disturbance or tumors were excluded. And patients who had difficulty to assume normal positioning for taking the panoramic radiograph due to their physique, posture, and neck disease were excluded. Images in which the hyoid bone was moving due to swallowing at the time of the examination were also excluded. In total, 347 patients were selected, consisting of 106 males and 241 females, with a mean age of 38.3 years (range, 22–69 years). The remaining teeth in each patient were counted to confirm the state of occlusal support using Eichner’s classification.

### *Radiographic imaging protocols and image assessment*

Panoramic radiography was performed with a Hyper-XF device (Asahi Roentgen Ind. Co., Ltd.) with parameters of 78–82 kV, 10 mA, and 12 sec. All patients were positioned with the laser instruction beam to capture the panoramic radiography so that the head and neck inclinations are almost equal. Lateral cephalometric radiography was performed with a Rotanode TM DRX-3724HD device (Toshiba Medical Systems Co., Ltd.) with parameters of 80 kV, 320 mA, and 0.3 sec. Radiographic images were analyzed on a RadiForce RX240 24-inch color LED monitor

(EIZO Co., Ltd.) with  $1,280 \times 1,024$  pixels, and SYNAPSE (Fuji Medical Co., Ltd.) software. Two oral and maxillofacial radiologists assessed the hyoid bone position on each panoramic radiograph.

The patients were divided into five groups according to the position of the hyoid bone in the panoramic radiograph as follows: Group 1: hyoid bone could not be observed, or part of the greater horn was observed; Group 2: part of the hyoid body was observed, but not the most supero-anterior point of the hyoid bone; Group 3: the most supero-anterior point of the hyoid bone was observed; Group 4: all of the hyoid body was observed; Group 5: the hyoid body overlapped the mandible. An example from each group is shown in Figure 1.

The gold standard for measurement of hyoid bone position is the lateral cephalometric radiograph according to the method of Hosoda *et al*<sup>15)</sup>. In this study group, the hyoid bones

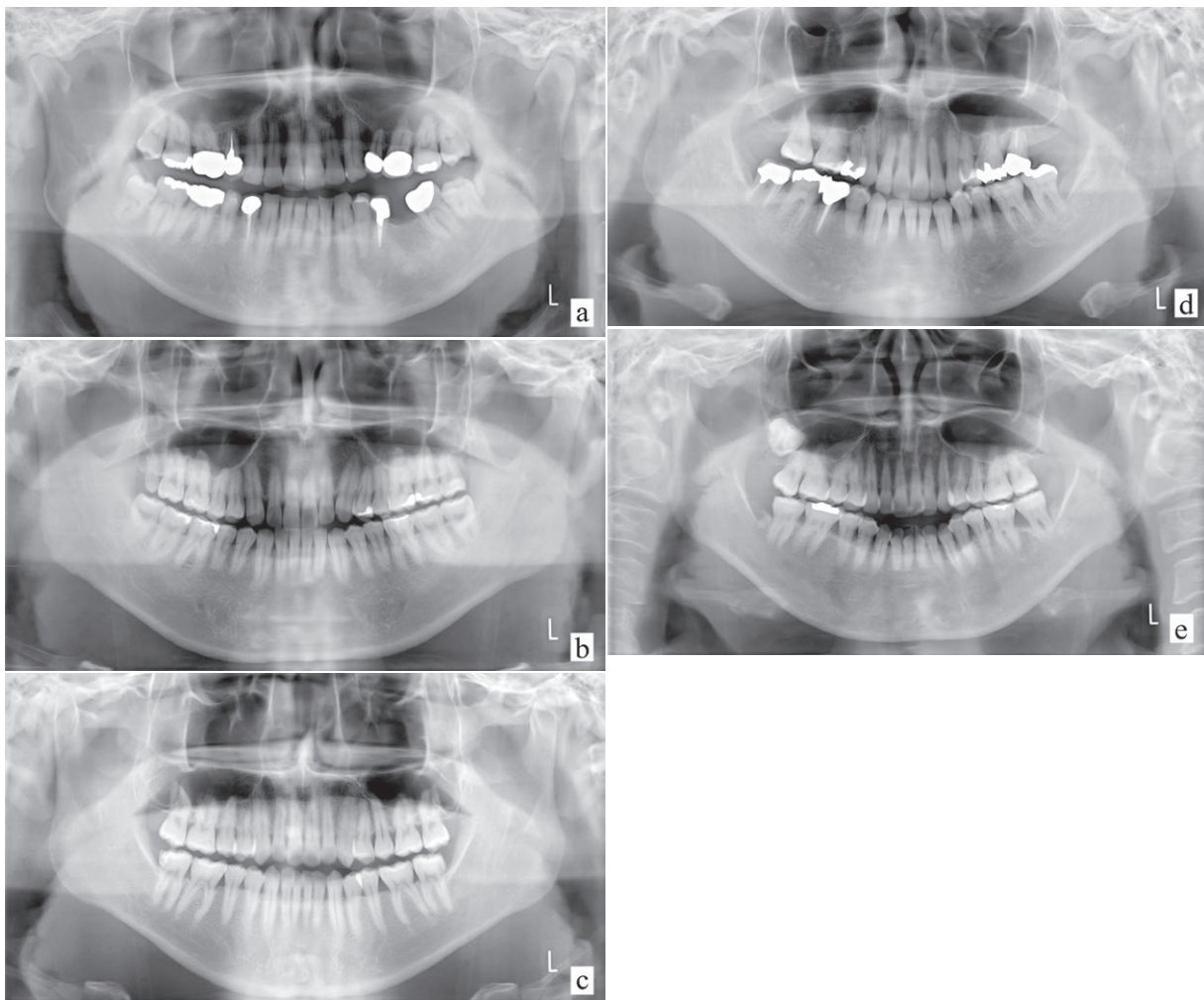


Fig. 1. Hyoid bone position on the panoramic radiograph

- (a) Group 1: hyoid bone could not be observed, or part of the greater horn was observed.
- (b) Group 2: part of the hyoid body was observed, but not the most supero-anterior point of the hyoid bone.
- (c) Group 3: the most supero-anterior point of the hyoid bone was observed.
- (d) Group 4: all of the hyoid body was observed.
- (e) Group 5: the hyoid body overlapped the mandible.

could be observed on the lateral cephalometric radiographs in all patients. Figure 2 shows the landmarks and variable definition of the hyoid bone and the cervical vertebra. The line was set from Menton to the most infero-anterior point of the third cervical vertebra (Me-C3). The reference points were set on the hyoid bone as follows: 1) H: the most supero-anterior point of the hyoid bone; 2) H': the intersection of the line perpendicular from H and the Me-C3 line; 3) H'': the intersection of the line perpendicular from H and the mandibular plane. Perpendicular distance from the hyoid bone to the Me-C3 (H'-H) and mandibular plane (H''-H) was measured. When the hyoid bone was observed above the Me-C3 line, the distance was treated as a negative value.

### Statistical analysis

The distances of H'-H and H''-H on cephalometric radiographs were compared among the five groups. The Kruskal-Wallis test was used for statistical analysis with SPSS Statistics (Ver. 20, Chicago, IL) software ( $p < 0.05$  indicates significant differences).

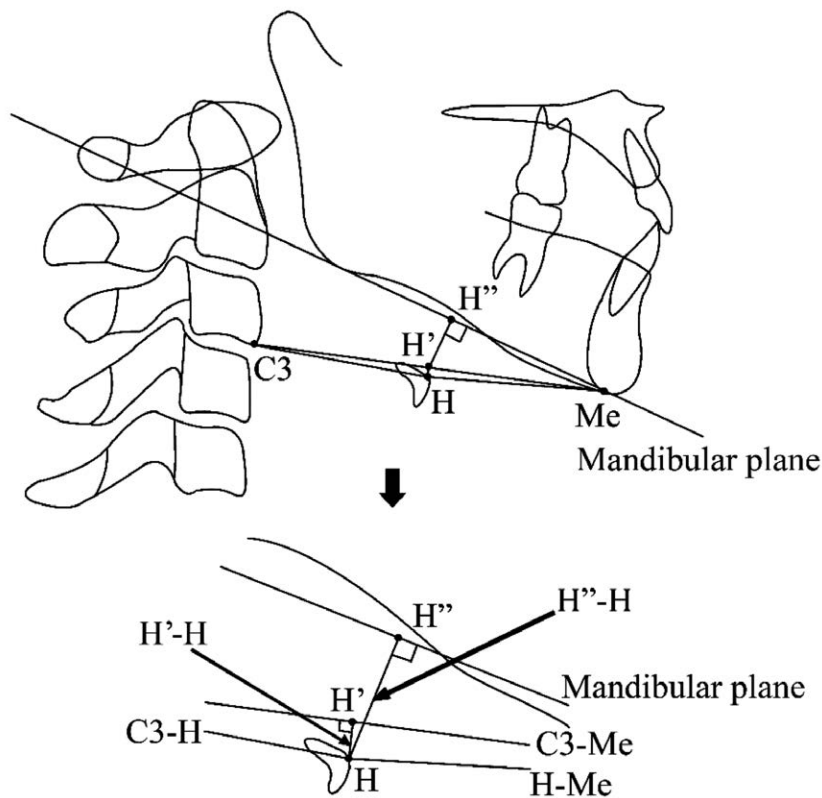


Fig. 2. Measuring the hyoid bone position on the lateral cephalometric radiograph  
Reference point: C3, the lowest salient points of the third cervical vertebra; Me, Menton; H, the most supero-anterior point of the hyoid bone; H', the intersection of the line perpendicular from H and the Me-C3 line; H'', the intersection of the line perpendicular from H and the mandibular plane. Measurement: (1) H'-H, straight distance from H to H'; (2) H''-H, straight distance from H to H''. [Modified from Hosoda *et al*<sup>15)</sup>]

## Results

Table 1 shows the mean and standard deviation (SD) for hyoid bone position relative to the Me-C3 line (H'-H) and to the mandibular lower border (H''-H). Table 1 also indicates the number of remaining teeth and gender in each group, and that no patients had lost occlusal support according to Eichner's classification. Table 2 shows the age distribution of each group.

The distances of H'-H were significantly shorter in Groups 4 and 5 than in Groups 1, 2, and 3 ( $p < 0.01$ ). The distances of H''-H were significantly shorter in Group 5 than in the other groups ( $p < 0.001$ ), while those in Group 4 tended to be shorter than those in Groups 1, 2, and 3.

In the patients whose hyoid bones were observed in higher positions on lateral cephalometric radiographs, the hyoid bones were also in higher positions on panoramic radiographs. Likewise, hyoid bones that appeared at lower positions on lateral cephalometric radiographs were also observed at lower positions on the panoramic radiographs.

## Discussion

The hyoid bone plays an important role during safe swallowing. The act of swallowing is generally described as having three stages, the oral, pharyngeal, and esophageal stages, as defined according to the location of the bolus<sup>16,17</sup>. During the pharyngeal stage, pharyngeal muscles, suprahyoid muscles, and muscles in the oral cavity such as the tongue move the hyoid bone upward<sup>18</sup>. In the pharyngeal stage, the movements of the muscles and the hyoid bone aid in

Table 1. Mean and standard deviation for hyoid bone position and remaining teeth in each group (mean  $\pm$  SD)

Group (n)	Group 1 (n = 16)	Group 2 (n = 12)	Group 3 (n = 21)	Group 4 (n = 177)	Group 5 (n = 121)
H'-H (mm)	6.68 $\pm$ 5.25	6.65 $\pm$ 4.47	6.15 $\pm$ 5.56	-0.97 $\pm$ 5.82	-3.69 $\pm$ 5.66
H''-H (mm)	20.1 $\pm$ 5.87	19.9 $\pm$ 3.79	17.1 $\pm$ 5.74	12.7 $\pm$ 5.23	8.10 $\pm$ 4.84
Remaining teeth	25.6 $\pm$ 1.54	27.0 $\pm$ 1.53	26.2 $\pm$ 1.97	26.9 $\pm$ 1.74	26.7 $\pm$ 2.07
Gender (male : female)	9 : 7	12 : 0	11 : 10	61 : 116	13 : 108

Comment : C3, the lowest salient points of the third cervical vertebra ; Me, Menton ; H, the most supero-anterior point of hyoid bone ; H', the shortest position from H to C3-Me plane ; H'', the shortest position from H to mandibular plane ; H'-H, straight distance from H to H' ; H''-H, straight distance from H to H''.

Table 2. Age distribution across groups

Age (y)	Group 1 (n = 16)	Group 2 (n = 12)	Group 3 (n = 21)	Group 4 (n = 177)	Group 5 (n = 121)
20-29	1	2	6	63	27
30-39	5	4	5	47	27
40-49	8	4	6	44	38
50-59	2	2	4	16	24
60-69	0	0	0	7	5

two crucial functions: food passage and airway protection<sup>19,20</sup>). It is thus important to evaluate the position of the hyoid bone by a simple, common and objective means.

Panoramic radiography is one of the most useful examinations in dental treatment, especially in diagnostic situations requiring broad visualization of the jaws<sup>21</sup>). It also offers the opportunity to visualize the hyoid bone, though it is inferior in reproducibility to the cephalometric radiography<sup>22</sup>).

In the present study, we investigated the usefulness of panoramic radiography in the evaluation of hyoid bone position. Statistically significant differences between the groups were observed in the visibility of the hyoid bone on panoramic radiograph and the bone's position as measured by cephalometric radiograph. Hyoid bones that appeared at lower positions on panoramic radiograph were also observed at lower positions in lateral cephalometric radiograph.

It is generally said that reduced hyoid elevation is a common cause of aspiration in the elderly<sup>23</sup>). It is also reported that the potential for dysphagia is increased if the position of the hyoid bone, which lowers with age, is not compensated by increased elevation during swallowing<sup>3</sup>). The strength of the suprahyoid muscles and the infrahyoid muscles can also affect the position of the hyoid bone. Iida *et al*<sup>24</sup>) suggested that aging decreases the strength of the suprahyoid muscles and that this may contribute to the decline in swallowing function observed in otherwise healthy adults. It is reported that atrophy of the geniohyoid muscle is greater in aspirators compared with non-aspirators in older men and that it might be associated with aging<sup>25</sup>). A study using lateral videofluoroscopy imaging revealed that reductions in anterior hyoid and laryngeal movement below the first-quartile boundaries are statistically associated with increased risk of penetration–aspiration and post-swallow residues<sup>5</sup>). Feng *et al*<sup>8</sup>) used three-dimensional reconstructions of the sagittal plane and two-dimensional reconstructions of CT scans to analyze the position of the hyoid bone and suggested that, among older male aspirators, the hyoid bone was in a more posterior and lower position relative to the mandible compared to non-aspirators. On the other hand, another study reported no differences in pulmonary CT findings between healthy older adult aspirators and non-aspirators<sup>7</sup>). The hyoid bone is located in the middle of the cervical muscles that are involved in oral masticatory function, and decreased muscular strength around the hyoid bone might therefore contribute to the lower position common in elderly patients and the related increased risk of dysphagia.

The elderly population is increasing in Japan, and frailty is an important predictor of the need for long-term care and medical treatment<sup>1,26</sup>). The term “oral hypofunction” as suggested by the Japanese Society of Gerodontology refers to the decline of oral masticatory function in elderly people. Slight signs of frailty in the oral and maxillofacial area such as decreased ability to speak smoothly, chewing and swallowing difficulties, and slight choking are emphasized as initial symptoms of serious systemic frailty<sup>2</sup>). Nevertheless, screening for oral hypofunction should take into account the importance of reducing radiation exposure by using radiographs already taken for dental diagnostic purposes.

The position of the hyoid bone has also been discussed in studies of obstructive sleep apnea (OSA). A number of these studies have reported that an inferiorly positioned hyoid bone and



an increased distance from the mandibular plane to the hyoid bone are commonly observed in OSA patients<sup>27-30</sup>). It might therefore be possible to evaluate the position of the hyoid bone using panoramic radiography as a means of screening not only for oral frailty but also for OSA.

The limitations of this study include the lack of information on aspiration status and age bias among the participants. In this study, both panoramic radiographs and lateral cephalometric radiographs were needed for analysis, and the participants in this study were patients who came to our hospital for orthodontic treatment. Additionally, if the position of the hyoid bone is to be evaluated by panoramic radiography alone, it must be noted that the position of the hyoid bone is affected by the position of the tongue in the oral cavity and the tension of the suprahyoid and the infrahyoid muscles. To account for this, patients must be told to control their swallowing and breathing during the approximately 10 seconds that it takes to capture a panoramic radiograph if the resulting image is to be useful for this purpose. Head positioning might also affect the position of the hyoid bone. In this study, the patients who had difficulty to assume normal positioning at the time of taking panoramic radiograph were excluded. However, for thorough evaluation of the hyoid bone by panoramic radiography it might be necessary to consider the extent to which different head and neck inclinations affect the position of the hyoid. Future studies could aim to improve the reproducibility of panoramic radiography for assessing oral function by further standardizing the position of the tongue and the head.

This study is the first to investigate the relationship between the visibility of the hyoid bone on panoramic radiographs and its position on lateral cephalometric radiograph. Further study is needed to confirm the usefulness of hyoid bone position for predicting oral hypofunction and to generate a set of standards for evaluating oral hypofunction by means of panoramic radiography.

In conclusion, the assessment of hyoid bone position by panoramic radiography might be useful as a screening method for oral hypofunction.

#### **Acknowledgment**

This work was supported by KAKENHI (16K11523).

#### **Conflict of interest disclosure**

The authors report no conflict of interest.

#### **References**

- 1) Fried LP, Tangen CM, Walston J, *et al.* Frailty in older adults: evidence for a phenotype. *J Gerontol A Biol Sci Med Sci.* 2001;**56**:M146-M156.
- 2) Minakuchi S, Tsuga K, Ikebe K, *et al.* Oral hypofunction in the older population: position paper of the Japanese Society of Gerodontology in 2016. *Gerodontology.* 2018;**35**:317-324.
- 3) Furukawa K. Cineradiographic analysis of laryngeal movement during deglutition-with special reference to aging. *Nihon Jibiinkoka Gakkai Kaiho.* 1984;**87**:169-181. (in Japanese).
- 4) Yabunaka K, Sanada H, Sanada S, *et al.* Sonographic assessment of hyoid bone movement during swallowing: a study of normal adults with advancing age. *Radiol Phys Technol.* 2011;**4**:73-77.

- 5) Steele CM, Bailey GL, Chau T, *et al*. The relationship between hyoid and laryngeal displacement and swallowing impairment. *Clin Otolaryngol*. 2011;**36**:30-36.
- 6) Cook II, Dodds WJ, Dantas RO, *et al*. Timing of videofluoroscopic, manometric events, and bolus transit during the oral and pharyngeal phases of swallowing. *Dysphagia*. 1989;**4**:8-15.
- 7) Butler SG, Clark H, Baginski SG, *et al*. Computed tomography pulmonary findings in healthy older adult aspirators versus nonaspirators. *Laryngoscope*. 2014;**124**:494-497.
- 8) Feng X, Todd T, Hu Y, *et al*. Age-related changes of hyoid bone position in healthy older adults with aspiration. *Laryngoscope*. 2014;**124**:231-236.
- 9) Cho HW, Kim IK, Cho HY, *et al*. Retrospective study of changes in pharyngeal airway space and position of hyoid bone after mandibular setback surgery by cephalometric analysis. *Maxillofac Plast Reconstr Surg*. 2015;**37**:38. (accessed 2016 Oct 14) Available from: [https://www.ncbi.nlm.nih.gov/pmc/articles/PMC4620125/pdf/40902\\_2015\\_Article\\_39.pdf](https://www.ncbi.nlm.nih.gov/pmc/articles/PMC4620125/pdf/40902_2015_Article_39.pdf)
- 10) Gulati A, Chate RA, Howes TQ. Can a single cephalometric measurement predict obstructive sleep apnea severity? *J Clin Sleep Med*. 2010;**6**:64-68.
- 11) Zheng B, Jiang Z, Liu F, *et al*. Effect of headgear and Class II traction on upper airway dimensions and hyoid bone position in non-extraction patients with Class II division 1 malocclusion. *J Hard Tissue Biol*. 2015;**24**:1-6.
- 12) Uchida K, Sugino N, Yamada S, *et al*. Clinical significance of carotid artery calcification seen on panoramic radiographs. *J Hard Tissue Biol*. 2014;**23**:461-466.
- 13) Ertas ET, Mavili E, Sisman Y, *et al*. Incidental findings of carotid artery stenosis detected by calcifications on panoramic radiographs: report of three cases. *Oral Radiology*. 2010;**26**:116-121.
- 14) Bollen AM, Taguchi A, Hujoel PP, *et al*. Case-control study on self-reported osteoporotic fractures and mandibular cortical bone. *Oral Surg Oral Med Oral Pathol Oral Radiol Endod*. 2000;**90**:518-524.
- 15) Hosoda K, Yamaguchi M, Kasai K, *et al*. Hyoid bone position in relation to skeletal malocclusion using cephalograms. *Nihon Univ J Oral Sci*. 1996;**22**:262-270. (in Japanese).
- 16) Jean A. Brain stem control of swallowing: neuronal network and cellular mechanisms. *Physiol Rev*. 2001;**81**:929-969.
- 17) Dodds WJ, Stewart ET, Logemann JA. Physiology and radiology of the normal oral and pharyngeal phases of swallowing. *AJR Am J Roentgenol*. 1990;**154**:953-963.
- 18) Park JS, Hwang NK, Oh DH, *et al*. Effect of head lift exercise on kinematic motion of the hyolaryngeal complex and aspiration in patients with dysphagic stroke. *J Oral Rehabil*. 2017;**44**:385-391.
- 19) Matsuo K, Palmer JB. Anatomy and physiology of feeding and swallowing: normal and abnormal. *Phys Med Rehabil Clin N Am*. 2008;**19**:691-707.
- 20) Magara J, Hayashi H, Kanda C, *et al*. Spatial and temporal relationship between swallow-related hyoid movement and bolus propulsion during swallowing. *J Jpn Soc Stomatognath Funct*. 2013;**20**:22-32.
- 21) Mallya SM, Lurie AG. Panoramic Imaging. In *White S, Pharoah MJ, eds. Oral radiology: principles and interpretation. 7th ed.* St. Louis, MO: Mosby Elsevier; 2014. pp166-184.
- 22) Morisawa Y. Examination of clinical X-ray for the correlation between hyoid and mandibular displacement: first report: change of the projection image by the position of the hyoid bone. *Dental Radiology*. 2008;**48**:37-44. (in Japanese).
- 23) Shinozaki H, Tohara H, Matsubara M, *et al*. Relationship between jaw opening force and hyoid bone dynamics in healthy elderly subjects. *Clin Interv Aging*. 2017;**12**:629-634.
- 24) Iida T, Tohara H, Wada S, *et al*. Aging decreases the strength of suprahyoid muscles involved in swallowing movements. *Tohoku J Exp Med*. 2013;**231**:223-228.
- 25) Feng X, Todd T, Lintzenich CR, *et al*. Aging-related geniohyoid muscle atrophy is related to aspiration status in healthy older adults. *J Gerontol A Biol Sci Med Sci*. 2013;**68**:853-860.
- 26) Kera T, Kawai H, Yoshida H, *et al*. Classification of frailty using the Kihon checklist: a cluster analysis of older



- adults in urban areas. *Geriatr Gerontol Int.* 2017;**17**:69-77.
- 27) Lavanya R, Gandhi Babu DB, Chavva S, *et al.* The role of oral physicians in predicting the risk of obstructive sleep apnea: a case-control study. *Imaging Sci Dent.* 2016;**46**:167-171.
  - 28) Armalaite J, Lopatiene K. Lateral teloradiography of the head as a diagnostic tool used to predict obstructive sleep apnea. *Dentomaxillofac Radiol.* 2016;**45**:20150085. (accessed 2018 May 2) Available from: <https://www.ncbi.nlm.nih.gov/pmc/articles/PMC5083885/pdf/dmfr.20150085.pdf>
  - 29) Sforza E, Bacon W, Weiss T, *et al.* Upper airway collapsibility and cephalometric variables in patients with obstructive sleep apnea. *Am J Respir Crit Care Med.* 2000;**161**:347-352.
  - 30) Takai Y, Yamashiro Y, Satoh D, *et al.* Cephalometric assessment of craniofacial morphology in Japanese male patients with obstructive sleep apnea-hypopnea syndrome. *Sleep Biol Rhythms.* 2012;**10**:162-168.

[Received May 28, 2019 : Accepted July 2, 2019]