

Case Report

Teriparatide Treatment for An Atypical Fracture of the Femoral Shaft : A Case Report

Yusuke OSHITA^{*1)}, Takuma KURODA¹⁾, Koji ISHIKAWA²⁾,
Takashi NAGAI²⁾, Keikichi KAWASAKI¹⁾, Koji KANZAKI³⁾
and Katsunori INAGAKI²⁾

Abstract : An 82-year-old woman had been taking alendronate for 5 years and 5 months, which had been prescribed for osteoporosis at a local clinic. Severe left thigh pain began without any trauma. X-ray, computed tomography and magnetic resonance imaging findings showed atypical femoral fracture (AFF). Treatment with teriparatide and weight-bearing therapy was selected. Bone union was achieved without surgery. Teriparatide has been reported to promote AFF healing. At four years and 9 months from the beginning of treatment, our patient has no left femoral pain and no impairment to activities of daily living. Careful follow-up will be necessary as long-term outcomes of conservative AFF treatment have not been reported to date.

Key words : atypical fracture, teriparatide, non-surgical procedure, alendronate, osteoporosis

Introduction

We report the case of a patient who sustained an atypical femoral fracture (AFF) during alendronate therapy for osteoporosis. Bone union was achieved with concurrent teriparatide administration and weight-bearing therapy.

Case report

We treated an 82-year-old woman whose chief complaint was left femoral pain. She had no recent history of trauma, but she had previously been diagnosed with osteoporosis and had been taking 35 mg of alendronate once weekly for 5 years and 5 months. On developing idiopathic left femoral pain, she was treated with non-steroidal anti-inflammatory drugs by a local physician. However, her symptoms were not alleviated. Therefore, she was referred to our hospital 3 months after she first experienced the pain. On initial examination, the patient had gait disturbance and experienced pain while turning over in bed. X-ray images showed a transverse

¹⁾ Department of Orthopedic Surgery Showa University, Northern Yokohama Hospital, 35-1 Chigasaki-Chuo, Tsuzuki-ku, Yokohama 224-8503, Japan.

²⁾ Department of Orthopedic Surgery, Showa University School of Medicine.

³⁾ Department of Orthopedic Surgery, Orthopedic Surgery, Showa University Fujigaoka Hospital.

* To whom corresponding should be addressed.

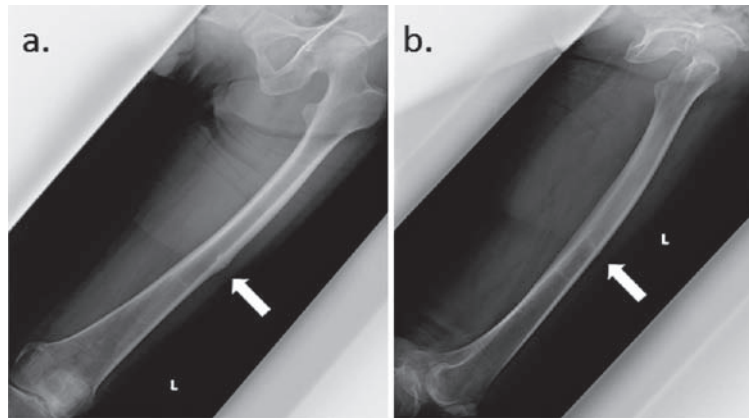


Fig. 1. Plain radiograph showing cortical thickness with radiolucent line (white arrow)
a : Anterior-posterior view, b : Lateral view.

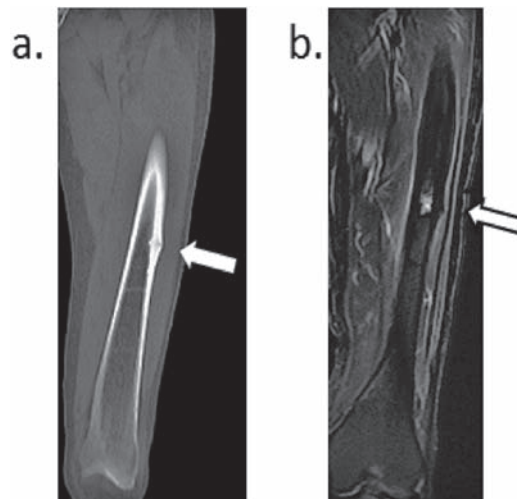


Fig. 2. Computed tomography and magnetic resonance imaging scans showing a left femur fracture
a : Computed tomography scan showing cortical thickness with radiolucent line (white arrow).
b : Magnetic resonance imaging scan showing signal intensity change (white arrow).

fracture in the left femoral shaft that extended to about half the bone diameter (Fig. 1). Computed tomography confirmed cortical bone thickening and the fracture line. Fat-suppressed magnetic resonance imaging (MRI) showed high signal intensity (Fig. 2). No malignant lesions were observed. A plain radiograph of the right femur showed cortical thickness but no radiolucent line.

The patient's blood bone biochemistry showed that she had abnormally low levels of metabolic markers for bone turnover, including P1NP (15.4 $\mu\text{g}/\text{l}$, range, 16.4–98.2 $\mu\text{g}/\text{l}$). Her

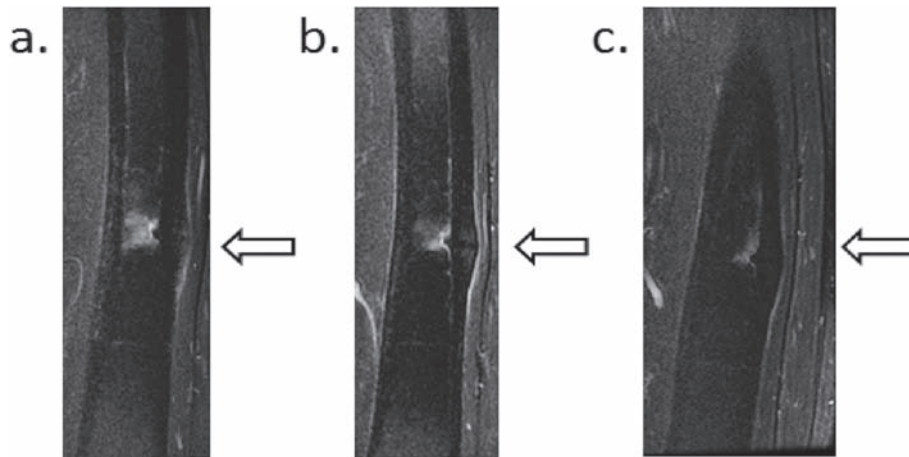


Fig. 3. Magnetic resonance imaging scans showing change in signal intensity
 a : 2 months after initial treatment.
 b : 3 months after initial treatment.
 c : 4 months after initial treatment.

bone mineral density relative to the young adult mean was 58% for the distal one-third of the radius, 78% for the femoral neck, and 82% for the anterior–posterior density of the L2–L4 vertebrae. Based on clinical and imaging findings, we diagnosed bisphosphonate-induced atypical fracture. The patient was hospitalized for treatment because she lived alone and had difficulty with activities of daily living. Subsequently, teriparatide therapy (56.5 μ g teriparatide acetate per week) was initiated and we established an exercise program of walking with partial (half) weight-bearing using double crutches. The patient was discharged 3 weeks after her gait stabilized. After 4 weeks of teriparatide therapy, the pain had been alleviated. An MRI scan showed a decrease in the luminosity change, standard x-ray images showed an increase in callus formation, and the patient could walk with full weight-bearing using crutches. Three months after treatment initiation, she could walk unassisted. At 4 months, her condition had further improved. In addition, the signal intensity changes that were previously evident on MRI scanning had mostly disappeared (Fig. 3). Four years and 9 months since her treatment began, she has no left femoral pain and no impairment to activities of daily living.

Discussion

During treatment of osteoporosis with bisphosphonate, bone metabolism is excessively suppressed, which can cause AFF. The incidence of AFF increases with the use of bisphosphonate for more than 5 years¹⁾, although a shorter duration of therapy may also lead to AFF^{2, 3)}. Interestingly, a diagnostic criteria task force of the American Society for Bone and Mineral Research has reported the involvement of femoral curvature⁴⁻⁷⁾. Thus, the exact pathological process is unclear, and the treatment strategy for AFF is controversial. Also, cases of delayed union in patients treated with bisphosphonates have been reported⁸⁻¹⁰⁾. However, by treating our patient with teriparatide, we achieved bone union much sooner than described in

other reported cases of healed fractures^{10, 11)}. In reports of conservative treatment, surgery was required more often for subtrochanteric fractures than for diaphyseal (shaft) fractures¹²⁾. The present patient sustained a femoral shaft fracture, which we were able to treat conservatively. A case of subtrochanteric AFF in which bone union was achieved following intramedullary nail fixation and administration of teriparatide therapy has also been reported⁹⁾. However, we were able to achieve bone union before complete bone fracture occurred. In cases of complete fracture, further treatment would be needed to prevent the onset of displacement. Generally, conservative treatment is only an option for cases of incomplete fracture¹³⁾, but AFF rarely heals spontaneously and most patients require surgery^{14, 15)}. Specifically, teriparatide appears to promote AFF healing¹⁶⁾, so weight-bearing gait rehabilitation during teriparatide treatment^{17, 18)} might be a good conservative treatment option for some patients. We believe that teriparatide therapy enhanced the bone union in our patient. We also believe that teriparatide treatment is likely to result in acceptable long-term outcomes, given the medium-term clinical success achieved with our patient.

Conclusion

We report our experience of treating a patient who developed an atypical fracture after 5 years and 5 months of alendronate therapy. The bone fracture site healed following teriparatide therapy. We conclude that conservative treatment might be a good treatment option in such cases.

Conflicts of interest disclosure

The authors have no conflicts of interest to disclose.

Patient consent

We obtained informed consent from our patient to publish her data.

References

- 1) Park-Wyllie LY, Mamdani MM, Juurlink DN, *et al*. Bisphosphonate use and the risk of subtrochanteric or femoral shaft fractures in older women. *JAMA*. 2011;**305**:783–789.
- 2) Black DM, Thompson DE, Bauer DC, *et al*. Fracture risk reduction with alendronate in women with osteoporosis: the Fracture Intervention Trial. FIT Research Group. *J Clin Endocrinol Metab*. 2000;**85**:4118–4124. Erratum in: *J Clin Endocrinol Metab*. 2001;**86**:938.
- 3) Tan SC, Koh SB, Goh SK, *et al*. Atypical femoral stress fractures in bisphosphonate free patients. *Osteoporosis Int*. 2011;**22**:2211–2212.
- 4) Shane E, Burr D, Abrahamsen B, *et al*. Atypical subtrochanteric and diaphyseal femoral fractures: second report of a task force of the American Society for Bone and Mineral Research. *J Bone Miner Res*. 2014;**29**:1–23.
- 5) Sasaki S, Miyakoshi N, Hongo M, *et al*. Low-energy diaphyseal femoral fractures associated with bisphosphonate use and severe curved femur: a case series. *J Bone Miner Metab*. 2012;**30**:561–567.
- 6) Oh Y, Wakabayashi Y, Kurosa Y, *et al*. Stress fracture of the bowed femoral shaft is another cause of atypical

- femoral fracture in elderly Japanese : a case series. *J Orthop Sci.* 2014;**19**:579–586.
- 7) Saita Y, Ishijima M, Mogami A, *et al.* The fracture sites of atypical femoral fractures are associated with the weight-bearing lower limb alignment. *Bone.* 2014;**66**:105–110.
 - 8) Oshita Y, Nakamura M, Mikumo H, *et al.* Atraumatic femoral insufficiency fracture in postmenopausal women taking bisphosphonate. *Showa Univ J Med Sci.* 2011;**23**:257–261.
 - 9) Fukuda F, Kurinomaru N, Hijioka A. Weekly teriparatide for delayed unions of atypical subtrochanteric femur fractures. *Biol Ther.* 2014;**4**:73–79.
 - 10) Huang HT, Kang L, Huang PJ, *et al.* Successful teriparatide treatment of atypical fracture after long-term use of alendronate without surgical procedure in a postmenopausal woman : a case report. *Menopause.* 2012;**19**:1360–1363.
 - 11) Chiang CY, Zebaze RM, Ghasem-Zadeh A, *et al.* Teriparatide improves bone quality and healing of atypical femoral fractures associated with bisphosphonate therapy. *Bone.* 2013;**52**:360–365.
 - 12) Lee YK, Ha YC, Kang BJ, *et al.* Predicting need for fixation of atypical femoral fracture. *J Clin Endocrinol Metab.* 2013;**98**:2742–2745.
 - 13) Toro G, Ojeda-Thies C, Calabro G, *et al.* Management of atypical femoral fracture: a scoping review and comprehensive algorithm. *BMC Musculoskelet Disord.* 2016;**17**:227. (accessed 2018 Sep 10) Available from : https://www.ncbi.nlm.nih.gov/pmc/articles/PMC4878072/pdf/12891_2016_Article_1086.pdf
 - 14) Ha YC, Cho MR, Park KH, *et al.* Is surgery necessary for femoral insufficiency fractures after long-term bisphosphonate therapy? *Clin Orthop Relat Res.* 2010;**468**:3393–3398.
 - 15) Oshita Y, Nagai T, Ishikawa K, *et al.* Incidence and clinical features of Atypical femoral fracture. *JJOS.* 2019;**5**:95-100 in press. (in Japanese).
 - 16) Miyakoshi N, Aizawa T, Sasaki S, *et al.* Healing of bisphosphonate-associated atypical femoral fractures in patients with osteoporosis : a comparison between treatment with and without teriparatide. *J Bone Miner Metab.* 2015;**33**:553–559.
 - 17) Saleh A, Hegde VV, Potty AG, *et al.* Management strategy for symptomatic bisphosphonate-associated incomplete atypical femoral fractures. *HSS J.* 2012;**8**:103–110.
 - 18) Kim HS, Jung HY, Kim MO, *et al.* Successful conservative treatment: multiple atypical fractures in osteoporotic patients after bisphosphate medication: a unique case report. *Medicine (Baltimore).* 2015;**94**:e446. (accessed 2018 Sep 10) Available from: <https://www.ncbi.nlm.nih.gov/pmc/articles/PMC4602721/pdf/medi-94-e446.pdf>

[Received August 27, 2018 : Accepted November 1, 2018]