Original article

Usefulness of antenatal ultrasound fetal morphological assessments in the first and second trimester: A study at a single Japanese university hospital

Hiroko Takita, Junichi Hasegawa, Tatsuya Arakaki, Masamitsu Nakamura, Shoko Hamada, Mayumi Tokunaka, Tomohiro Oba, Ryu Matsuoka, Akihiko Sekizawa

Department of Obstetrics and Gynecology,

Showa University School of Medicine, Tokyo, Japan

2822 words, 5 tables and 1 figure

Correspondence to: Dr. Junichi Hasegawa

Department of Obstetrics and Gynecology

Showa University School of Medicine

1-5-8 Hatanodai, Shinagawa-ku, Tokyo, 142-8666, Japan

TEL: +81-3-3784-8551 FAX: +81-3-3784-8355

E-mail: hasejun@oak.dti.ne.jp

Funding sources: None

Conflicts of interest: All authors have no potential conflicts of interest to declare.

Key words:morphorogical assessment; first trimester; second trimester; ultrasound assessment; fetal anomaly

Abstract

Objective: To assess the usefulness of antenatal ultrasound examinations for detecting fetal morphological abnormalities in the first and second trimesters.

Methods: A prospective cohort study was conducted at a single Japanese university hospital in the period from February 2011 to September 2013. Patients in whom ultrasound was attempted at both 11-13+6 and 18-20+6 weeks' gestation and were delivered at our hospital were enrolled. After delivery, neonatal congenital abnormalities were reviewed and compared with the ultrasound findings in the first and second trimesters.

Results: The subjects included 2,028 singleton babies. Abnormal fetal morphological findings were found in the first trimester in 28 cases, Of these patients, fetal anomaly as diagnostic findings were anencephaly (2 cases) and endocardial cushion defect (2 cases). Findings suspected fetal anomaly were observed in 24 cases in the first trimester. Twelve cases with ultrasound findings in the first trimester including fetal edema, anencephaly, endocardial cushion defect, revealed abnormal chromosome after amniocentesis. Ultrasound findings in the first trimester were disappeared until 18 weeks of gestations in eight cases, and they were preserved in three cases. Fetal anomalies were primarily noted in the second trimester in 10 cases. However, after delivery, morphological abnormalities were primarily observed in 18 cases

Conclusion: Major congenital abnormalities were identified in the first trimester morphological assessment. We think the use of a combination of the first trimester ultrasound screening and the second trimester ultrasound scan for detecting fetal anomalies were effective.

Introduction

Screening is the systematic application of a test or inquiry to identify the individuals at sufficient risk of a specific disorder to benefit from further investigation [1]. First trimester fetal morphological screenings by ultrasound are popular in Western countries [2]. Although antenatal ultrasound screening for morphological abnormalities has now become an accepted obstetric practice, there is some variation in the practice at different centers. Acquiring more information during the gestational period allows clinicians to improve the management of pregnancy and gives parents earlier reassurance about the well-being of the fetus [3]. At present, however, first trimester morphological assessments are not popular in Japan.

In our institution, while second trimester ultrasound morphological assessments are performed systematically, we additionally added first trimester ultrasound morphological assessments starting in 2011. To the best of our knowledge, there are no previous reports evaluating the accuracy of first and second trimester ultrasound morphological assessments in Japan. The aim of the present study was therefore to assess the usefulness of ultrasound examinations for detecting fetal morphological abnormalities.

Patients and methods

A prospective cohort study was conducted from February 2011 to September 2013 at Showa University Hospital. Patients in whom ultrasound fetal morphological assessments were attempted in the first trimester (11-13+6 weeks' gestation) and second trimester (18-20+6 weeks' gestation) and subsequently delivered at our hospital were enrolled. Multiple gestations were excluded from the present study. Patients referred for an ultrasound diagnosis of morphological abnormalities or other complications were also excluded.

After delivery, neonatal congenital abnormalities were reviewed and compared with the ultrasound findings obtained in the first and second trimesters. All ultrasound examinations conducted in the first and second trimesters were performed via the transabdominal (TA) approach.

Six of the authors (H.T., J.H., T.A., M.N., S.H. and M.T.) who have received accreditation by the Fetal Medicine Foundation to perform scans at 11 to 13+6 weeks performed the ultrasound scans. The ultrasound equipment was a Voluson E8 (GE Healthcare Japan, Tokyo) with a 4- to 8-MHz transabdominal transducer.

Reference ultrasound pictures obtained in the first trimester

The ultrasound morphological assessments in the first trimester were performed for screening of fetal anomalies and cases obtained abnormal findings were

carefully followed up in pregnant checkups. The visits to the outpatient clinic for the ultrasound assessments were set at 30-minute intervals per fetus. This screening at our institution in the first trimester was performed based on the following definitions and reference ultrasound pictures modified from a previous report by Souka et al. [4] (Table1).

1) Skull and brain: Size and shape of the skull, presence of midline falx, a butterfly shape of the choroid plexus in the cerebral ventricles, and cerebellum.

2) Face: View of the median facial profile and both orbits.

3) Neck and spine: The alignment of the vertebrae and skin covering the spine from the cervical to sacral region.

4) Chest: Lungs without evidence of pleural effusion or cystic or solid masses, diaphragm with a normal intra-abdominal position of the stomach, heart rate and four-chamber view of the heart.

5) Abdomen: Abdominal wall and stomach as a hypoechoic structure in the left upper abdomen, kidneys as hyperechoic structures with a hypoechoic center lateral to the spine, bladder as a hypoechoic structure in the fetal pelvis and two umbilical arteries.

6) Limb and extremities: Long bones, fingers, toes and their movement.

7) External genitalia

Note

Fetal edema: This was defined when the edema of the whole body of the fetus were visualized.

Reference ultrasound pictures obtained in the second trimester

The ultrasound morphological assessments in the second trimester were performed for prenatal final diagnosis of fetal anomalies. The visits to the outpatient clinic for the ultrasound assessments were scheduled at 30-minute intervals per fetus. This ultrasound diagnosis at our institution were performed based on the following definitions and reference ultrasound pictures similar to previous guidelines [5] and a review article [6] (Table 2).

1) Skull and brain: Size, shape, integrity and bone density of the skull, presence of the lateral ventricles including the choroid plexus, cavum septum pellucidum, midline falx, thalami, cerebellum and cisterna magna of brain structures.

2) Face: Median facial profile, both orbits, nose and nostrils and the upper lip for possible cleft lip.

3) Neck and spine: Neck as a cylindrical structure with no protuberances, masses or fluid collection and the fetal spine.

5) Chest: Lung, diaphragm and heart including heart rate, size, the four-chamber view (visualization of the two atria and ventricles, interventricular septum, crux and

atrioventricular valves), aortic and pulmonary outflow tracts in the transverse plane, aortic arch in the sagittal plane and three-vessel view of the great vessels (visualization of a cross-sectional view of the pulmonary arteries, aorta and superior vena cava).

6) Abdomen: Abdominal wall, abnormal fluid collection in the bowel or any other cystic structures, stomach position, size and shape in the transverse view, size and appearance of the kidneys, renal pelvis, bladder and two umbilical arteries.

7) Limbs and extremities: Long bone, the presence of both arms/hands, both legs/feet, fingers and toes.

8) External Genitalia: the characteristics of the external genitalia to determine the fetal gender.

This research study was approved by the Ethics Committee of our hospital. Informed consent was obtained in writing from all patients before conducting ultrasound scanning. The confidentiality of the patients was protected, and no personal data were collected in the present study.

Results

A total of 2028 patients were enrolled in the present study. The maternal and neonatal demographics of all cases are demonstrated in Table3.

A study flow diagram and the outcomes accuracy of antenatal ultrasound fetal morphological assessments are presented in Figure 1, Table4 and Table5. Visualized rates in each ultrasound findings in the first trimester were as follows, skull and brain 99.8%, face 99.8%, chest 98.8%, abdomen 99.6%, limb and extremities 98.2%, and external genitalia 82.4%, respectively.

Abnormal fetal morphological findings were found in the first trimester in 28cases. Of these patients, fetal anomaly as diagnostic findings were anencephaly (2 cases) and endocardial cushion defect (2 cases). . Findings suspected fetal anomaly included 16 cases of fetal edema, a case of ventriculomegaly, three case of choroid plexus cyst, a case of cardiac forcus, ascites, absent stomach, and umbilical cord cyst. Twelve cases with ultrasound findings in the first trimester including fetal edema, anencephaly, endocardial cushion defect, revealed abnormal chromosome after amniocentesis. Ultrasound findings in the first trimester were disappeared until 18 weeks of gestations in eight cases, and they were preserved in three cases. Fetal anomalies were primarily noted in the second trimester in 10 cases, including three

cases of cleft lip, a case of ventricular septal defect, a case of intestinal atresia, two cases of hydronephrosis (grade IV), two cases of polycystic kidneys, and a case of spina bifida. Three cases suspected fetal anomaly in the first trimester were diagnosed as heterotaxia and single ventricle, ventricular septal defect and hydronephrosis in the second trimester morphological assessment.

After delivery, morphological abnormalities were primarily observed in 18 cases including two cases of an accessory ear, a case of funnel chest, a case of atrial septal defect, eight cases of ventricular septal defect, a case of pyloric atresia, and double ureter, hypospadias, meatal atresia, anal atresia, and polysyndactyly. However, all of the diagnosis of fetal anomalies in the second trimesters were confirmed in the neonates. Therefore, fetal morphological abnormalities were observed in a total of 31 cases (1.5% of all deliveries) after delivery.

Discussion

In the present study, anencephaly and endocardial cushion defect were detected on the first trimester ultrasound assessments. This result indicates that major congenital abnormalities are detectable in the first trimester, similar to previous studies [7, 8]. In other investigations, it has been reported that other abnormalities, including alobar holoprosencephaly, exomphalos, gastroschisis, megacystis and body stalk anomalies, the absence of hands or feet, diaphragmatic hernia, lethal skeletal dysplasia, polydactyly, facial clefts, open spina bifida, echogenic lung lesions, bowel obstruction, omphalocele and most renal defects and talipes, may be found in the first trimester [7, 8]. We think the purpose of the ultrasound assessments in the second trimester is final prenatal diagnosis of fetal morphological anomalies, while the first trimester ultrasound assessments are performed as screening.

On the other hand, ultrasound findings suspected anomaly, not diagnostic findings were observed in 24 cases in the first trimester. Of these cases, two-third had abnormal chromosome or fetal anomaly, or resulted spontaneous abortion. We did not find abnormal fetal findings such as cleft lip, hydronephrosis, ventricular septal defect, polycystic kidneys, spina bifida, heterotaxia, a single ventricle and intestinal atresia in the first trimester. However, these abnormal findings were detected in the second

trimester. We believe that the poor sensitivity for detecting cleft lip, kidney disease, spina bifida and cardiac disease in the first trimester may be attributed to technical difficulties due to the small size of the fetus in the first trimester. Pilalis et al. [9] reported that first trimester assessments are very effective for detecting anencephaly, abdominal wall defects, body stalk anomalies and limb reduction defects, although the results were disappointing for the detection of cardiac and open neural tube defects. Because the fetal body remains small in the first trimester, first trimester assessments are suitable for evaluating the whole body of the fetus and detecting major structural abnormalities. On the other hand, second trimester assessments are easy to carry out using a detailed scan. We therefore consider that first trimester assessments play a role in early screening for major structural anomalies, different from the diagnosis of fetal anomaly detected in the second trimester.

Abnormal fetal findings such as ventricular septal defect (VSD), an accessory ear, double ureter, hypospadias, anal atresia, pyloric atresia, polysyndactyly, funnel chest or meatal atresia were not identified by these scans. These abnormal findings were found only after delivery on examinations by obstetricians and pediatricians. Eight cases of VSD were not detected on prenatal ultrasound assessments. In the cases of VSD that were not detected during pregnancy, the interventricular septum was

unlikely to be horizontal on the stored pictures. Therefore, the present rate of detection of VSD was poor, which is similar to the findings of a previous study reported by Nielsen et al., in which the detection rate of atrioventricular septal defects was 50.0% [10].

Hypospadias, a double ureter and meatal atresia were missed on the prenatal ultrasound assessments in the current study. The ultrasound diagnosis of hypospadias is made based on the findings of extreme ventral angulation of the penis in a form resembling a tulip flower, formed by the ventrally bent penis located between the two scrotal folds [11]. However, we investigated the bladder in only the coronal plane, so this landmark was missed. Although a double ureter is often found in patients with hydronephrosis or morphological abnormalities, none of cases were complicated with these abnormalities. Hence, this condition is usually diagnosed after birth.

Because ears were not included in the second trimester morphological assessments, no cases of an accessory ear were found in our investigations. We believe that it is not essential to detect an accessory ear antenatally, as this condition is not life-threatening and can be seen immediately after delivery and subsequently cured with simple treatment. Additionally, no cases of polysyndactyly were identified. Although all fingers were confirmed to be present in our investigations, we did not

check for an open or grasping hand. Alternatively, while funnel chest is common in cases of Marfan syndrome [12], no signs of funnel chest without other anomalies were found.

We consider the provision of intensive and focused ultrasound assessments to be essential for achieving accurate ultrasound prenatal diagnosis. However, some limitations can be expected in the introduction of such ultrasound screening protocols in many of the other hospitals in Japan. At present, the frequency of checkup scans during pregnancy is high in Japan, in comparison to other developed countries, because physicians only have a limited time to scan each patient. Moreover, ultrasound scans are usually performed by individual doctors in Japan, and repeat checks by specialists are not available. Consequently, efforts should be made to establish an environment in which ultrasound examinations, which can provide accurate prenatal diagnosis and which includes a system of outpatient clinics and examiners. To ensure equitable access to these examinations a referral system between the regional hospitals and clinics should also be established. Additionally, all examiners should be strongly motivated to provide complete scanning in order to further improve the accuracy.

In conclusion, major congenital abnormalities were identified in the first

trimester, instead of the second trimester, on morphological assessments. We think the use of a combination of the first trimester ultrasound screening and the second trimester ultrasound scan for detecting fetal anomalies were effective.

References

(1) Chandrasekaran N, Viswanatha R, Bhide A. Ultrasound in antenatal diagnosis of structural abnormalities. Obstetrics, Gynaecology and Reproductive Medicine 2013;23:101-07.

(2) Souka AP, Pilalis A, Kavalakis I, et al Screening for major structural abnormalities at the 11- to 14-week ultrasound scan. Am J Obstet Gynecol 2006;194:393-6.

(3) Luchi C, Schifano M, Sacchini C, et al Detailed fetal anatomy assessment in the first trimester at 11, 12 and 13 weeks of gestation. J Matern Fetal Neonatal Med 2012;25:675-8.

(4) Souka AP, Pilalis A, Kavalakis Y, et al Assessment of fetal anatomy at the 11-14-week ultrasound examination. Ultrasound Obstet Gynecol 2004;24:730-4.

(5) Schwarzler P, Senat MV, Holden D, et al Feasibility of the second-trimester fetal ultrasound examination in an unselected population at 18, 20 or 22 weeks of pregnancy: a randomized trial. Ultrasound Obstet Gynecol 1999;14:92-7.

(6) Chandrasekaran N, Viswanatha R, Bhide A. Ultrasound in antenatal diagnosis of structural abnormalities
Obstetrics, Gynaecology and Reproductive Medicine 2013;23:101-07.

(7) Syngelaki A, Chelemen T, Dagklis T, et al Challenges in the diagnosis of fetal non-chromosomal abnormalities at 11-13 weeks. Prenat Diagn 2011;31:90-102.

(8) Grande M, Arigita M, Borobio V, et al First-trimester detection of structural abnormalities and the role of aneuploidy markers. Ultrasound Obstet Gynecol 2012;39:157-63.

(9) Pilalis A, Basagiannis C, Eleftheriades M, et al Evaluation of a two-step ultrasound examination protocol for the detection of major fetal structural defects. J Matern Fetal Neonatal Med 2012;25:1814-7.

(10) Nielsen DE, Vejlstrup N, Jorgensen C, et al Prenatal detection of congenital heart disease in a low risk population undergoing first and second trimester screening. Prenat Diagn 2014.

(11) Meizner I. The 'tulip sign': a sonographic clue for in-utero diagnosis of severe hypospadias. Ultrasound Obstet Gynecol 2002;19:317.

(12) Bezuska L, Mussa S, Muthialu N. Chest wall reconstruction in Marfan syndrome following aortic root replacement. Asian Cardiovasc Thorac Ann 2014;22:872-4.

Ethical Consideration

All procedures followed were in accordance with the ethical standards of the responsible committee on human experimentation (institutional and national) and with the Helsinki Declaration of 1975, as revised in 2008 (5). Informed consent was obtained from all patients for being included in the study.

Conflict of Interest

There are no financial or other relations that could lead to a conflict of interest.

Figure 1

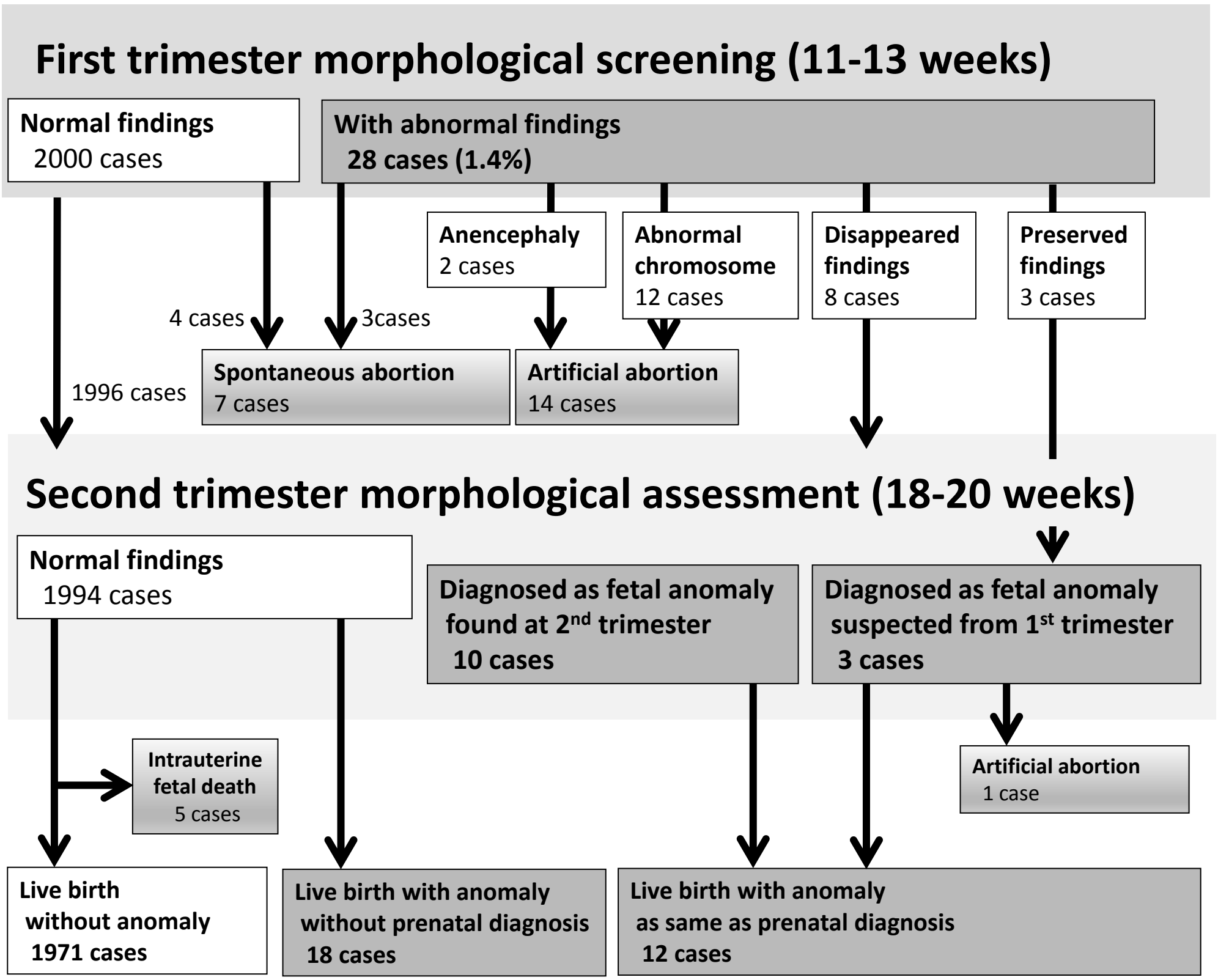
First trimester morphological screening (11-13 weeks)
Normal findings
2000 cases
With abnormal findings
28 cases (1.4%)
Anencephaly
2 cases
Abnormal chromosome
12 cases
Disappeared findings
8 cases
Preserved findings
3 cases
4 cases
3cases
1996 cases
Spontaneous abortion
7 cases
Artificial abortion
14 cases
Second trimester morphological assessment (18-20 weeks)
Normal findings
1994 cases
Diagnosed as fetal anomaly found at 2nd trimester
10 cases
Diagnosed as fetal anomaly suspected from 1st trimester
3 cases
Intrauterine fetal death
5 cases
Artificial abortion
1 case
Live birth without anomaly
1971 cases
Live birth with anomaly without prenatal diagnosis
18 cases
Live birth with anomaly as same as prenatal diagnosis
12 cases

Table 1: Checklist of the first trimester ultrasound screening of fetal anomalies

Skull and brain	Size and shape of skull
	Midline falx
	Cerebral ventricles
	Butterfly shape of the choroid plexus
	Cerebellum
Face	Median facial profile
	Both orbits
Neck and spine	Vertebrae
	Spine
Chest	Lungs
	Diaphragm
	Heart: Heart rate
	Four-chamber view
Abdomen	Abdominal wall
	Stomach
	Kidneys
	Bladder
	Two umbilical arteries
Limb and extremities	Long bones
	Fingers
	Toes
External genitalia	

Table 2: Checklist of the second trimester ultrasound diagnosis of fetal anomalies

Skull and brain	Size, shape and integrity and bone density of skull		
	Ventricles		
	Cavum septum pellucidum		
	Midline falx		
	Thalami		
	Cerebellum		
	Cisterna magna of brain structures.		
Face	Median facial profile		
	Orbits		
	Nose and Nostrils		
	Lip		
Neck and spine			
Chest	Lungs		
	Diaphragm		
	Heart:	Heart rate	
		Size	
		Four-chamber view	
		Interventricular septum	
		Aortic and pulmonary outflow tracts	
		Three-vessel view	
		Aortic arch	
Abdomen	Abdominal wall		
	Stomach	Position	
		Size and shape	
	Kidneys	Size, appearance and renal pelvis	
	Bladder		
	Two umbilical arteries		
Limbs and extremities	Long bones		
	Arms, hands and fingers		
	Legs, feet and toes		
External genitalia			
Estimated fetal weight (EFW)			
Amniotic fluid assessment			

Table 3: Demographics of the subjects

Maternal	
Height	158.8 ± 8.8 cm
Body weight	53.2 ± 8.7 kg
Gravida (median, range)	0 (0-7)
Parity (median, range)	0 (0-5)
Spontaneous abortion (median, range)	0 (0-5)
Induced abortion (median, range)	0 (0-6)
in vitro fertilization and embryo transfer (n)	8.7 % (188)
Neonatal	
Birth weight	2958 ± 308 g
Delivery at gestational weeks	39.3 ± 1.1
Umbilical arterial pH	7.31 ± 0.07

The data indicate the mean ± standard deviation, median (range) or frequency (n).

Table 4: Outcomes stratified by ultrasound abnormal findings in the first trimester

Findings in 1st trimester	Outcomes (n)
Diagnostic findings	
Anencephaly	Artificial abortion (2)
Endocardial cushion defect	
	Artificial abortion due to abnormal chromosome (2)
Findings suspected anomaly	
Fetal edema	Spontaneous abortion (2)
	Artificial abortion due to abnormal chromosome (10)
	Disappeared (1)
	Anomaly was found in 2nd trimester
	Hydronephrosis (1)
	Ventriclar septal defect (1)
	Heterotaxia and single ventricle (1)
Ventriculomegaly	Spontaneous abortion (1)
Choroid plexus cyst	Disappeared (3)
Cardiac focus	Disappeared (1)
Ascites	Disappeared (1)
Absent stomach	Disappeared (1)
Umbilical cord cyst	Disappeared (1)

Table 5: Prenatal ultrasound diagnosis of fetal anomalies and outcomes

With prenatal ultrasound diagnosis	
Cleft lip	3
Heterotaxia and single ventricle	1
Ventricular septal defect	2
Intestinal atresia	1
Hydronephrosis (grade IV)	3
Polycystic kidney	2
Spina bifida	1
Without prenatal ultrasound diagnosis	
Accessory ear	2
Funnel chest	1
Atrial septal defect	1
Ventricular septal defect	8
Pyloric atresia	1
Double ureter	1
Hypospadias	1
Meatal atresia	1
Anal atresia	1
Polysyndactyly	1